

Laparoscopic Extraperitoneal Repair of Incarcerated Bladder Inguinal Hernia

Abstract

Introduction. Cases of inguinal bladder hernia are rare, with bladder involvement seen in 1–4% of inguinal hernias. Surgical repair is currently the standard treatment, and careful surgical planning is necessary to avoid complications including bladder injury.

Case Presentation. A 62-year-old man presented to our Emergency Department with 2-day history of progressively worsening left lower quadrant pain, groin bulge, and dysuria. Physical exam revealed an irreducible right inguinal hernia associated with urinary urgency on attempted reduction. Plain CT was ordered and demonstrated inguinal hernia with bladder protrusion into the right scrotum. The patient underwent Laparoscopic extraperitoneal reduction and hernia repair and made a quick postoperative recovery without complications.

Discussion . Inguinal bladder hernia most often presents in older, obese males and clinicians should have a high index of suspicion when assessing patients with inguinal hernia. Preoperative diagnosis based on history, physical, and radiologic imaging allow for careful surgical planning and prevention of severe complications including bladder injury and leakage.

Conclusion. We present a case report of incarcerated inguinal bladder hernia in a middle-aged man that presented as right lower quadrant pain, groin pain, and dysuria. The hernia was Laparoscopic extraperitoneal repair reduced and the defect repaired without complications.

1. Introduction

Although incidence of bladder and inguinal hernia can be seen in 1-4%, incarcerated bladder inguinal hernia is very rare (1). The contents of the hernia sac can range from a simple diverticulum to the entire bladder, ureter, and prostate with intestinal segments (1,2). While small bladder hernias generally do not cause any complaints, patients with large or incarcerated bladder hernia may present with symptoms such as lower urinary tract symptoms, intermittent scrotal swelling and biphasic voiding. Symptomatic patients usually require surgical correction. We aimed to present the laparoscopic extraperitoneal repair of an incarcerated bladder hernia.

2. Case report

A 62-year-old male patient presented to our outpatient clinic with complaints of intermittent right groin swelling and lower urinary tract for 15 days. In the history, it was learned that the complaints first started with swelling in the right groin and then the swelling did not disappear and caused pain. It was learned that the patient had diabetes mellitus and hypertension which had been under oral control for 10 years. Body mass index was 26 kg/m². Physical examination revealed an unreducible swelling of approximately 7-8 cm in the right groin that did not descend to the scrotum. Ultrasonography revealed suspected bladder hernia and cystography was planned. On cystography, approximately one quarter of the bladder was incarcerated from the right inguinal hernia site. Magnetic resonance imaging (MRI) confirmed that there was no evidence of malignancy in the hernia sac and that there was continuous incarcerated hernia in the bladder (Figure 1). The patient underwent laparoscopic extraperitoneal reduction of the incarcerated bladder directly from the hernia site and hernia repair with mesh. There was no postoperative problem and the patient was sent to the second postoperative home. On the 15th day, the cystography showed normal bladder.

The preperitoneal area was enlarged by inflating the balloon in the Bogros area by passing the skin, subcutaneous and rectus anterior sheath through a 1.5 cm incision made from the midumbilical midline and then extending the 10 mm balloon dilator through the rectus sheath

to the pubis. After the CO₂ was delivered through the hub port, 2 more 5 mm trocar was entered under the umbilical middle line under the sight of the camera so as not to interfere with each other. The dissection area was enlarged until simplex pubis and inferior epigastric vessels were seen on the inner side, and the outer margin of the psoas muscle appeared on the anterior superior sink of the spina iliac. An incarcerated bladder was seen in the direct hernia area (Figure 2) and it was reduced by blunt dissection to the anatomic position. The bladder was inflated by giving water through the foley catheter and bladder integrity was checked. After the hernia sac was rotated at the level of the inner inguinal ring, the separation of the spermatic cord and vessels and the reduction of the whole hernia sac were performed. (figure 3) The patch of appropriate size was laid to cover the potential hernia areas, and it was fixed to the pubic bone and Cooper ligament on the inner side and transverse aponeurosis at the iliac bone level on the outer side. (Figure 4) The process was terminated by providing CO₂ desufflation under the camera view.

3. Discussion

Bladder hernia develops in 4% of inguinal hernias, approximately 31 cases have been reported in the literature and incarcerated bladder hernia has not been found (1-5). Bladder hernia is usually slippery in the inguinal canal with omentum. Bladder hernias are thought to be due to chronic urinary obstruction, obesity, decreased bladder tone and weakness of the pelvic muscles (1). Ersoy et al. reported a case of giant inguinoscrotal bladder hernia developing as a late complication of inguinal herniorrhaphy (2). Bladder hernias are usually seen in the elderly and are more common on the right side (1). In our case, it was seen in the elderly and right groin. Bladder hernias are classified as intraperitoneal, extraperitoneal and paraperitoneal according to their relationship with the peritoneum. Extraperitoneal hernia is the most common type as seen in our patient. Intraperitoneal hernias are extremely rare. The clinical presentation of scrotal bladder hernias is generally related to the size and content of the hernia. While small ones do not usually cause any complaints, large bladder hernias may present with hematuria, pain, biphasic voiding, renal failure, incarceration or perforation (14). In a 2004 study, 11.2% of incarcerated mesena hernias were shown to be associated with urologic malignancies (6-7). Das et al. reported a case of transitional cell carcinoma developing in herniated bladder diverticulum (4). In our case, we ruled out malignancy in the first stages with MRI. Truss et al. reported a case of scrotal bladder hernia involving the entire bladder, prostate, urethra, and both ureters leading to uremia (3). Ultrasound is the first imaging modality to be used in the differential diagnosis of scrotal swelling. The hypoechoic

appearance adjacent to the testis extending into the inguinal canal is the main finding in ultrasound. Ultrasound also allows the evaluation of the upper urinary system. Retrograde urethrocytography is the indispensable imaging method in the diagnosis of bladder hernia. Computed tomography and MRI provide additional information for hernia content and assist in surgical planning. Preoperative recognition of hernia sac contents is important to prevent serious surgical complications. Gomella et al. reported that unrecognized bladder injuries during hernia repair may lead to serious complications such as hematuria, sepsis and fistula formation in 38% of cases (1). In the treatment of scrotal bladder hernias, inguinal placement of hernia in the anatomical position of the bladder and repair of patchy / non-patchy hernia is the preferred method. Moufid et al. reported that the hernia can be repaired successfully in cases where the use of patches is avoided due to bleeding or the possibility of urine contact or leakage to the surgical area (6). Partial cystectomy is recommended in the presence of necrotic bladder tissue or bladder diverticulum, when hernia neck is smaller than 0.5 cm or incidental bladder tumor is detected within the hernia (1). Laparoscopic repair of incarcerated inguinal hernia has been increasingly accepted in recent years. In laparoscopic repair of incarcerated direct or indirect hernias, it is recommended that in some sources, the incision of the defect area or blunt dissection can be reduced in a controlled manner.

4. Conclusion

Patients presenting with incidental inguinal hernia should be suspected of having a bladder herniation, especially if urinary system complaints are present, and in order to minimize the intraoperative complication, it is necessary to clarify the diagnosis and perform an operation plan with preoperative evaluation. The laparoscopic extraperitoneal bladder can be removed from the hernia sac without any complications and placed in its anatomical place and repaired by mesh.

References

1. Gomella LG, Spiers SM, Burton JM, Ram MD, Flanigan RC. The surgical implications of herniation of the urinary bladder. Arch Surg 1985;120:9647.

2. Ersoy E, Karagüzel E, Akgül T, Ayyıldız A, Germiynoğlu C. Dev inguinoskrotal mesane hernisi: inguinal herniografinin geç Skrotal mesane hernisinin düzeltilmesi, hastanın alt bir komplikasyonu. Türk Üroloji Dergisi 2009;35(3):2667.
3. Truss F, Zimmermann A. Uremia caused by giant scrotal hernia and bladder herniation (author's transl). Urologe A 1981; 20(3): 15961.
4. Das CJ, Debnath J, Thulkar SP, Kumar L, Vashist S. Transitional cell carcinoma in a herniated vesical diverticulum. Br J Radiol. 2007;80(957):e2279.
5. Stewart CA, Hung GL, Olsen B, Bennett C. Urinary bladder herniation into the scrotum. Incidental demonstration on bone scintigraphy. Clin Nucl Med. 1996;21(6): 498.
6. Moufid K, Touiti D, Mohamed L. Inguinal bladder hernia: four case analysis. Rev Urol. 2013;15:326.2170
7. Kraft K.H., Sweeney S., Fink A.S., Ritenour C.W.M., Issa M.M. Inguinoscrotal bladder hernias: report of a series and review of the literature. Can. Urol. Assoc. J. 2008;2(6):619–623.

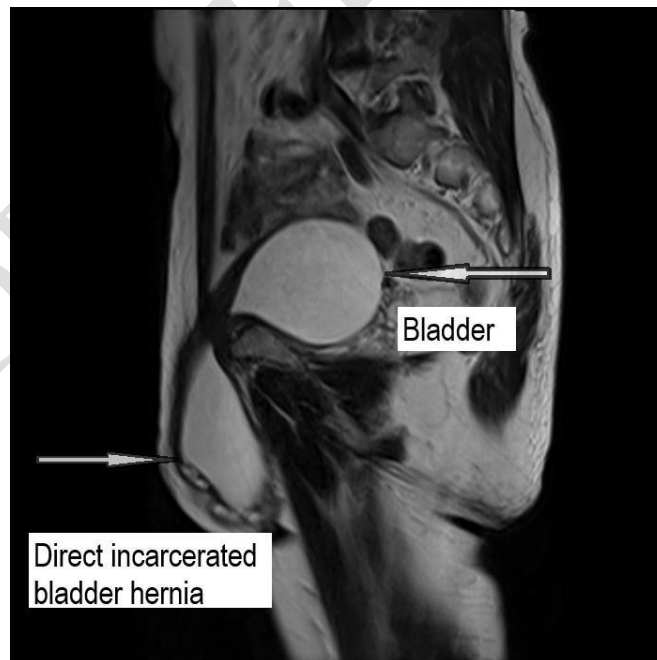


Figure 1. Magnetic Resonance Image of Incarcerated Bladder Hernia

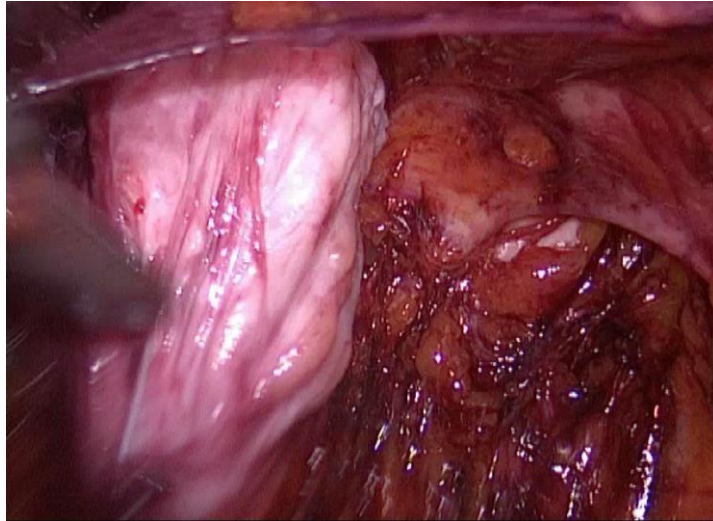


Figure 2. Intraoperative image of incarcerated bladder hernia

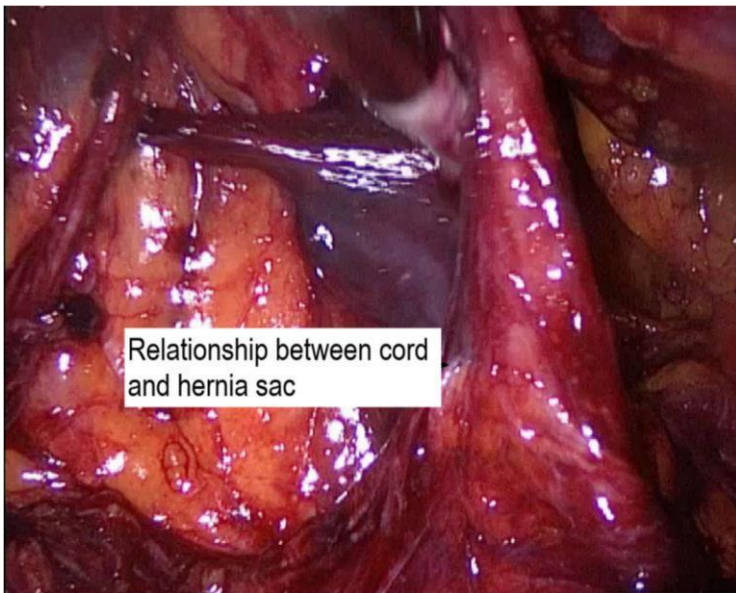


Figure 3. Separation of hernia pouch from Inguinal cord

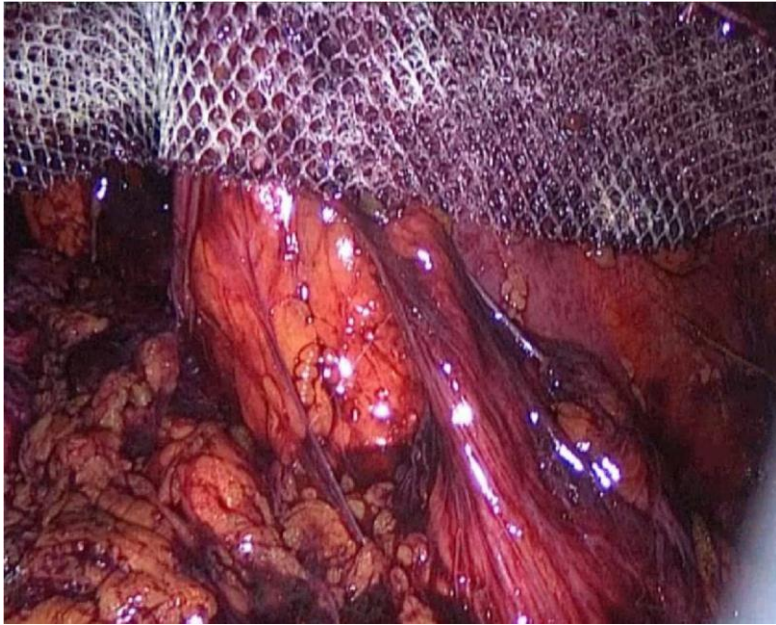


Figure 4. Laparoscopic repair with extraperitoneal mesh

UNDER PEER REVIEW