

Maxillary prosthodontic rehabilitation with Fixed-Removable Partial Denture using extra coronal attachment: A clinical case report

ABSTRACT:

The rehabilitation of partially edentulous patients is a real challenge for prosthodontists. Attachment retained cast partial dentures can be an excellent option when economic or anatomic conditions do not permit the use of dental implants. They give functionally and esthetically good results. This article describes rehabilitation of a partially edentulous patient with attachment retained hybrid prosthesis.

Keywords: Fixed denture, removable partial denture, extra coronal attachment

Introduction:

Rehabilitation of partial edentulism can be done by several methods out of which one treatment modality is implant retained prosthesis: This option need a sufficient residual bone, a good general health status and a good economic situation of patients. Fixed dentures may not be recommended when remaining teeth are unable to withstand oral charges or when the edentulism is terminal or extended. [1]

Combined prosthesis constitutes a feasible option if implant retained or fixed prosthesis are not possible and a good alternative to a conventional clasp retained removable partial denture. This type of prosthesis not only provide an esthetic result, also it gives functional advantage of fixed denture that leads to decreased compression of edentulous ridge and enhanced phonetics and mastication. [2]

The present clinical case report describes a maxillary prosthodontic rehabilitation with a combined prosthesis: a fixed dental prosthesis designed to interfere with a removable cast framework partial denture (RPD) retained by an extra coronal attachment type Rhein⁸³.

Clinical case presentation:

A 52 years old female, with good general health status, was addressed to the Prosthodontics Department at the *FACULTY OF DENTAL MEDICINE, UNIVERSITY OF MONASTIR, TUNISIA*. She was unsatisfied of her smile and suffered from compromised masticatory function.

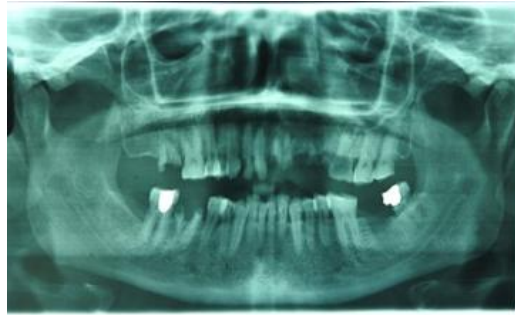


Figure 1: Orthopantomogram before extraction of compromised teeth

Clinical and radiographic examinations (**Fig.1**) revealed a lack of posterior support, a little loss of occlusal vertical dimension, an alteration in the occlusal plane and a reduced vertical space. The diagnosis of Kennedy-Applegate class I modified 1 edentation in the maxillary arch was made. Decays are found in the 11, 12 and 44 (**Fig. 2**) After compromised teeth extraction and periodontal clinical status, remaining teeth: 16, 15, 14, 13, 12, 11, and 27 presented good periodontal support.

Considering the extensive caries lesions the maxillary right central and lateral incisor, were endodontically treated. Lateral incisor was reconstituted by an inlay core to get best retention value.

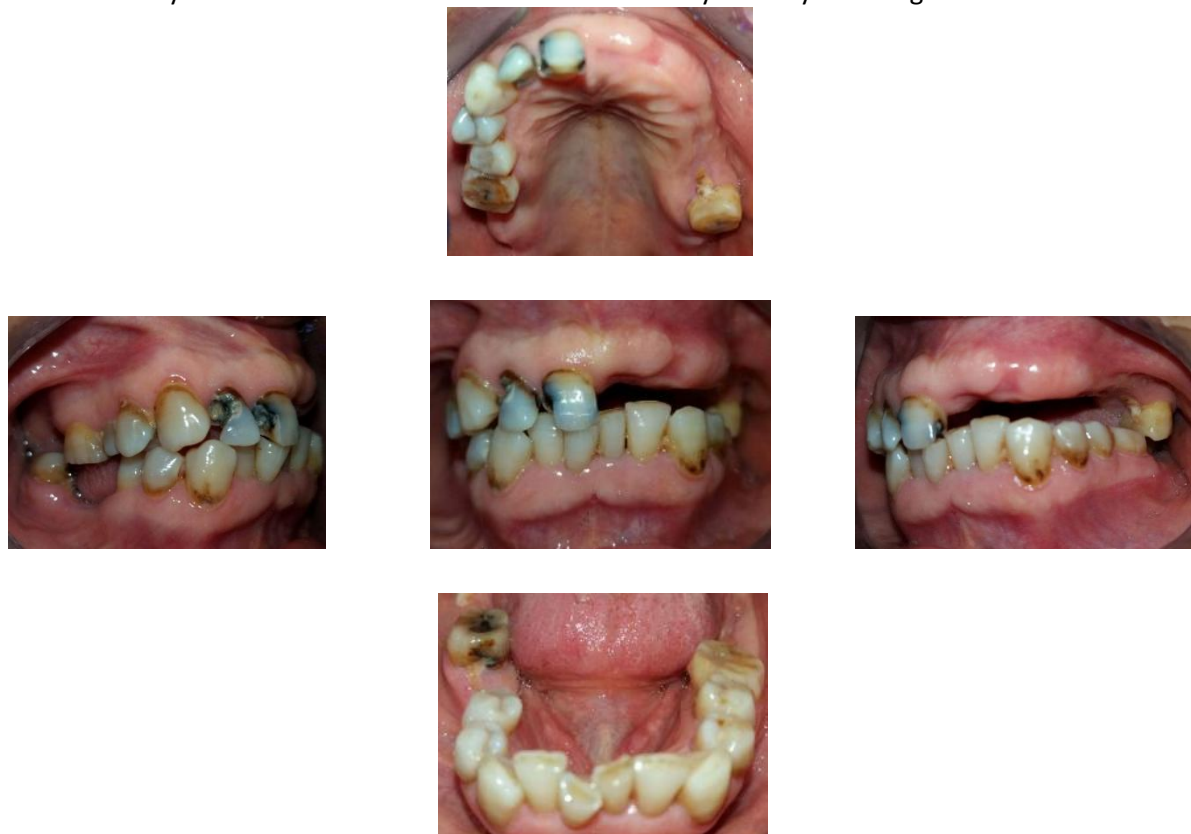

Figure 2 : pretreatment intraoral view

Diagnostic casts were articulated at the correct occlusal vertical dimension, and the treatment was carefully planned taking into account patient's esthetic demand and economical condition. Inter-arch space was found to be adequate for the use of precision attachments.

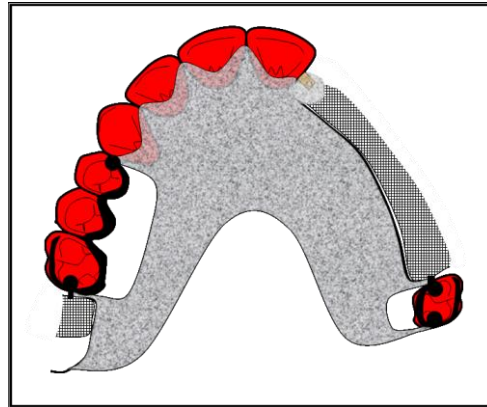


Figure 3: Design of the prosthesis frame

Treatment plan included rehabilitation of maxillary arch with combined fixed/removable prosthesis (using RHEIN⁸³ precision attachment) (Fig.3) and fixed prosthesis in the mandibular arch. It was established and presented to the patient to obtain her consent.

Preparation of all maxillary remaining teeth is done (Fig. 4, 5) in order to be restored with fixed metal-ceramic bridge as well as 45 and 47.

Provisional acrylic resin crowns were fabricated and a provisional removable partial denture was created to replace missing teeth. Provisional restorations are an integral part of prosthodontic treatment pertaining to their importance regarding margin fidelity, function, occlusion, and esthetics. [3]

Once the prosthodontic project has been visualized by provisional restorations, we started clinical steps. Gingival retraction was achieved by double wire methods and maxillary Impression was made with wash technique using silicone of low and heavy viscosity. (Fig. 6)

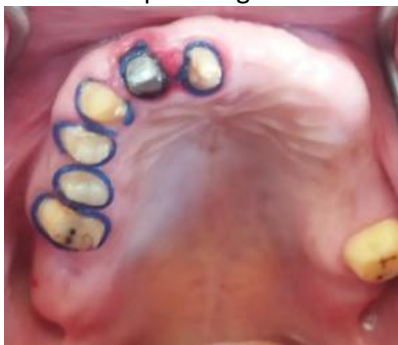

Figure 4: preparation of all remaining maxillary teeth

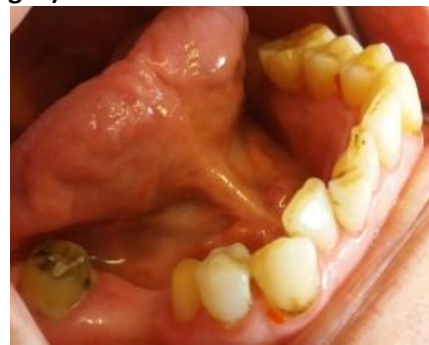

Figure 5: preparation of 45, and 47

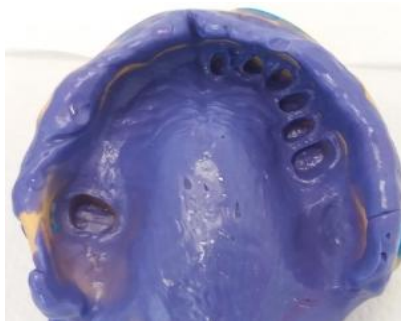


Figure 6: Maxillary impression

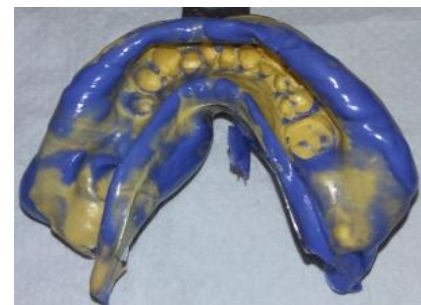

Figure 7: Mandibular impression

The final model was performed in gypsum type IV mounted in semi adjustable articulator using a face bow. References are the centric relation and a correct occlusal vertical dimension.

In laboratory crowns have been waxed (**Fig.8**) and the Patrice of the attachment was added to the distal surfaces of the abutment using a dental surveyor, lingual to the centre of proximal contour (**Fig.9**). This ensures that the matrice parts do not interfere with esthetic and that fixed elements are made according to an insertion path; in this case it s the vertical path.

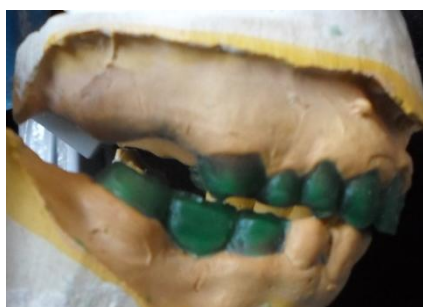

Figure 8: Waxed Crowns

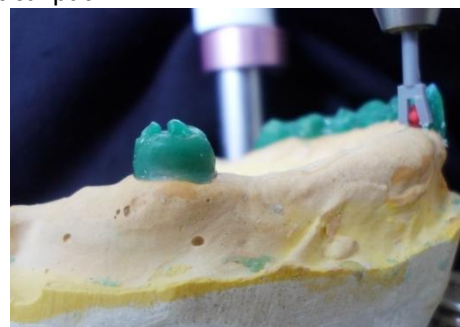


Figure 9: Fixing the patrice of the attachment

In laboratory the metal framework is made (**Fig.10**) and the extra-coronal attachment was attached. The lingual surfaces of the maxillary teeth were flattened to guide the insertion /removal path of the removable partial denture. The metal copings were examined and the marginal limits were verified. An adequate interocclusal distance allowed ceramic application. The unglazed ceramic was clinically tried and returned to the definitive cast. The dental surveyor was again used to check the previously established insertion/removal path of the RPD. Porcelain buildup of fixed denture was completed. (**Fig. 11**)

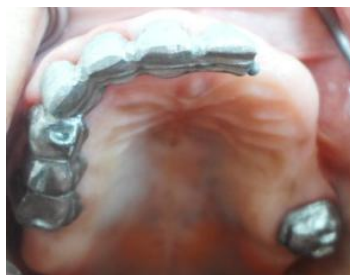

Figure 10: Metal framework try-in

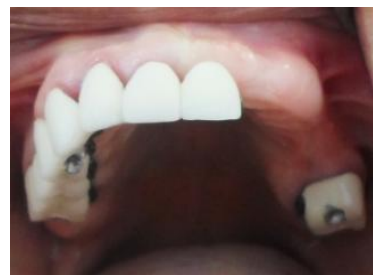

Figure 11: clinical try-in of fixed denture

The fixed component including veneered metal-ceramic crowns and the patrices were tried in the patient mouth (**Fig. 12**) and a pick-up impression with acrylic custom tray and polyether was made. (**Fig. 13**) Polyether seems to be ideal for a pick up impression it s known for its precision and rigidity.

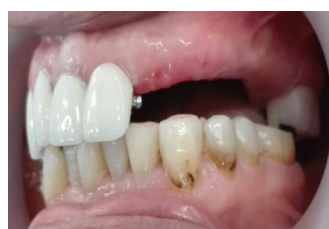

Figure 12: Trying the finished bridge impression

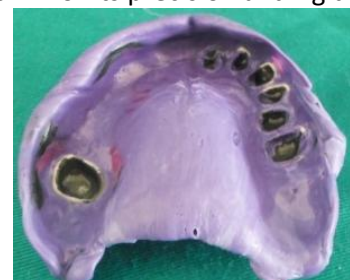


Figure 13: Pick-up

Female replica of the attachment was attached to the cast male component (**Fig. 14**). The Fixed partial denture /cast assembly was duplicated with reversible hydrocolloid, and a refractory cast was produced. The RPD framework was cast in a cobalt-chromium alloy and clinically tried to check seating. The artificial teeth were selected and positioned using the interim prostheses as form and color reference.

Wax-up of the cast framework was completed on the master cast, (**Fig 15**) and the entire cast partial framework was cast in Co-Cr alloy. Care was taken during the finishing and sandblasting procedures of the casted fixed denture to avoid abrasive wear of the attachment (**Fig. 16**)

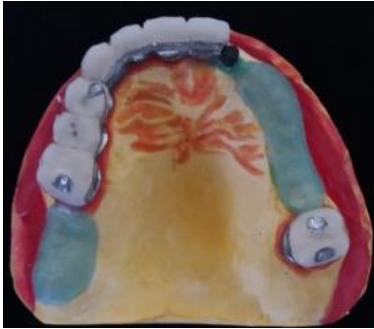

Figure 14: Female replica fixed denture

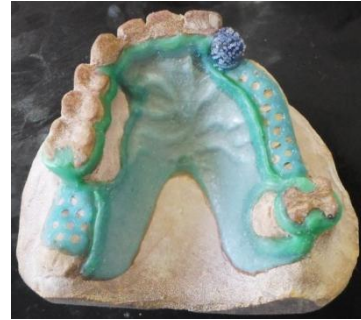

Figure 15: Wax pattern fabrication of cast partial

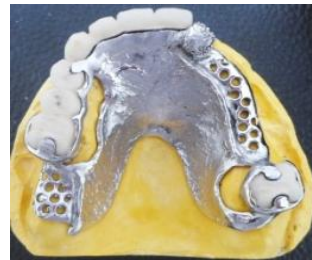

Figure 16: Framework of maxillary cast partial

Maxillomandibular relation was recorded and mounted on semi-adjustable articulator after trying the metallic frame of partial denture in mouth. Teeth arrangement was done and wax try in done.

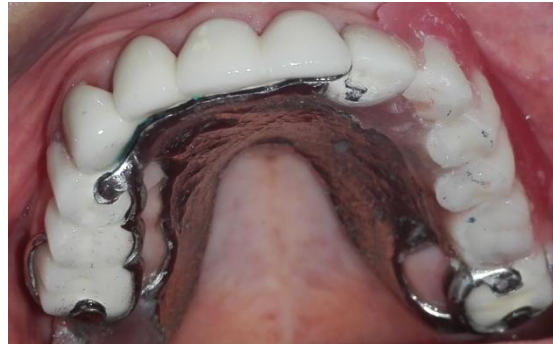

Figure 17: Clinical try-in of RPD framework.

Occlusion and esthetics was verified in patient's mouth. Cast partial denture for maxillary arch was fabricated in heat cure denture base resin.

Female components of attachments were attached to cast partial denture by relining method after verifying occlusal contacts. It's a critical step because an incorrect positioning can result in a wrong fitting of the removable partial denture.

So, crowns and the framework had to be inserted and cemented simultaneously.

Retention was found to be satisfactory after insertion of cast partial in patient's mouth. The patient was instructed regarding oral hygiene, use of interproximal brushes, how to remove and insert the denture and the time to recall for matrices check, in order to have a good functionality.

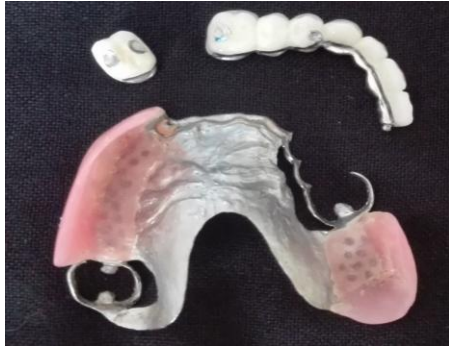

Figure 18: Different parts of the combined prosthesis smile

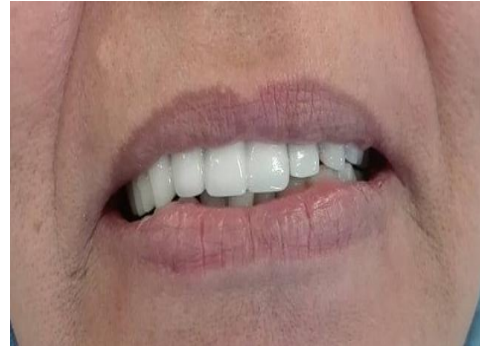

Figure 19: Post-treatment frontal smile

The end result has provided patient satisfaction regarding the combination of fixed dentures and removable skeletal dentures using an extra coronal attachment. Occlusion stabilization was achieved, improved chewing and good aesthetics.

Discussion:

The association between fixed and removable partial dentures by means of attachments is an important alternative for oral rehabilitation, particularly when the use of dental implants and fixed denture is limited or not indicated. [1]

Attachment is a connector consisting of two or more parts. They are classified as semi precision and precision devices. In our case, we used a semi precision attachment type Rhein⁸³ which is cast from calculable patterns, while in precision attachments, the matrix portions are prefabricated on a metal alloy. [4]

Among the advantages of an attachment-retained removable partial denture are the improvement in esthetics, as clasps are not used in the anterior region, and biomechanics, considering that lower torque is applied to the abutment teeth in a cervical direction during functional movements. Moreover, attachment helps to distribute forces equally between soft and hard tissues. [5, 7]

Attachments may also allow better cross arch force transmission and stabilization than clasps but this is determined by the type of attachment used, the number of guiding surfaces and the design of the framework. [6, 8]

The extra coronal attachment used in our case has a vertical freedom of movement with elastic retention; this elasticity controls the flexure and constructs a resilient and shock absorbing prostheses.

Most of the studies have shown that attachment retained cast partial dentures gives better comfort, function, esthetics, less adjustments, protect abutment teeth and easy to clean. [8]

The stress control on abutment is essential for the success of the prosthodontic rehabilitation which is achieved through accurate impression technique, broad coverage, stable denture base, a good shimming and proper selection of attachment. [8]

Finally, long term success requires knowledge of important laboratory techniques, clinical skills; it depends also on biological factors, especially the periodontal ones. [9]

References:

- 1- Chronopoulos V, Sarafianou A, Kourtis S: The use of dental implants in combination with removable partial dentures: a case report. *J Esthet Restor Dent* 2008; 20:355–364.
- 2- José Mauricio dos Santos Nunes Reis, Luciano Elias da Cruz Perez, Bruna Fernandes Moreira Alfnas and al: Maxillary Rehabilitation Using Fixed and Removable Partial Dentures with Attachments: A Clinical Report.
Journal of Prosthodontics 00 (2013) 1–6 C _ 2013 by the American College of Prosthodontists
- 3- Regish KM, Sharma D, Prithviraj DR: Techniques of fabrication of provisional restoration: An overview
International Journal of Dentistry 2011(6):134659
- 4- Cristian Schuh, Jovito Adiel Skupien , Mauro Elias Mesko and al
Resilient Attachments as an Alternative to Conventional Cast Clasp Removable Partial Denture: 3-Year Follow-up. *J Indian Prosthodont Soc (December 2014) 14(Suppl. 1):S273–S278*
- 5- Sakshi Gupta, Sapna Rani, Arpit Sikri, Aditya Kapoor
Attachment Retained Cast Partial Denture: Conventional and Contemporary Treatment Perspectives
International Journal of Oral Care and Research, October-December 2016; 4(4):312-316
- 6- Sharad Vaidya, Charu Kapoor, Yujika Bakshi, Sonam Bhalla
Achieving an esthetic smile with fixed and removal prosthesis using extracoronar castable precision attachments
The Journal of Indian Prosthodontic Society | Jul-Sep 2015 | Vol 15 | Issue 3
- 7- Gopinadh Anne, Krishna Kishore Kadiyala H, Ravi Rakesh Dev J, Mohan Krishna Badisa
Full mouth rehabilitation using fixed partial denture & cast partial denture with attachments and conventional lower denture - A case report
International Dental Journal of Students Research; 5(1):25-28
- 8- GulshanKumarTomar, Mirna Garhnayak,SitansuSekhar Das , Shelly Roy
Cast Partial Denture Retained Using Precision Attachment – A Case Report
IOSR Journal of Dental and Medical Sciences; Volume 15, Issue7 Ver. V (July 2016), PP 94-99
- 9- Agripina Zaharia, Aureliana Caraiane, Corina Ștefănescu, Rodica Murineanu and al
Fixed Dentures Combined with Removable Dentures Retained with Extracoronar Attachments
Ovidius Dentistry Journal, vol. 1, no. 1, 2014