

1 **URETER KINKED AROUND THE SUPERIOR MESENTERIC VEIN CAUSING**
2 **FEATURES OF PELVIURETERIC JUNCTION OBSTRUCTION: A CASE REPORT**

3

4

5 **ABSTRACT**

6 Pelviureteric junction obstruction (PUJO) is the condition where flow of urine from
7 the renal pelvis to the ureter is hindered due to various intrinsic or extrinsic causes.
8 lower pole renal vessels are mostly associated with this condition. Unlike our case,
9 there have been reports of ureter being kinked around the Veins of Retzius but there
10 has been no case report of ureter being kinked around the superior mesenteric vein
11 directly causing causing features of PUJO.

12 **KEYWORDS**

13 PUJO; Pyeloplasty; Superior mesenteric vein ; Endopyelotomy; Veins of Retzius.

14 **INTRODUCTION**

15 Pelviureteric junction obstruction (PUJO) is a condition in which the flow of urine
16 from the renal pelvis to ureter is obstructed . This condition is more often seen in
17 children but not rare in adults. The overall incidence of PUJO is between 1 in 1000
18 to 1 in 2000 live births. Antenatal ultrasonogram (USG) of the abdomen can detect
19 this condition in growing foetus.^[1] About 80% of the dilated pelvicalyceal systems in
20 the growing foetuses are due to PUJO.^[2] It is more common in boys and is frequently
21 seen on the left side. The causes of obstruction are classified as intrinsic or extrinsic.
22 They could be primary or secondary. The crossing renal vessels are an important
23 extrinsic cause of PUJO. A crossing aberrant lower pole renal artery is the most
24 common offending vessel.^[2] There has been case reports of ureter being trapped
25 between the vein of Retzius^[3] but to the best of our knowledge there has been no
26 case where the ureter was kinked around the superior mesenteric vein leading to
27 features of PUJO.

28

29

30 **CASE REPORT**

31 We present the case of a 23 years old female who has been coming to outpatient
32 department time and again with right flank pain along with occasional nausea for last
33 one year. No lump was palpable on abdominal examination. Her routine
34 haematological and biochemical investigations were within normal limits. Urine
35 examination showed pus cells and a positive leucocyte esterase. USG showed
36 hydronephrotic right kidney with dilated pelvis . Patient underwent CT urography
37 which revealed hydronephrotic right kidney with dilated PUJ and upper ureter with
38 bilateral normally excreting kidneys(Fig. 1). The patient was taken up for open
39 Anderson Hynes dismembered Pyeloplasty. The right PUJ and upper part of ureter
40 was grossly dilated until a point where the ureter was kinked around the superior
41 mesenteric vein (SMV) (Fig.2). The ureter was divided just distal to the junction of
42 the dilated and normal ureter. The redundant pelvis alongwith the grossly dilated
43 ureter was excised and the pelviureteric anastomosis was done over a 6F double J
44 stent to bring it anterior to SMV (Fig.3). The patient was sent home on the fourth post
45 operative day after an uneventful hospital stay. The double J stent was removed
46 after 03 weeks. She is still in follow up and symptom free. The facility of nuclear scan
47 is not available in the institution and closest center to offer this facility is 250
48 kilometres away hence it could not be done.

49 .

50 **DISCUSSION**

51 Pelviureteric junction (PUJ) obstruction refers to a condition where the drainage of
52 urine from the renal pelvis to the ureter is obstructed. This can be due to the intrinsic
53 causes or any extrinsic cause. Most common cause of intrinsic PUJO is
54 disorientation or complete absence of muscle fibres or excessive collagen deposition
55 in the muscle fibres at PUJ along with decrease of nerve terminals and nerves at
56 stenotic segments. These all factors lead to ineffective peristalsis causing caliectasis
57 and hydronephrosis and failure of passage of urine from renal pelvis to the ureter.
58 Impacted stones, strictures secondary to instrumentation, ureteral polyps and
59 persistent fetal involutions are other intrinsic causes of PUJO. A crossing lower pole
60 renal vessel is the most significant external cause of PUJO apart from external
61 compression of the PUJ by kinks, tumors, high insertion of ureter or retroperitoneal

62 fibrosis. ^[1,2,4] Lower pole crossing vessels may arise from aorta , vena cava, renal
63 vessels or iliac vessels. Most of the times crossing vessels are arteries and they are
64 anterior branches.^[5] They may be the only possible cause of PUJO. ^[1] Maheshwari et
65 al has reported a case of 26 years old female where the PUJO was caused by Veins
66 of Retzius.^[3] They are the anastomotic channels between superior or inferior
67 mesenteric vein and the inferior vena cava. They can provide a route for the spread
68 of colonic malignancies and can easily be injured during the right hemicolectomy The
69 kinking of ureter due to wrapping around the superior mesenteric vein leading to
70 features of pelvireteric junction obstruction has never been reported in literature. It is
71 very difficult to say if the crossing vessels are responsible for PUJO or they are mere
72 associations with this condition as it occurs in about 25-50% of the patients.
73 Crossing vessels can be a source of haemorrhage during minimally invasive
74 techniques for PUJO like endopyelotomy . They further can be a cause of recurrent
75 obstruction after minimal access surgery thus responsible for long term failure of
76 these techniques. The patients usually present with an intraabdominal mass, flank
77 pain, nausea, and repeated features of urinary tract obstruction (UTI). USG of the
78 abdomen is the initial investigation of choice which will pick up the dilated
79 pelvicalyceal systems and the pelvis. Antenatal USG can even pick up
80 hydronephrosis in the foetuses from 16- 20 weeks onwards. An antero posterior
81 diameter of renal pelvis more than 10-11 mm is diagnostic of PUJO. A Doppler
82 resistive index of > 0.7 is an indicator of obstruction.^[6] Intravenous pyelography (IVP)
83 used to be the diagnostic modality in past but now a days it has been replaced with
84 nuclear scans. They can diagnose obstruction as well as predict the differential renal
85 function (DRF) thus helping in planning the surgical intervention. Dimercaptosuccinic
86 acid (DMSA) is a cortical agent whereas diethylenetriaminepentaaceticacid (DTPA)
87 and mercaptoacetyltriglycine (MAG 3) are the tubular agents . MAG-3 is considered
88 the best scan for diagnosing PUJO. A clearance of less than half of total radio
89 isotope at 20 minutes is considered diagnostic of PUJO. A DRF of less than 10% is
90 an indication for nephrectomy.^[1] Computerised tomographic angiography (CTA), CT
91 urography, Magnetic resonance angiography (MRA) or MR urography gives the
92 detailed renal morphological picture along with the renal vascular relationship to the
93 PUJ. Every patient is not a case for treatment. Hydronephrosis will disappear after
94 birth in about 75% of the neonates.

95 Worsening symptoms or deterioration of the renal functions in a patient of PUJO are
96 indications for surgical treatment. The goals of surgery are to ensure free drainage
97 of urine, enhance renal functions, prevent complications and to render the patient
98 symptom free.^[1,2] Anderson Hynes dismembered pyeloplasty is considered as the
99 gold standard but the more conservative and minimally invasive techniques are also
100 being employed with equivalent success. Open dismembered Pyeloplasty has a
101 success rate of about 95% .^[4] It can also be done by transperitoneal , retroperitoneal
102 or robotic assisted through laparoscopic approach. The aim of pyeloplasty is to
103 remove the scarred portion of PUJ, excise the redundant pelvis and fashion an
104 anterior uretropic anastomosis to ensure the free and dependent exit of the urine
105 from kidney to the ureter. An antegrade or a retrograde endopyelotomy is the
106 minimally invasive endoscopic approach with about 85% success rate but the renal
107 vascular information is important as the lower pole renal vessels can lead to
108 hemorrhage in case of injury at endopyelotomy . Ureter can be attached to a lower
109 pole renal calyx in case of failed open pyeloplasty and extensive renal scarring.^[1,4]
110 We contacted the patient telephonically and she is doing well . She was called upon
111 for review investigations but she couldn't turn up for the same due to being from a far
112 flung area around 200 kilometres away however, The patients should be followed
113 with USG and MAG3 scans to ensure resolution of symptoms, improved renal
114 functions and early detection of recurrence or treatment failure.

115

116

117 **CONCLUSION**

118 Lower pole crossing vessels are most important extrinsic cause of PUJO. Ureter
119 getting entangled around the superior mesenteric vein is a very rare cause of PUJO.
120 Anderson Hynes dismembered pyeloplasty is the treatment of choice .

121

122

123 **CONFLICT OF INTEREST**

124 Authors declare no conflict of interests.

125

126

127

128

129 **CONSENT**

130 Written informed consent was obtained from the patient for publication of this Case
131 report and any accompanying images. A copy of the written consent is available for
132 review by the Editor-in-Chief of this journal.

133

134

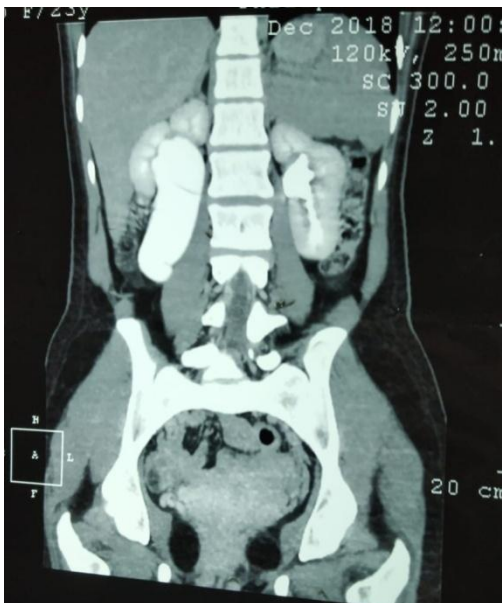135

136

137

138 **FIGURES**

139



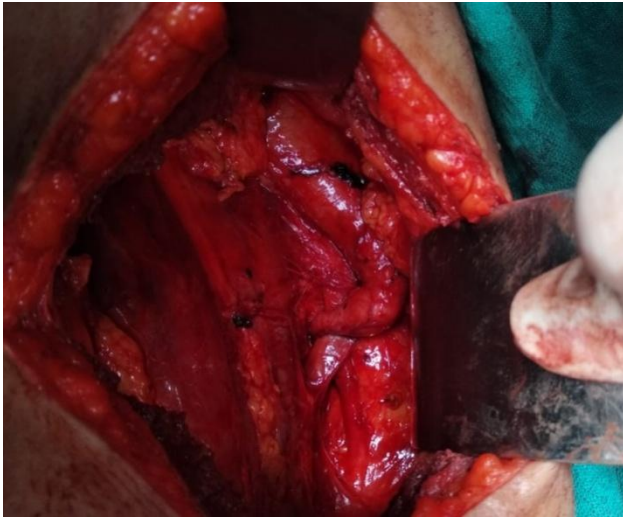140

141

142 Fig.1: CT urography showing the dilated right renal pelvis and upper ureter.

143

144

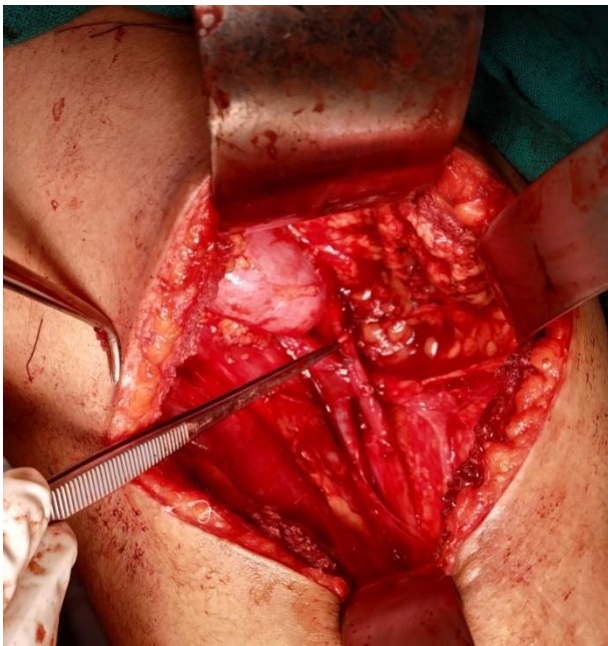


145

146

147 Fig. 2: Showing dilated upper part of the ureter and PUJ kinked around superior
148 mesenteric vein.

149



150

151

152 Fig. 3: Showing anteriorly placed uretero pelvic anastomosis.

153

154

155

156

157

158

159 **REFERENCES**

- 160 1. Vaos G. Pelvi-ureteric junction obstruction. In: George Sakellaris (ed),
161 Essentials in Pediatric Urology. Research Signpost, Kerala . 2012: 125-138
162 ISBN: 978-81-308-0511-5
163
- 164 2. Grasso M, Caruso RP, Phillips CK. UPJ Obstruction in the Adult Population:
165 Are Crossing Vessels Significant?: Rev Urol. 2001;3(1):42-50, 61
166
- 167 3. Maheshwari PR, Shammam O. Anomalous systemic drainage of ileocolic
168 veins (veins of Retzius) causing pelviureteric junction obstruction: Indian J
169 Radiol Imaging . 2008 ;18(3): 242-244.
170
- 171 4. Wiener JS. Upper Urinary Tract, Chapter 96. In: Oldham KT, Colombani PM,
172 Foglia RP, Skinner MA (editors). Principles and Practice of Pediatric Surgery,
173 4th Edition , Lippincott Williams & Wilkins, USA. 2005. 1541- 1563.
174
- 175 5. Lawler LP, Jarret TW, Corl FM, Fishman EK. Adult ureteropelvic junction
176 obstruction: insights with three-dimensional multi-detector row CT.
177 Radiographics 2005;25:121-34.
178
- 179 6. Borin JF. Ureteropelvic Junction Obstruction in Adults. Reviews in urology
180 .2017;19(4):261-264. doi: 10.3909/riu0781.

181

182

183

184

185

186

187