

### **Light emitting diode (LED) bulb aspiration in Northern Ghana: A case report and literature review**

#### **ABSTRACT**

Light emitting diode (LED) bulb is an unusual cause of foreign body aspiration. We present a case of a 6-year-old boy who reported with a four-day history of difficulty in breathing and cough following a LED bulb aspiration retrieved via rigid bronchoscopy. This present case suggests that LED bulb should be considered in the differential diagnosis of foreign body aspirations in our environment.

**KEY WORDS:** LED, bulb, Aspiration, bronchoscopy, Northern, Ghana.

#### **1. INTRODUCTION**

Foreign body aspiration is a well-known life-threatening emergency in children especially below the age of three years [1]. Previous studies in Ghana reported groundnuts, corn, seeds, plastics and metallic objects as the most commonly aspirated foreign bodies [1]–[4]. Globally only six cases of LED bulb aspiration have been reported. The gold standard for treatment of foreign body aspiration is rigid bronchoscopy. This article presents our first case of LED bulb aspiration in a six-year-old boy with literature review on LED bulb aspiration.

#### **2. CASE REPORT**

Our patient was a six-year-old boy who presented with four-day history of difficulty in breathing and dry cough. Prior to presentation patient was in school sleeping with a LED bulb in his mouth when a colleague suddenly startled him and he accidentally aspirated the LED bulb. He reported to our facility when the symptoms were not subsiding. There was no history of fever, dysphagia or odynophagia.

On examination, the oxygen saturation was 92% on room air with alar nasal flaring. Air entry was reduced on the right hemithorax with vesicular breath sounds. Chest X-ray showed a metallic wire-like shadow in the right main bronchus (Figure 1). An initial diagnosis of foreign body aspiration was made. Patient was given 2L/minute of intranasal oxygen and subsequently prepared for emergency rigid bronchoscopy. A LED bulb was retrieved from the right main bronchus (Figure 2). There was no perioperative complication. Patient was discharged home on the third postoperative day and eight months follow up was unremarkable.

### **3. DISCUSSION**

Foreign body aspiration is a pediatric emergency which needs to be managed with initial resuscitation and early removal of foreign body via a bronchoscope [2], [5]–[7]. Many patients succumb to death before reaching any health facility equipped to perform rigid bronchoscopy.

There have been numerous reports of foreign body aspiration in literature, including one of our previous study revealing groundnuts to be the most commonly aspirated material and children younger than 3 years are most vulnerable in more than 70% of cases [2], [8].

In the event of suspected foreign body aspiration, bronchoscopy should be done without delay due to the fact that accurate clinical diagnosis of foreign body aspiration is usually around 60% [5], [6].

This is our first case of LED bulb aspiration into the right main bronchus which we successfully retrieved by rigid bronchoscopy using advanced bronchoscope and imaging systems. LED bulb is a rare cause for tracheobronchial aspiration and only six cases have been reported in the literature so far with a total of 8 cases [5]–[10]. We reviewed the six published literature reports. The first case of LED bulb aspiration was reported in the 21<sup>st</sup> century by Mukherjee et al [5]. They reported 2 cases of LED bulb aspiration out of 74 cases of foreign body aspirations. The latest reported cases of LED bulb aspiration was in 2017 from France and India (Carsin, Baravalle-Einaudi, & Dubus, 2017; Sikdar et al., 2017).

In recent years, usage of LED bulbs has gained popularity in the toy, lightening and entertainment industry, which accounts for the recent increase in reports of its aspiration. It is possible the number of LED bulb aspiration cases are higher than reported as many authors only

report on the common foreign bodies aspirated and tend to summarize the less frequent ones and thereby omitting the incidence of LED bulb aspiration.

#### 4. CONCLUSION

In conclusion, LED bulb should be considered in the differential diagnosis of aspirated foreign bodies in Ghanaian children. We add our voice to the call of creating awareness of LED bulb aspiration in caretakers and health workers in the prevention, diagnosis and timely intervention in a center with expertise in rigid bronchoscopy.

#### CONSENT

A written consent was obtained from guardian of patient for this publication.

#### REFERENCES

- 1 M. Dzogbefia, T. Adjeso, D. M. Issahalq, R. Larsen-reindorf, and A. Konney, 'Foreign Body Aspiration in Children at the Komfo Anokye Teaching Hospital', *Journal Adv. Med. Med. Res.*, vol. 28, no. 5, pp. 1–6, 2019.
- 2 T. Adjeso, M. C. Damah, J. P. Murphy, and T. T. K. Anyomih, 'Foreign Body Aspiration in Northern Ghana: A Review of Pediatric Patients', *Int. J. Otolaryngol.*, vol. 2017, pp. 1–4, 2017.
- 3 E. D. Kitcher and K. K. Baidoo, 'AUDIT OF INHALED FOREIGN BODIES IN CHILDREN: OUR RECENT EXPERIENCE IN GHANA', *Niger. J. Otorhinolaryngol.*, vol. 7, pp. 12–15, 2010.
- 4 E. D. Kitcher, 'Foreign body inhalation: a review of patients at the Korle Bu Teaching Hospital, Accra, Ghana', *West Afr J Med*, vol. 28, no. 6, pp. 368–370, 2009.
- 5 M. Mukherjee and R. Paul, 'Foreign Body Aspiration: Demographic Trends and Foreign Bodies Posing a Risk', *Indian J. Otolaryngol. Head Neck Surg.*, vol. 63, no. 4, pp. 313–316, 2011.

- 6 T. D. Yetim, H. Bayarogulları, V. Arıca, B. Akcora, and S. G. Arıca, 'Foreign Body Aspiration in Children; Analysis of 42 Cases', *J. Pulm. Respir. Med.*, vol. 02, no. 03, pp. 61–67, 2012.
- 7 A. Sikdar, S. Mishra, S. Nivsarkar, R. Agrawal, and S. Phatak, 'Light-emitting diode bulbs in paediatric airway- A case series', *J. Evid. Based Med. Healthc.*, vol. 4, no. 91, pp. 5518–5520, 2017.
- 8 C. T. Lau, L. Lan, K. Wong, and P. K. H. Tam, 'A light bulb moment: An unusual cause of foreign body aspiration in children', *BMJ Case Rep.*, vol. 2015, pp. 10–12, 2015.
- 9 H. Roslina, S. T. Subha, S. Hisyam, and A. Asma, 'LED bulb in trachea and bronchus of an 8 months old infant', *Rawal Med. J.*, vol. 37, no. 2, pp. 220–221, 2012.
- 10 A. Carsin, M. Baravalle-Einaudi, and J. C. Dubus, 'When Christmas decoration goes hand in hand with bronchial aspiration ...', *Respir. Med. Case Reports*, vol. 22, no. June, pp. 266–267, 2017.

Table 1. Literature review of LED bulb aspiration.

Ref #	Authors	Country	Year	Cases #	Location	Intervention	Results
5	Mukherjee M et al.	India	2011	2	NS	Rigid	Satisfactory
6	Tulin Durgun Y et al.	Turkey	2012	1	NS	Rigid	Satisfactory
7	Roslina H et al.	Malaysia	2012	1	Right main bronchus	Rigid	Satisfactory
8	Lau CT et al.	Hong Kong	2015	1	Right main bronchus	Rigid	Satisfactory
9	Sikdar A et al.	India	2017	2	Right main bronchus	Rigid	Satisfactory
10	Carsin A et al.	France	2017	1	Left main bronchus	Rigid	Satisfactory
Our case	Adjeso T et al.	Ghana	2020	1	Right main bronchus	Rigid	Satisfactory

NS- not specified

## Legends

Figure 1. Chest X-ray showing LED Bulb in right main bronchus

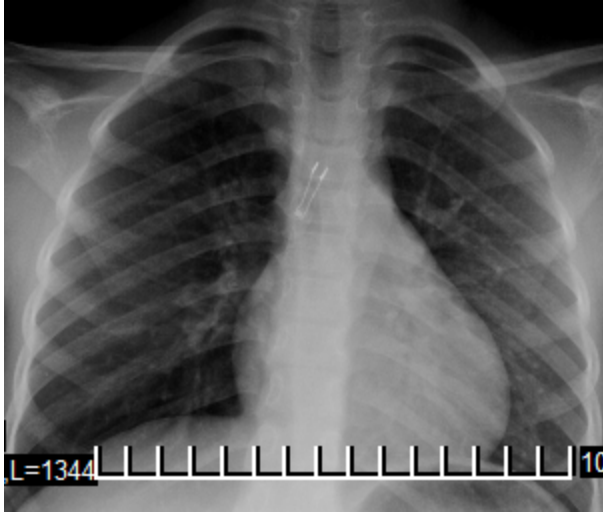



Figure 2. Retrieved LED Bulb

UNDER PEER REVIEW



UNDER