

### HAEMATOLOGICAL AND HISTOPATHOLOGICAL EFFECTS OF ARTEMISININ-BASED COMBINATION THERAPY IN HEALTHY MICE.

#### ABSTRACT

Artemisinin-based combination therapy had been recommended for the treatment of uncomplicated malaria in Africa.

**Aim:** This study investigated the effects of artesunate/amodiaquine (A/A) and dihydroartemisinin/piperaquine (D/P) on some blood parameters and histopathology of the liver and kidney of mice.

**Materials and methods:** A Complete randomized design was applied. Fifty mice were randomly assigned to five treatment groups of ten animals each. Therapeutic doses of the drugs were orally administered to the animals. Group A received normal saline (control), group B received 10/14mg/kg body weight of artesunate/amodiaquine for 3 days, group C received 10/18mg/kg of dihydroartemisinin/piperaquine for 3 days, group D received similar treatment with group B, but were followed up to 28 days, group E received similar treatment with group C but were also followed up to 28 days. After experimental period, blood samples were collected for determination of white blood cell count, white blood cell differential count, red blood cell count, packed cell volume and haemoglobin concentration. Liver and kidney were also harvested for histopathological analysis.

**Results:** Result showed that therapeutic doses of artesunate/amodiaquine and dihydroartemisinin/piperaquine had no significant ( $P > 0.05$ ) effects on hematological parameters assessed. Mild inflammation and degeneration of hepatocyte were observed in the liver of the group treated with D/P while fatty change was found in the group treated with A/A. Venous congestion was observed in the kidney of the group treated with D/P. After 28 days, degeneration of hepatocyte and inflammatory cells were observed in the liver. Shrunken glomerulus was found in the kidney of the group treated with D/P.

**Conclusion:** These drugs are detrimental to the liver and kidney even at ~~therapeutic dose~~ **therapeutic dose**, therefore, they should be used with caution.

**KEYWORDS-** Artemisinin, Dihydroartemisinin, Piperaquine, Malaria, Artesunate, Amodiaquine, antimalaria.

#### 1. INTRODUCTION

Malaria remains an important cause of illness and death in children and adults [1]. It is caused by infection of red blood cells with different strains of the protozoan (one-celled microorganism) parasites of the genus *Plasmodium*, inoculated into the humans host by a feeding infected female anopheline mosquito [1]. There were about 216 million (range 149–303 million) new cases of malaria, with an estimated 445000 deaths worldwide [2].

Malaria control requires an integrated approach, including prevention (primarily vector control) and prompt treatment with effective anti-malaria agents [1]. The earliest drugs used were the aminoquinolines, among which chloroquine was the mainstay of nearly 60 years [3]. However, due to resistance of malaria parasite to chloroquine and other antimalarial drugs, artemisinins-based combination therapy (ACT) was recommended by the World Health Organization [4]. Artemisinin is a sesquiterpene lactone with a 1, 2, 4-tioxane ring system, extracted from the Chinese herb qinghaosu (*Artemisia annua* or annual wormwood) [5]. Artemisinin is considered as a

perfect replacement for chloroquine because it is a potent and rapidly acting blood schizonticide, eliciting shorter parasite clearance time and rapid symptomatic response than chloroquine and other antimalarial drugs. [5]. Despite its efficacy, artemisinin is not soluble in water or oil; it has poor bioavailability, and a short elimination half-life in vivo (~2.5 h), high recrudescence rate of infection [6][7]. To overcome some of these problems, semisynthetic derivatives compounds of artemisinin have been developed, to improve the drug's pharmacological properties and antimalarial potency [8], they include- artesunate, arteether, artemether, artemisone and dihydroartemisinin [1]. These derivatives of artemisinin are more frequently used malaria chemotherapy, because of their effectiveness against *Plasmodium* parasite [1]. Studies have shown that monotherapy with the artemisinin derivatives resulted in some levels of treatment failures [9][10]. This has necessitated the use of combination therapy of artemisinin with other antimalarial agents known as the artemisinin – based combination therapies (ACT) [11][12]. ACT is a combination of rapidly acting artemisinin derivatives with a longer-acting partner drug- lumefantrin, amodiaquine, mefloquine, piperazine and sulphadoxine/pyrimethamine [1]. The artemisinin component rapidly clears parasites from the blood; it is also active against the sexual stages of parasite [1]. The partner drug clears the remaining parasite and provides protection against development of resistance to the artemisinin derivatives [1].

Artesunate/amodiaquine, and dihydroartemisinin/piperazine were among the five ACTs recommended by the World Health Organization for treatment of uncomplicated malaria in Africa [4]. Artesunate/amodiaquine is a combination of Artesunate and amodiaquine [13]. Artesunate is a semisynthetic derivative of dihydroartemisinin [8] while amodiaquine, is a 4-aminoquinoline with a mode of action similar to that of chloroquine [14]. This combination is well tolerated but is associated with a higher incidence of gastrointestinal disturbances than other ACTs [15]. Serious adverse events associated with amodiaquine/amodiaquine are severe neutropenia and hepatotoxicity [16][17].

Dihydroartemisinin/piperazine is a fixed-dose combination of dihydroartemisinin and piperazine (17). Dihydroartemisinin is a sesquiterpeneperoxide while piperazine is a bisquinoline compound of the 4-aminoquinoline group of antimalaria drugs [18]. It has been reported that Dihydroartemisinin/piperazine combination has adverse effect on enzymatic and non-enzymatic antioxidant status and induces marked renal and liver damages and oxidative stress in rats [19].

Due to high prevalence of malaria in Africa, these ACTs are carelessly used for presumptive treatment of fever, even in absence of laboratory confirmed malaria infection; this may lead to emergence of adverse drug events. Furthermore, despite global recommendation of ACTs for treatment of uncomplicated malaria, there is insufficient data on haematological and histopathological effects of these drugs. Therefore, this present study documented the effects of oral administration of therapeutic doses of artesunate/amodiaquine and dihydroartemisinin/piperazine on some haematological parameters and histopathology of the liver and kidney using mice model.

## **2. MATERIALS AND METHODS**

### **2.1 Experimental Site**

The study was carried out in the animal house of the Zoology Department, Nnamdi Azikiwe University, Awka.

### **2.2 Study duration**

The study was carried out from April 2018 to August 2018.

### **2.3 Experimental Animals**

Adult albino mice of 8 weeks old with average weight between  $23.5 \pm 5.7$ g were used for this study. The animals were procured from the animal house of the Faculty of Veterinary Medicine, University of Nigeria, Nsukka.

### **2.4. Procurement of Drugs**

Camosunate® (Artesunate 100mg plus Amodiaquine 300mg, manufactured by Adams Pharmaceutical, China). P-Alaxin® (Dihydroartemisinin 40mg plus Piperaquine 320mg, manufactured by Blis gvs Pharmaceutical Ltd, India) were used for the study.

### **2.5 Experimental Design**

The study was arranged in a complete randomized design. Fifty albino mice were randomly distributed into five (5) groups of ten (10) animals each ( $n=10$ ). They were kept in separate cages with sawdust as beddings. The beddings were replaced regularly for prevention of infection. The animals were fed with grower's mash (Vital feed Limited, Sapele) and were given access to water from public supply *ad libitum* till the end of the experiment. They were allowed to acclimatize for a period of one week prior to commencement of the study. The animals were identified using concentrated picric acid solution, based on their weight and drug dose received.

### **2.6 Drug Administration**

Two Camosunate tablets® (100mg of Artesunate + 300mg of Amodiaquine) and one P-Alaxin tablet® (40mg of Dihydroartemisinin + 320mg of Piperaquine) were powdered separately in a mortar, mixed with 20ml of distilled water and administered in mg/kg body weight as recommended by the World Health Organization [1]. Drugs were administered as aqueous suspensions with oral gavage as follows-

Group A received normal saline (control)

Group B received 10/14 mg/kg body weight of Artesunate/amodiaquine (A/A) for 3 days

Group C received 10/18 mg/kg body weight of Dihydroartemisinin/piperaquine (D/P) for 3 days

Group D received 10/14 mg/kg body weight of Artesunate/amodiaquine for 3 days but were followed up to 28 days (served as recovery group for A/A)

Group E received 10/18 mg/kg body weight of Dihydroartemisinin/piperaquine for 3 days but were also followed up to 28 days (served as recovery group for D/P).

### **2.7 Collection of blood samples**

After drug administration, blood samples were collected through retro – orbital sinus with a capillary tube into ethylenediaminetetraacetic acid (EDTA) tubes.

### **2.8 Estimation of White blood cell count (WBC)**

White blood cell count was estimated with improved Neubauer chamber using the principle of a calibrated capillary tube for blood sampling [20].

### **2.9 White blood cell differential count**

White blood cell differential count was carried out by examination of blood smear [20].

### **2.10 Estimation of Packed Cell Volume (PCV)**

Packed cell volume was estimated using centrifugation method[21].

### **2.11 Red Blood Cell count(RBC)**

Red blood cell count was estimated with improved Neubauer chamber using the principle of a calibrated capillary tube for blood sampling [20].

### **2.12 Estimation of Haemoglobin concentration(Hb)**

Haemoglobin concentration was estimated using calorimetric method.

### **2.13 Collection of Tissue for Histopathological Studies**

Animal from each group were anesthetized in chloroform vapour and dissected, liver and kidney were collected for histopathological analysis.

### **2.14 Histopathological Analysis**

Histopathological analysis was carried out as described by Bancroft and Gamble (2002) [22].

The liver and kidney from the various groups were collected, and immediately fixed in 10% formol saline. The organs were dehydrated in ascending grades of ethanol (70%, 80%, 90%, 100%, Absolute I, Absolute II), within 1 hour intervals, then cleared using xylene. The tissue block was infiltrated with paraffin, embedded with molten paraffin wax, sectioned with microtome, then stained with hematoxylin and eosin, and examined under Olympus/3H light microscope-Japan (x400) for histopathological changes. Photomicrographs were captured using a Moticam Images plus 2.0 digital camera fixed onto the light microscope.

### **2.15 Statistical Analysis**

Statistical Analysis was carried out using statistical package for social sciences (SPSS) version 22. Comparisons between groups were performed with one-way analysis of variance (ANOVA).

## **3. Results**

### **3.1 Effect of artesunate/amodiaquine and dihydroartemisinin/piperazine on haematological parameters.**

#### **3.1.2 White blood cell count(WBC)**

Result from table 1 showed insignificant increase ( $P > 0.05$ ) in white blood cell count in the group treated with A/A and D/P compared to the control group.

#### **3.1.3 White blood cell differential count**

From table 1, Lymphocyte count slightly increased in all the treated groups and their recovery groups but the increase was statistically non significant ( $P > 0.05$ ) when compared to the control.

Decrease in neutrophil count was observed in the experimental groups, when the values were compared statistically, no variation ( $P > 0.05$ ) was observed between the treated groups and the control group.

Basophil and monocyte counts in both treated and recovery groups showed no significant difference ( $P > 0.05$ ) when compared to the control group.

Insignificant decrease ( $P > 0.05$ ) was observed in eosinophil count in all the treated groups and their recovery groups compared to the control group.

### 3.1.4 Red blood cell count(RBC)

No significant difference ( $P > 0.05$ ) was observed in red blood cell count of the group treated with artesunate/amodiaquine, group treated with dihydroartemisinin/piperaquine and the recovery groups compared to the control group (Table 1).

### 3.1.5 Packed cell volume(PCV)

All the treated groups and their recovery groups showed no significant ( $P > 0.05$ ) changes in packed cell volume when compared to the control group (Table 1).

### 3.1.6 Haemoglobin concentration (Hb)

There was no significant alteration ( $P > 0.05$ ) in haemoglobin concentration of all the treated groups and their recovery groups compared to the control group.

**Table 1 Effects of Artesunate/amodiaquine and dihydroartemisinin/piperaquine on hematological parameters of mice.**

Parameters	Treatment Groups				
	Control	A/A group	D/P group	A/A recovery group	D/P recovery group
WBC( $\text{mm}^3 \times 10^3$ )	7.65 ± 0.98	8.51 ± 0.11	8.68 ± 0.25	7.73 ± 0.39	8.05 ± 0.76
Lymphocyte(%)	61.83 ± 4.24	72.50 ± 2.18	75.66 ± 49	68.50 ± 4.50	66.20 ± 0.76
Neutrophil(%)	35.50 ± 3.88	24.66 ± 2.24	23.00 ± 0.36	29.83 ± 10.70	26.80 ± 14.60
Basophil (%)	0.33 ± 0.21	0.33 ± 0.21	0.10 ± 0.22	0.10 ± 0.22	0.60 ± 0.24
Eosinophil (%)	1.16 ± 1.66	0.66 ± 0.21	0.66 ± 0.21	0.66 ± 0.21	0.66 ± 0.21
Monocyte (%)	0.50 ± 0.22	0.50 ± 0.22	0.33 ± 0.21	0.66 ± 0.21	0.66 ± 0.21
RBC( $\times 10^{12}/\text{ml}$ )	8.08 ± 0.38	8.63 ± 0.04	8.53 ± 0.49	8.11 ± 0.11	8.15 ± 0.26
PCV (%)	40.67 ± 0.88	40.33 ± 0.91	43.50 ± 0.42	40.00 ± 0.57	40.17 ± 0.91
Hb (g/dl)	11.04 ± 0.04	10.60 ± 0.24	11.10 ± 0.08	11.02 ± 0.010	11.25 ± 0.11

## 3.2 Effects of artesunate/amodiaquine and dihydroartemisinin/piperaquine on histopathology of the liver of healthy mice.

Minimal periportal inflammatory cells infiltration and widespread vacuolar **degeneration** of hepatocytes were observed in liver of the group treated with artesunate/amodiaquine (fig 2) while the group treated with dihydroartemisinin/piperaquine showed apparently normal portal areas but has widespread vacuolar degeneration of hepatocytes and fatty change (fig 3). After 28 days recovery period, panlobular vacuolar degeneration of hepatocytes

was observed in the liver of the group treated with artesunate/amodiaquine (fig 4) while inflammatory cells were found in the group treated with dihydroartemisinin/piperazine (fig 5)

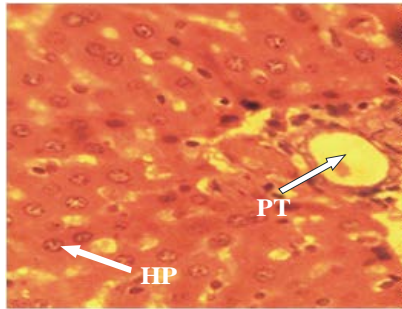


Figure 1: A section of liver from control Group (normal liver) showing normal hepatocytes (HP) and normal portal tract (PT). H and E, x 400.

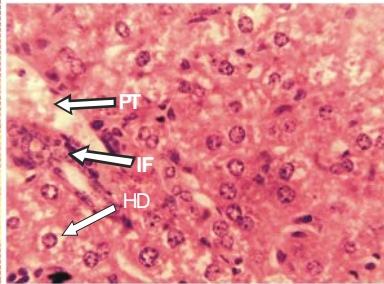


Figure 2: A section of liver from the group treated with 10/14 mg/kg of artesunate/ amodiaquine, showing minimal inflammation (IF), hepatocyte degeneration (HD) and portal tract (PT). H and E, x400.

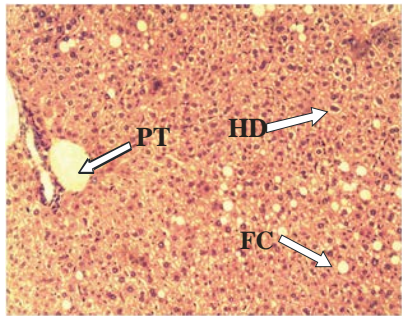


Figure 3: A section of liver from the group treated With 10/18mg/kg of dihydroartemisinin/piperazine for 3 days, showing hepatocyte degeneration (HD) of Artesunate/amodiaquine, then and fatty change (FC). Portal tract(PT). followed up to 28days, showing H and E,x100. hepatocyte degeneration (HD). H and E, x400

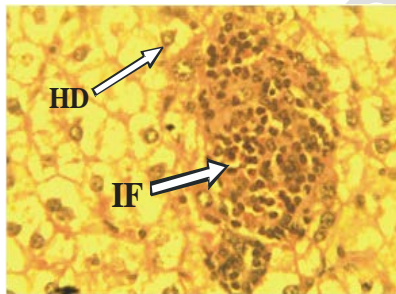
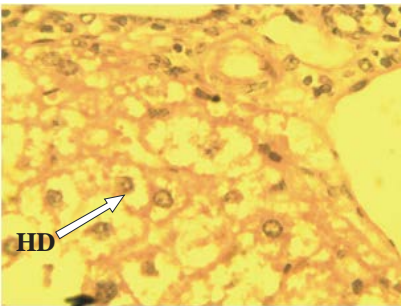


Figure 5: A section of liver from the group treated with dihydroartemisinin/piperazine, then followed up to 28 days, showing inflammations (IF) and hepatocyte degeneration (HD) H and E,x 400.

### 3.3 Effects of artesunate/amodiaquine and dihydroartemisinin/piperazine on histopathology of the kidney in healthy mice.

There was no remarkable histopathological change in the kidney tissue of the group treated with artesunate/amodiaquine(fig 7), however, congestion of blood vessels at the medulla was found in the group treated with dihydroartemisinin/piperazine(fig 8).After 28 days follow up, there was a focal area of inflammatory reactions in the group treated with dihydroartemisinin/piperazine (fig

9) while the kidney of the group treated with artesunate/amodiaquine was without any histopathological change(fig 10)

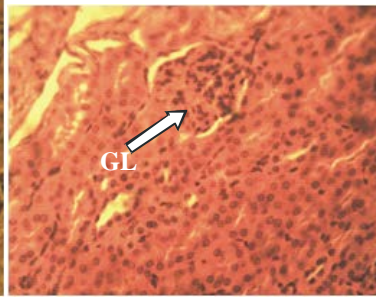
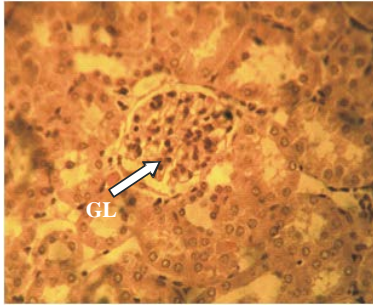


Figure 6: A section of kidney from control

Figure 7: A section of kidney from the group (normal liver) showing normal hepatocytes (HP) and normal glomerulus (GL). H and E, x 400.

treated with 10/14 mg/kg of artesunate/ amodiaquine, showing normal glomerulus (GL). H and E,x400

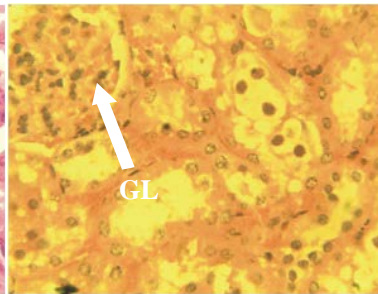
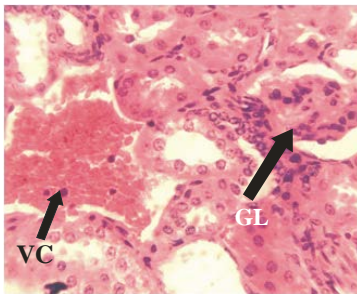


Figure 8: A section of kidney from the group treated with 10/18 mg/kg of dihydroartemisinin/piperazine, showing venous congestion (VC) and glomerulus (GL)

Figure 9: A section of kidney from the group treated with 10/14mg/kg artesunate/amodiaquine then followed up to 28 days, showing normal glomerulus (GL)

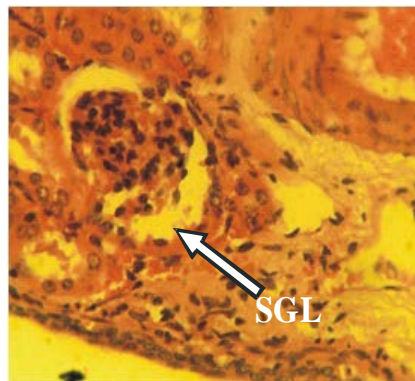

Figure 10: A section of the kidney from the group treated with dihydroartemisinin/piperazine, then followed up to 28 days, showing shrunken glomerulus(SGL).

#### 4. Discussion

In this study, the effects of artemisinin-based combination therapy on haematological parameters and histopathology of the liver and kidney was investigated in mice. Total white blood cell count and lymphocyte count were insignificantly increased. This may be due to reaction of body immune system to the drugs. White blood cells are important part of body's defense which made up the immune system. Slight decrease in neutrophil and eosinophil counts observed, may indicate toxic

effects of the drugs to bone marrow. Some antimalaria drugs or their metabolites are directly toxic to bone marrow and this inhibits the production of neutrophil [23]. Artesunate/amodiaquine combination may induce neutropenia and increase risk of infection (18). This finding is in line with the report of (Obianime and Aprioku, 2011) [3] that artesunate and dihydroartemisinin caused dose-dependent increase in white blood cell count and lymphocyte count, decrease in neutrophil count. Agomo *et al* (2008) [24] also reported slight increase in white blood cell count after treatment of uncomplicated malaria with artesunate/mefloquine, the increase was more prominent in lymphocyte count with a decrease in neutrophil as treatment progressed. Intravascular haemolysis, leucocytosis with significant decrease in neutrophil in the group of rats treated with Artesunate had also been reported [25].

Levels of red blood cell count, packed cell volume and haemoglobin concentration were not altered in this study. This indicates that therapeutic doses of these drugs may not induce anaemia. Artesunate and dihydroartemisinin had been reported to cause no significant effect on red blood cell, haemoglobin and packed cell volume [3]. Kareem *et al* (2014) [26] reported insignificant alteration in packed cell volume, red blood cell count and white blood cell count after administration of therapeutic dose of P-alaxin (dihydroartemisinin/piperaquine) to healthy individuals. These minor alterations observed in the haematological parameters were reversed when drug administration was terminated. Therefore these drugs had no long term effect on the blood parameters.

In the liver, mild inflammatory cells found in the group treated with artesunate/amodiaquine and in the recovery group treated with dihydroartemisinin/piperaquine is an indication of liver inflammation like hepatitis. Hepatitis has been reported after administration of treatment doses of amodiaquine, alone or in combination with artesunate [27]. Fatty change observed in the group treated with dihydroartemisinin/piperaquine indicates disruption in the process of fat metabolism resulting in excessive accumulation of fats in the liver. Studies with animals had shown that artemisinin and its analogues cause acute hepatotoxicity in guinea pig [28]. Al-Ani *et al* (2013) [29] discovered degenerative hepatocytes, congestion of the central vein, vacuolization of cytoplasm, infiltration of inflammatory cells, dilation and congestion of cytoplasm and fatty infiltration in the liver of rats treated with artemisinin. The liver is susceptible to these toxicities because all the foreign substances and drugs are metabolized in the liver. Certain medicinal agents, when taken in overdose and sometimes even when introduced within therapeutic ranges may injure the liver [30].

Mild congestion and shrinkage of glomerulus observed in the group treated dihydroartemisinin/piperaquine may indicate renal toxicity. Drugs can exert toxic effect on the glomerulus [31]. As most drugs are excreted by the kidney, it is reasonable to assume that the kidney itself could be a privileged target of their toxic action [31]. Amaza *et al* (2013) [32] reported glomerulus degeneration and venous congestion after treatment with artesunate. It was hypothesized that the release of malaria antigens activates monocyte cells, to release proinflammatory cytokines and activate cell-mediated response, causing renal problems [33].

## 5. CONCLUSION

This study demonstrated that oral administration of therapeutic doses of artesunate/amodiaquine and dihydroartemisinin/piperaquine in healthy mice had no haematological toxicity, but potentially toxic to the liver and kidney. Though there was sign of recovery, but new toxicities emerged in both organs after 28 days follow up. Therefore, caution should be observed when using these drugs especially in patients with liver and kidney impairments.



## COMPETING INTERESTS DISCLAIMER:

Authors have declared that no competing interests exist. The products used for this research are commonly and predominantly use products in our area of research and country. There is absolutely no conflict of interest between the authors and producers of the products because we do not intend to use these products as an avenue for any litigation but for the advancement of knowledge. Also, the research was not funded by the producing company rather it was funded by personal efforts of the authors.

## REFERENCES

1. World Health Organization. World malaria report, 2015. WHO, Geneva
2. World Health Organization. World Malaria Report, 2017. WHO, Geneva
3. Obianime, AW, Aprioku JS. Mechanism of action of arteminins on biochemical hematological and reproductive parameters in male guinea pig. *International Journal of Pharmacology*. 2011; 7(1):84-95.
4. World Health Organisation. A background document for the WHO global strategy for containment of antimicrobial resistance, 2001. WHO, Geneva
5. Qinghaosu Antimalaria Coordinating Research Group. Antimalaria studies on Qinghaosu. *Chinese Medical Journal*, 1979; 92 (12): 811–816.
6. Ashton M, Sy ND, Van Huong N. Artemisinin kinetics and dynamics during oral and rectal treatment of uncomplicated malaria. *Clinical Pharmacology and Therapeutics*. 1998; 63(4): 482–493.
7. Li QP, Weina J, Milhous W K. (2007). Pharmacokinetic and pharmacodynamic profiles of rapid-acting artemisinins in the antimalarial therapy. *Current Drug Therapy*. 2007; 2 (3): 210–223.
8. Klayman D L. Qinghaosu (artemisinin): an antimalarial drug from China. *Science*. 1985; 228 (4703): 1049–1055.
9. Price RN, Van vugt M, Nosten F, Luxemburger C, Brockman, A., Phaipun, I., *et al.*, Artesunate versus artemether for the treatment of recrudescence multidrug-resistant falciparum malaria. *American Journal of Tropical Medicine and Hygiene*. 1998; 59: 883 – 888.
10. McIntosh HM, Olliaro P. Artemisinin derivatives for treating uncomplicated malaria. *Cochrane Database of Systematic Review*. 2000; (2): 256-265
11. World Health Organisation. Guidelines for treatment of malaria, 2006. WHO, Geneva.
12. Olliaro, PL, Taylor W. Developing artemisinin treatment drug resistance falciparum malaria. *Journal of Postgraduate Medicine*, 2004; (50): 40 - 44
13. Merck I. An encyclopedia of chemicals, drugs and biological. USA; Rahway NJ, 1983.
14. Tarning J, Lindgardh N, Sandberg S, Day NJ, White NJ, Ashton M. Pharmacokinetics and metabolism of the antimalarial piperazine after intravenous and oral single doses to the rat. *Journal of Pharmaceutical Sciences*. 2008; (97): 3400–3410.
15. World Health Organisation. World Malaria Report, 2010. WHO, Geneva.
16. Hatton CS, Peto TE, Bunch C, Pasvol G, Russell SJ, Singer CR *et al.* The frequency of severe neutropenia associated with amodiaquine prophylaxis against malaria. *Lancet*. 1986; (1): 411-414

17. World Health Organisation. World Health Organisation model list of essential medicines, 2019. WHO, Geneva. Hdl:10665/325771
18. Davis TM, Hung TY, Sim IK, Karunajeewa HA, Ilett KF. Piperaquine: a resurgent antimalarial drug. *Drugs*; 2005; 65(1):75-87.
19. Olayinka ET, Ore A. Alterations in Antioxidant Status and Biochemical Indices Following Administration of Dihydroartemisinin-Piperaquine Phosphate (P-ALAXIN®). *Journal of Pharmacy and Biological Sciences*. 2013;5 (4): 43-53.
20. Baker FJ, Silverton RE, Pallister CJ. *Introduction to Medical Laboratory Technology*. Nigeria: Bouty press, 1998.
21. Dacie SJV, Lewis SM. *Practical Haematology*. Edinburgh: Churchill Livingstone, 1984.
22. Bancroft JD, Gamble M. *Theory and Practice of Histological Techniques*. Edinburgh: Churchill Livingstone, 2002.
23. David FS. *Transfusion Medicine Reviews*. 1993;7 (4): 268-274
24. Agomo, UP, Merimikwu MM, Ismaila MW, Omalu IT, Oguiche VI, Odey S. Efficacy, Safety, and Tolerability of Plasmodium falciparum Malaria in four geographical zones of Nigeria. *Malaria Journal*. 2008;7:172.
25. Omotosho, OO, Mutiu AA, Oyeyemi MO. Comparative Study of the Haematology and Serum Biochemistry of Male Wistar Rats Treated with Chloroquine and Artesunate. *Journal of Physiology and Pharmacology Advances*. 2014.4(8): 413-419.
26. Kareem F, Ifabunmi A, Osonuga O, Mutiu A, Alabi E, Ajani O. Haematological Changes Associated with Administration of Therapeutic dose of P-Alaxin in Healthy Adult Wistar Rats. *Journal of Natural Sciences Research*. 2014;4:20.
27. Orrel C, Taylor WR, Olliaro P. Acute asymptomatic hepatitis in a healthy normal volunteer exposed to oral doses of amodiaquine and Artesunate. *Transaction of Royal Society Tropical Medicine and Hygiene*. 2001;95:517-518
28. Nwanjo HU, Oze G. Acute Hepatotoxicity Following Administration of Artesunate in Guinea pigs. *Internet Journal of Toxicology*. 2007;4: 1-8
29. Al-Ani IA, Al-Janabi ST, Hamoudi SR. Effect of some antimalaria drugs on the liver, biochemical and histopathological studies. *International malaria symposium*, 2013. Pp. 1-17.
30. Aashish P, Tarun S, Pallavi B. Drug-induced Hepatotoxicity: A Review. *Journal of Applied Pharmaceutical Science*. 2012; 2(5):233-243. DIO: 10 7324/japs.2012.2541
31. Bartoli E. Adverse effects of drugs on the kidney. *European Journal of Internal Medicine*. 2016; 28:1-8. DIO: <http://doi.org/10.1016/j.ejim.2015.12.001>
32. Amaza DS, Momoh M, Ziraheil JV, Rufai AA, Sambo N, Amos L *et al.* Effect of Oral Administration of Artesunate on the Histology of the Kidney in Albino Rat. *Journal of Dental and Medical Sciences*. 2013;3(5): 15-20.
33. Barsoun RS. Malaria nephropathies. *Nephrology Dialysis Transplant*. 1998; 13: 1588-97.
34. Institution of Laboratory Animal Resources (U.S), Committee on Care and Use of Laboratory Animals; National Institution of Health (U.S). *Guide for care and use of laboratory animals*. NIH publication no. 85-23. U.S: Bethesda, Md, 1985.