

## **Case study**

### **Budd-Chiari syndrome: an unusual complication of sarcoidosis.**

#### **Abstract:**

Hepatic involvement during sarcoidosis is common but rarely symptomatic. Budd-Chiari syndrome is an exceptional but potentially serious complication. We report the case of a 38-year-old woman with a Budd-Chiari syndrome complicating multisystemic sarcoidosis.

A case of 38 year old woman was diagnosed with a Budd-Chiari syndrome complicating multisystemic sarcoidosis has been reported in present case study.

**Keywords:** Sarcoidosis, Budd-Chiari syndrome, Cholestasis.

UNDER PEER REVIEW

## Introduction:

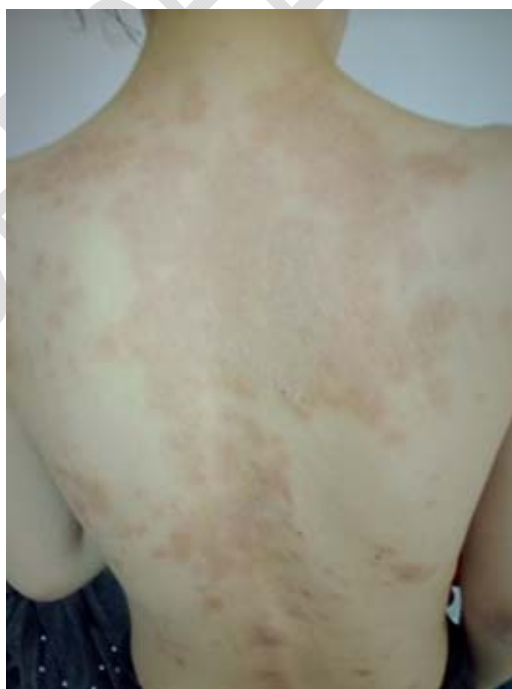Sarcoidosis is an inflammatory disease with poorly known etiologies. It is often caused by an exaggerated immune response to some antigens of susceptible individuals (1).

It is a systemic granulomatosis. The main localization are lymph node and lungs, but it can involve several other organs (2-4). Extra pulmonary manifestations are reported in half of the cases of systemic sarcoidosis (5). Liver involvement is often asymptomatic. Clinical involvement is observed in less than 20% of cases. In symptomatic patients, elevated liver enzymes are present in only 10-30% of cases (5,6) and hepatosplenomegaly is noted in about 20% of cases (2).

Bud Chiari syndrome (BCS) is exceptional during sarcoidosis (7). **We report a case of BCS complicating systemic sarcoidosis (Not needed but Author need to describe the clinical and diagnostic fature of BCS to give an overview to reader)**

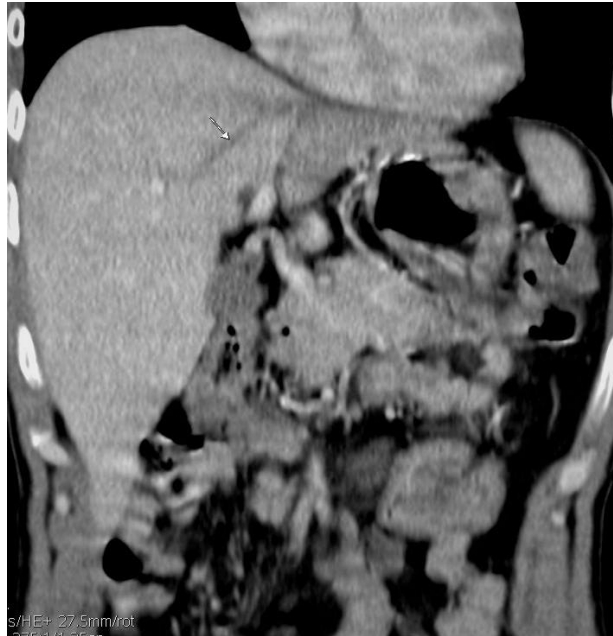## Case Presentation:

**We report the (In present report )** a case of a 38-year-old patient with a 4-year history of type 2 diabetes and 8-year history of multisystemic sarcoidosis with skin, lymph node and lung involvement (**was reported at .....place of institution or locality**). The diagnosis was established in front of several findings: disseminated erythematous squamous papular plaques (Fig.1), hypercalcemia, elevation of angiotensin II converting enzyme, hilar and mediastinal adenopathies with pulmonary parenchymal involvement associated with cutaneous and bronchial granulomatosis.



**Fig.1:** Extensive erythematous squamous lesions on the back.

The patient was treated with hydroxychloroquine and long-term corticosteroid therapy with favorable clinical and radiologic outcomes. During the follow-up, the patient reported right hypochondrial pain. The laboratory workup revealed a prothrombin level of 76%, seven-times-normal anicteric biological cholestasis, and a twice-normal cytolytic. The hepatic angioscanner revealed an absence of opacification of the left and median supra-hepatic veins with perfusion abnormalities in the left liver, all consistent with BCS (fig.2). Fibroscopy revealed grade I esophageal varices.

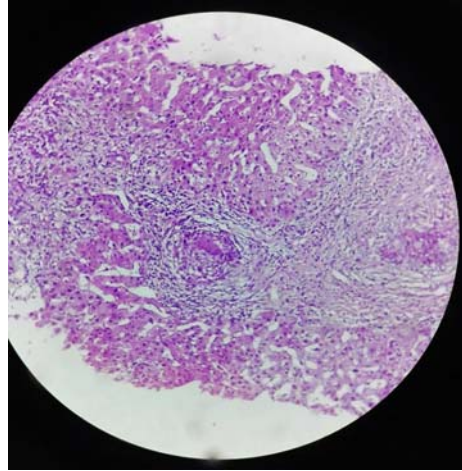


**Fig.2:** Coronal section of an abdominal angioscanner showing the absence of opacification of the medial suprahepatic vein (arrow).

As part of the etiologic evaluation of the BCS, a complete investigation including hereditary and acquired prothrombotic conditions was performed with a negative result.

The diagnosis of primary BCS complicating systemic sarcoidosis was then established. Viral serology and immunological workup were performed in front of a persisting significant cholestasis, but they were negative.

Liver biopsy-puncture revealed gigante-cellular granulomatous and epithelioid lesions without necrosis associated with ductopenia and portal fibrosis consistent with sarcoidosis (Fig.3). The patient was treated with anticoagulant therapy, Prednisolone (40mg/day) and Ursodeoxycholic Acid (15mg/Kg/day).



**Fig.3:** Hepatic parenchyma containing epithelioid and gigantocellular granulomas.

### **Discussion:**

Liver damage during sarcoidosis is common but rarely symptomatic. In the minority of symptomatic cases, cholestasis is most often discovered during follow-up of known patients with systemic sarcoidosis, which is the case of our patient (8-10). Liver biology and imaging are recommended during the initial evaluation of sarcoidosis in order to early detect liver damage (11). Liver biopsy is indicated in cases of moderate or severe disturbances of liver tests (11).

Cholestasis appears to be secondary to the progressive destruction of the interlobular bile ducts, due to inflammatory infiltration of the basement membranes and the formation of the portal granuloma. Portal granuloma causes portal tract fibrosis, bile duct destruction and ductopenia (12).

More serious complications such as severe anicteric cholestasis, portal hypertension, BCS or cirrhosis are less common (7,13).

We present (In present case report, an) the exceptional case of a multisystemic sarcoidosis complicated by a portal cavernoma (has been presented). To our knowledge, only 11 cases of BCS related to hepatic sarcoidosis have been reported in the literature, including two pediatric cases (The literature search revealed only 11 cases of BCS related to hepatic sarcoidosis including two pediatric cases) (13-23). The main mechanism of BCS complicating sarcoidosis is not clearly elucidated. Granulomatous lesions are thought to cause external compression of the hepatic veins. They can also directly involve the vascular wall, resulting in lumen narrowing and leading to venous stasis and thrombotic occlusion (12,14,16). We believe that the development of BCS in our patient may be due to both extrinsic compression and intrinsic granulomatous infiltration of the hepatic veins.

The treatment of hepatic involvement during sarcoidosis is not well codified. Corticosteroid therapy at a dose of 40-60 mg/kg/day is indicated for moderate to severe hepatic impairment, but cannot prevent progression to cirrhosis and portal hypertension (24). Treatment of BCS associated with sarcoidosis is based on cause management, venous thrombosis prevention and hepatic venous drainage

restoration. This may require thrombolytic treatment, angioplasty, transjugular intrahepatic porto-systemic shunt, surgical shunt, or liver transplantation (25-27).

**Conclusion:**

Although BCS is an exceptional complication of hepatic sarcoidosis, physicians should always consider it. A Doppler ultrasound should be performed in front of any evocating sign, in order to establish an early diagnosis. However, the progression to portal hypertension and hepatocellular failure is unpredictable.

UNDER PEER REVIEW

## Références :

1. Nunes H, Soler P, Valeyre D. Pulmonary sarcoidosis. *Allergy*. mai 2005;60(5):565•82.
2. Baughman RP, Lower EE. Sarcoidosis. In: Kasper D, Fauci A, Hauser S, Longo D, Jameson JL, Loscalzo J, éditeurs. *Harrison's Principles of Internal Medicine* [Internet]. 19<sup>e</sup> éd. New York, NY: McGraw-Hill Education; 2014 [cité 10 juin 2020]. Disponible sur: [accessmedicine.mhmedical.com/content.aspx?aid=1120813969](https://accessmedicine.mhmedical.com/content.aspx?aid=1120813969)
3. Esfeh JM, Culver D, Plesec T, John B. Clinical presentation and protocol for management of hepatic sarcoidosis. *Expert Review of Gastroenterology & Hepatology*. 4 mars 2015;9(3):349•58.
4. Syed U, Alkhawam H, Bakhit M, Companioni RAC, Walfish A. Hepatic sarcoidosis: pathogenesis, clinical context, and treatment options. *Scandinavian Journal of Gastroenterology*. 1 sept 2016;51(9):1025•30.
5. Soto-Gomez N, Peters JI, Nambiar AM. Diagnosis and Management of Sarcoidosis. *AFP*. 15 mai 2016;93(10):840•8.
6. Ebert EC, Kierson M, Hagspiel KD. Gastrointestinal and hepatic manifestations of sarcoidosis. *Am J Gastroenterol*. déc 2008;103(12):3184•92; quiz 3193.
7. Ayyala US, Padilla ML. Diagnosis and treatment of hepatic sarcoidosis. *Curr Treat Options Gastroenterol*. 2006;9(6):475•83.
8. Elloumi H, Marzouk S, Tahri N, Bahloul Z, Azouz MM. Sarcoidose et atteinte hépatique : étude de 25 cas. *La Revue de Médecine Interne*. 1 nov 2012;33(11):607•14.
9. Valla, Plessier. SYNDROME DE BUDD CHIARI. 2010;13.
10. Devaney K, Goodman Z, Epstein M, Zimmerman H, Ishak K. Hepatic sarcoidosis. Clinicopathologic features in 100 patients. *Am J Surg Pathol*. 1993;17(12):1272•80.
11. Valeyre D, Prasse A, Nunes H, Uzunhan Y, Brillet P-Y, Müller-Quernheim J. Sarcoidosis. *The Lancet*. 29 mars 2014;383(9923):1155•67.
12. Karagiannidis A, Karavalaki M, Koulaouzidis A. Hepatic sarcoidosis. *Ann Hepatol*. 2006;5(4):251•6.
13. Ennaifer R, Bacha D, Romdhane H, Cheikh M, Nejma HB, BelHadj N. Budd-Chiari Syndrome: An Unusual Presentation of Multisystemic Sarcoidosis. *Clin Pract*. 28 sept 2015;5(3):768.

14. Delfosse V, de Leval L, De Roover A, Delwaide J, Honoré P, Boniver J, et al. Budd-Chiari syndrome complicating hepatic sarcoidosis: definitive treatment by liver transplantation: a case report. *Transplant Proc.* oct 2009;41(8):3432•4.
15. Deniz K, Ward SC, Rosen A, Grewal P, Xu R. Budd-Chiari syndrome in sarcoidosis involving liver. *Liver Int.* avr 2008;28(4):580•1.
16. Efe C, Shorbagi A, Ozseker B, Yilmaz H, Sokmensuer C, Balkanci F, et al. Budd-Chiari syndrome as a rare complication of sarcoidosis. *Rheumatol Int.* oct 2012;32(10):3319•20.
17. Krishnamoorthy G, Ray G, Agarwal I, Kumar S. Unusual presentation of sarcoidosis in a child. *Rheumatol Int.* mai 2012;32(5):1453•5.
18. Maàmouri N, Ketari S, Habessi H, Noura K, Dhaou BB, Boussema F, et al. Syndrome de Budd-Chiari secondaire à une sarcoïdose. *Gastroentérologie Clinique et Biologique.* 2009;(33):147•8.
19. Nataline MR, Goyette RE, Owensby LC, Rubin RN. The Budd-Chiari syndrome in sarcoidosis. *JAMA.* 23 juin 1978;239(25):2657-.
20. Sghier IA, Billah NM. Le syndrome de Budd-Chiari: une complication rare de la sarcoïdose hépatique (à propos d'un cas). *The Pan African Medical Journal.* 2016;23.
21. Van Brusselen D, Janssen CEI, Scott C, Bevers N, Roskams T, Wouters C, et al. Budd-Chiari syndrome as presenting symptom of hepatic sarcoidosis in a child, with recurrence after liver transplantation. *Pediatr Transplant.* mars 2012;16(2):E58-62.
22. Odah T, Al-Khazraji A, Idriss R, Morrow M, Curry MP. Budd-Chiari Syndrome in a Patient With Simultaneous Diagnosis of Hepatic Sarcoidosis and Nodular Regenerative Hyperplasia. *ACG Case Reports Journal.* sept 2019;6(9):e00200.
23. Russi EW, Bansky G, Pfaltz M, Spinaz G, Hammer B, Senning A. Budd-Chiari syndrome in sarcoidosis. *Am J Gastroenterol.* janv 1986;81(1):71•5.
24. Bakker GJ, Haan YCL, Maillette de Buy Wenniger LJ, Beuers U. Sarcoidosis of the liver: to treat or not to treat? *Neth J Med.* oct 2012;70(8):349•56.
25. Langlet P, Valla D. Is surgical portosystemic shunt the treatment of choice in Budd-Chiari syndrome? *Acta Gastroenterol Belg.* sept 2002;65(3):155•60.
26. Düşüceli E, Sancak T, Sezgin S, Bilgiç S, Sanlidilek U. Percutaneous transluminal angioplasty of the inferior right hepatic vein for the treatment of Budd-Chiari syndrome. *Acta Gastroenterol Belg.* sept 2004;67(3):306•8.

27. Menon KVN, Shah V, Kamath PS. The Budd-Chiari syndrome. N Engl J Med. 5 févr 2004;350(6):578-85.

UNDER PEER REVIEW