

Basil (*Ocimum basilicum* L.) and/or Celery (*Apium graveolens* L.) Leaves Aqueous Extracts Role In opposition to Drinking Contaminated Water Induced Male Rats Urinary Stones and Renal Deteriorations

Comment [H1]: Title needs to be more meaningful and scientific names may be omitted here

ABSTRACT

Aims: The current research was designed to explore the role of basil and/or celery leaves aqueous extracts against urinary stones (urolithiasis) and renal deteriorations induced by drinking water contaminated with ethylene glycol (EG) and ammonium chloride (AC) in male rats.

Place and Duration of Study: The Medical Research Center of the Faculty of Pharmacy, Al-Azhar University, Cairo, Egypt. The experiment duration was (35 days), 7 days for acclimatization followed by 28 days experimentation.

Comment [H2]: Remove bracket

Methodology: Fifty-five adult male Sprague-Dawley rats were classified randomly into 5 groups of ten animals each, except urolithiatic control group which contained 15 rats. Rats were treated as follow: Group I: healthy control group (HCG), rats drank distilled water and received a placebo 1 ml distilled water daily by intra-gastric tube ; Group II: urolithiatic control group (UCG), rats drank distilled water containing (0.75% EG and 1% AC) and the access to water was *ad libitum* and received 1 ml distilled water daily by intra-gastric tube.; Group III : urolithiatic rats supplemented with aqueous basil extract(U+ABE), rats drank distilled water containing (0.75% EG and 1% AC) and the access to water was *ad libitum* and supplemented with (200mg/kg body weight) aqueous basil extract daily by intra-gastric tube.; Group IV: urolithiatic rats supplemented with aqueous celery extract(U+ACE), rats drank distilled water containing (0.75% EG and 1% AC) and the access to water was *ad libitum* and supplemented with (200mg/kg body weight) aqueous celery extract daily by intra-gastric tube. ; Group V: urolithiatic rats supplemented with aqueous basil and celery extract(U+ABE+ACE) , rats drank distilled water containing (0.75% EG and 1% AC) and the access to water was *ad libitum* and supplemented with (100mg/kg body weight) aqueous basil extract and (100mg/kg body weight) aqueous celery extract daily by intra-gastric tube. At the end of the study (28) days, 24 h urine samples were collected from each individual animal, then rats were sacrificed under sodium barbiturate anesthesia. Blood samples were collected from the hepatic portal vein, serum was separated for biochemical analyses. Kidney samples were separated for tissue homogenate preparation, urinary bladder and ureters were separated and opened to collect urinary calculi.

Comment [H3]: Remove bracket

Comment [H4]: and

Results: Research results documented that basil and celery aqueous extracts contain significant amount of active constituents including flavonoids and polyphenols. Drinking water contaminated with EG and AC caused significant decrease ($p \leq 0.01$) in urine volume, pH, urinary and renal magnesium levels with significant increase ($p \leq 0.01$) in urinary and renal calcium, phosphate and oxalate levels. It also caused significant increase in kidney function tests [serum creatinine, uric acid, urea, as well as cystatin C] levels .Also renal enzyme activities of [acidic phosphatase (ACP), alanine aminotransferase (ALT), aspartate aminotransferase (AST) and alkaline phosphatase (ALP)] activities were significantly increased ($p \leq 0.01$) with significant decrease in renal lactate dehydrogenase (LDH) activity. Water contamination also induced renal mitochondrial dysfunction (decreased complex-I activity), apoptosis (increased caspase-3 activity) in association with a state of renal oxidative stress (increased renal malondialdehyde (MDA) level related to decreased renal reduced glutathione (GSH) level and superoxide dismutase (SOD) activity). Inflammation (increased renal tumor necrosis factor- alpha (TNF- α) and interleukin 18 (IL-18) with suppressed

immune function (decreased serum immunoglobulin (IgG and IgM) levels were observed in urolithiatic control group. As a result of biochemical changes resulted from EG and AM administration mineral precipitation and urinary stones formation was observed in urolithiatic control group. Oral administration of aqueous basil and /or celery extracts to urolithiatic rats improved urine analysis parameters, renal functions, renal enzymes activities and mitochondrial function. Aqueous extracts also counteracted renal oxidative stress, inflammation, suppressed immune response and urinary stones formation.

Conclusion: research results proved that aqueous basil and/or celery extracts counteracted and ameliorated urinary stones formation and renal deteriorations associated with drinking water contaminated with EG and AC. The most significant improvements were recorded in the group supplemented with both extracts.

Keywords: Water contamination ; ethylene glycol ; ammonium chloride; urolithiasis; renal deteriorations; basil; celery; aqueous extracts.

1. INTRODUCTION

Fresh water availability affects the world economy especially as a reflect on human health. Water contamination became a common problem worldwide. Water contamination may be natural or man-made. The types and concentrations of natural contaminants depend on the nature of the geological materials through which the groundwater flows and quality of the recharge water [1].

Man-made water contamination is caused by-products of industry and agriculture, including heavy metals, hazardous chemicals, dyes and compounds like insecticides and fertilizers. Improper storing or disposing of household chemicals such as paints, detergents, oils, solvents, medicines, pesticides, batteries, gasoline and diesel fuel can lead to ground water contamination. According to United Nations report 2003 every day 2 million tons of sewage, industrial and agricultural waste are discharged into the world's water [2].

Ethylene glycol (EG) is an odorless, electrically neutral polyalcohol and a common solvent for antifreeze solutions, brake fluids, and household industrial products. The sweet taste and low cost of EG lead to its illicit use as an ethanol substitute. In cases of both accidental and purposeful ingestion, EG is rapidly absorbed from the gastrointestinal tract, and widely distributed throughout the body due to its miscibility with water. The first metabolic step is oxidation by alcohol and aldehyde dehydrogenases to the monoacid leading to the formation and accumulation of toxic metabolites causing metabolic acidosis. Urinary excretion as well as expiration as carbon dioxide represents the major pathway for elimination of the EG [3].

Ammonium chloride is commonly used as a buffer solution in a variety of chemical and medical applications and is also used as a fertilizer, in welding or smelting of metals, in cleansing agents, as food additives, also ammonium chloride is used as a diuretic. Ammonia may be present in drinking-water as a result of disinfection with chloramines. Also cement mortar used for the insides coating of water pipes may release considerable amounts of ammonia into drinking-water and compromise disinfection with chlorine [4].

The formation of stony concretions in body is known as lithiasis. Nephrolithiasis and urolithiasis are the main types of lithiasis that cause renal failure in human. It is the third most prevalent renal diseases affecting humans [5]. Urinary stone is a multi-factorial disorder resulted from association between epidemiological, biochemical and genetic risk factors. It occurs both in men and women but the risk is generally higher in men and is becoming more common in young women. Calcium oxalate contributes 75-90% of the total urinary stones [6].

Comment [H5]: Capitalize first letter

Comment [H6]: Please mention the details of improvements as to why do you think basil and celery helped to counteract renal failure

Comment [H7]: Sentence needs to be corrected

Comment [H8]: Insert 'by'

Nutritional causes of stone formation include inadequate drinking of water or drinking contaminated water with minerals and different chemicals, systematic dehydration, obesity, high dietary intake of minerals, sugars, corn syrups, vitamin C as well as vitamin A and deficiency of vitamin D. Other possible reasons include excess intake of alcohol and drugs, also may be attributed to obstruction in urine flow by microbial infections or foreign substances [7].

The medical techniques for urinary stones management includes extracorporeal shock wave lithotripsy and percutaneous nephrolithotomy. In addition to the high cost and the issues of recurrence, there are multiple side effects. Side effects include renal damage and impairment, induced hypertension, sever haematuria, steinstrasse (multiple small stone blocking ureter) and pancreatitis [8].

Comment [H9]: Full stop

On the other hand, there is a growing research to apply the use of herbal medicine in the treatment of urolithiasis. Herbal remedies are known to contain beneficial constituents, acting through several pathways, for example, antispasmodic, diuretic and pain relieving with no side effects associated with maximum benefits that needed for treating urolithiasis [9].

Sweet basil (*Ocimum basilicum*) is a herbal plant from *Lamiaceae* family and is known as Holy Basil in English and Rehan in Egypt. Basil leaves have been recognized as a food additive and spice but some evidence shows that these leaves can also be used to overcome different human diseases. This may be due to their phytochemical contents, including antioxidants, polyphenols and flavonoids. Essential oils as well as most the active constituents of basil is dominantly found in the leaves [10].

Celery (*Apium graveolens* L.) is a herbal plant, belonging to the parsley descent *Umbelliferae* family. Celery leaves have a variety of compounds like caffeic acid, p-coumaric acid, ferulic acid, apigenin, luteolin, tannin, saponin, and kaempferol. These compounds have powerful antioxidant characteristics, and able to chelate and fight free radicals that give celery varied healing characteristics [11].

Comment [H10]: Insert 'are'

In this study, I compare and examine for the first time the protective and healing effects of basil and/or celery aqueous extracts on the urinary stones and renal deteriorations induced by drinking water contaminated with ethylene glycol and ammonium chloride in male adult rats.

Comment [H11]: Write the sentence in indirect speech

2. MATERIALS AND METHODS

2.1. Materials

2.1.1. Chemicals

Ethylene glycol (EG) and ammonium chloride (AC) were purchased from Sigma Aldrich Chemical Co. (St. Louis, Missouri, United States). Urolithiasis model was induced using 0.75% EG and 1% AC dissolved in drinking water (distilled water) and the access to water was *ad libitum* [12].

2.1.2. Plants

Basil and celery were purchased from The Ministry of Agriculture, Giza, Egypt. Plant leaves were verified by botanist (Department of Botany, Faculty of Women for Arts, Science and Education, Ain shams University).

2.1.3. Diet

Experimental animals were fed on standard commercial diet according to [13] which obtained from The Egyptian Organization for Biological Products and Vaccines (Helwan, Egypt).

Comment [H12]: remove

2.1.4. Animals

fifty-five adult male albino rats of Sprague-Dawely strains weighing (185 ± 7 g), were supplied by The Egyptian Organization for Biological Products and Vaccines (Helwan, Egypt). All animal experimentations were carried out in conformity with the Committee for the Purpose of Control and Supervision of Experiments on Animals guidelines and were approved by the Institutional Animal Ethics Committee.

Comment [H13]: Capitalize

2.2. Methods

2.2.1. Preparation of Plants Aqueous Extracts

Basil and celery leaves were dried (40–60 °C) and the aqueous extracts were prepared by boiling dried plant leaves with distilled water for 15 min in a covered container [14]. The extracts were then filtered through a clean cotton cloth. The aqueous extracts were prepared and given to tested rats at dose of (100 mg and 200mg/kg body weight) [14, 15] via intra-gastric tube.

2.2.2. Measurement of Total Polyphenols and Total Flavonoids Contents of Aqueous Extracts

The amount of total polyphenols and total flavonoids contents in each plant aqueous extract were determined by folin-ciocalteu reagent as described by [16,17], respectively. The experiments were repeated in triplicate.

2.2.3. Experimental Design

All rats were individually housed with constant controlled environments in stainless steel cages and fed on the balanced commercial diet with drinking distilled water *ad libitum* for 7 days to be acclimatized. Animals classified randomly into 5 groups of ten animals each, except urolithiatic control group which contained 15 rats. Rats were treated as follow: Group I: healthy control group (HCG), rats drank distilled water and received a placebo 1 ml distilled water daily by intra-gastric tube ; Group II: urolithiatic control group(UCG) , rats drank distilled water containing (0.75% EG and 1% AC)and the access to water was *ad libitum* and received 1 ml distilled water daily by intra-gastric tube.; Group III : urolithiatic rats supplemented with aqueous basil extract(U+ABE), rats drank distilled water containing (0.75% EG and 1% AC) and the access to water was *ad libitum* and supplemented with (200mg/kg body weight) aqueous basil extract daily by intra-gastric tube.; Group IV: urolithiatic rats supplemented with aqueous celery extract(U+ACE), rats drank distilled water containing (0.75% EG and 1% AC) and the access to water was *ad libitum* and supplemented with (200mg/kg body weight) aqueous celery extract daily by intra-gastric tube. ; Group V: urolithiatic rats supplemented with aqueous basil and celery extract(U+ABE+ACE) , rats drank distilled water containing (0.75% EG and 1% AC) and the access to water was *ad libitum* and supplemented with (100mg/kg body weight) aqueous basil extract and (100mg/kg body weight) aqueous celery extract daily by intra-gastric tube.

Comment [H14]: were

2.2.4. Handling of Urine, Blood and Kidney Samples

At the end of the study (28) days, individual animal was placed in the metabolic cage for collection of 24 h urine samples. Initially a drop of concentrated hydrochloric acid was added to the test tubes as a preservative [18]. After urine collection period, rats were sacrificed under sodium barbiturate anesthesia. Blood samples were collected from the hepatic portal vein, serum was separated for biochemical analyses. Kidney samples were separated, rinsed, dried on filter paper, homogenized in Tris hydrochloride (Tris-HCl) buffer (pH 7.4) and centrifuged. The resulting supernatants were stored at -80°C immediately until doing the biochemical analysis.

Comment [H15]: remove bracket

2.2.5. Biochemical analysis

2.2.5.1. Urine Samples

Urine were tested for total volume in a measuring cylinder and reported in Milliliter (mL), pH of each sample was measured using pH meter [19]. Urinary oxalate, calcium, magnesium and phosphate concentration were determined using *Biodiagnostic kits, Giza, Egypt*.

Comment [H16]: samples

2.2.5.2. Serum Samples

Serum uric acid, urea and creatinine levels were determined according to [20-22] using *Biodiagnostic kits, Giza, Egypt*. Serum cystatin C was determined using ELISA assay technique according to the method described by *Pergande and Jung* [23]. Immunoglobulins G and M (IgG and IgM) concentrations were measured using *Biocientifica kit, San Diego, USA*.

2.2.5.3. Kidney Samples

Renal complex I activity, malondialdehyde (MDA), reduced glutathione (GSH) levels and superoxidedismutase (SOD) activity were determined according to [24-27]. Renal oxalate, calcium, magnesium and phosphate levels as well as renal acidic phosphatase (ACP), alkaline phosphatase (ALP), Alanine aminotransferase (ALT), aspartate aminotransferase (AST) activities were determined using *Biodiagnostic kits, Giza, Egypt*. Renal lactate dehydrogenase (LDH) activity was determined according to standard methods using diagnostic kits from BioSystems S.A. (Barcelona, Spain), caspase-3 was determined following ELISA MyBioSource kit standard method. Tumor necrosis factor alpha (TNF- α) as well as interleukin eighteen (IL-18) levels were determined using Koma Biotech and MyBioSource ELISA kits according to [28,29].

2.2.6. Weight of Calculi

The urinary bladders and ureters were opened by incision. The adhered crystals were removed and weighed using digital balance [30].

2.2.7. Statistical Analysis

Results were expressed as mean \pm Standard deviation (S.D) of the mean. Differences among means were tested for statistical significance by one-way analysis of variance using SPSS package version 20. Statistical significance was considered when $P \leq 0.01$ according to [31].

3. RESULTS AND DISCUSSION

3.1. Aqueous basil and celery extracts total flavonoids and total polyphenols contents

Flavonoids and phenolic compounds are the main medicinal plants active constituents. The analysis of aqueous basil extract (ABE) and aqueous celery extract (ACE) as illustrated in figure (1) revealed that both plants extracts contain valuable amount of flavonoids and polyphenols in comparison with their price. The aqueous basil extract contained (2.59mg flavonoids/100mg extract) and (4.86 mg polyphenols/100mg extract) while the aqueous celery extract contained (1.87 59mg flavonoids/100mg extract) and (3.95 mg polyphenols/100mg extract).

Comment [H17]: Fig

Flavonoids possess antioxidant power by efficiently scavenging various free radicals. Flavonoids act through modulating antioxidant enzymes activities as well as catching metals accompanied with processes of radical production [32]. While phenolic compounds are the main secondary metabolites in plants. Phenolics have antioxidant associated with anti-inflammatory capability. Also phenolics can regulate enzyme activity and gene expression [33].

The results go hand in hand with [34,35] who confirmed that basil and celery and their aqueous extract contain significant amount of phytochemicals including flavonoids and polyphenols .

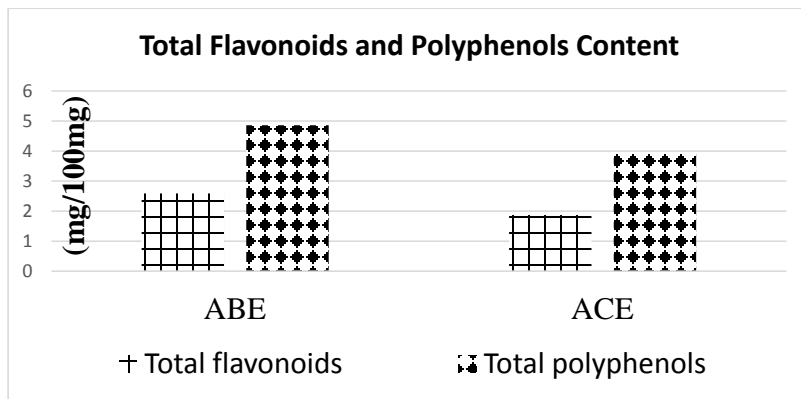


Fig (1): Aqueous basil and celery extracts total flavonoids and total polyphenols contents

3.2. Effect of aqueous basil and/or celery leaves extracts on urine volume, pH, urinary and renal oxalate, calcium, magnesium and phosphate levels in urolithiatic rats

The results in Fig 2(a, b and c) and table (1) revealed that rats drank on water contaminated with ethylene glycol (EG) in association with ammonium chloride (AC) for 28 days to induce urolithiasis, urinated less and their urine and renal oxalate, calcium, and phosphate levels increased significantly ($p \leq 0.01$) on comparison with healthy control rats that drank pure clean distilled water on the other hand water contamination decreased urine pH , urine as well as renal magnesium level significantly ($p \leq 0.01$). Supplementation with aqueous basil and /or celery extracts improved significantly ($p \leq 0.01$) the urine volume, pH, urinary and renal oxalate, calcium, magnesium and phosphate levels in urolithiatic rats in comparison with urolithiatic control rats.

Comment [H18]: Table

Urinary super saturation is one of the main causative factors in calculogenesis with respect to stone-forming constituents. Fourteen days continued administration of ethylene glycol (EG) to young albino rats led the formation of renal calculi composed mainly of calcium oxalate [36]. Also it resulted in increase in urine and renal concentration of oxalate as well as phosphate stones. Administration of 0.75% (v/v) EG solution caused formation of toxic metabolites inside the body resulting in metabolic acidosis due to the accumulation of acid metabolite and lactate. Renal calcium oxalate deposition by EG and ammonium chloride in rats is mainly used to mimic the urinary stone formation in humans. Ammonium chloride reported to accelerate the lithiasis [37]. The stones induced obstruction of urine flow leading to decreased urine output and urine volume in urolithiatic rats. EG and AC administration results in decreased urine pH as acidity encourages salts precipitation and crystallization. Also the most components of kidney stones are inorganic materials, with a small percentage of organic material; 90% of the inorganic components are calcium, oxalate and phosphate. While magnesium is one of the inhibitors of crystallization, as encountered in EG and AC induced urolithiasis, and it decreases the super saturation of stony formation resulting in reduced crystal growth [6, 30, 38].

Aqueous basil and celery extracts significantly improved the urine volume that decreased the crystal formation rate as well as facilitated the flushing out of crystals and raised urine pH that prevented the stone formation by preventing salt precipitation. Supplementation also decreased urinary and renal calcium, oxalate and phosphate levels while increased

magnesium levels that decreased stony formation. The best effects were seen in the group that supplemented with both basil and celery aqueous extracts.

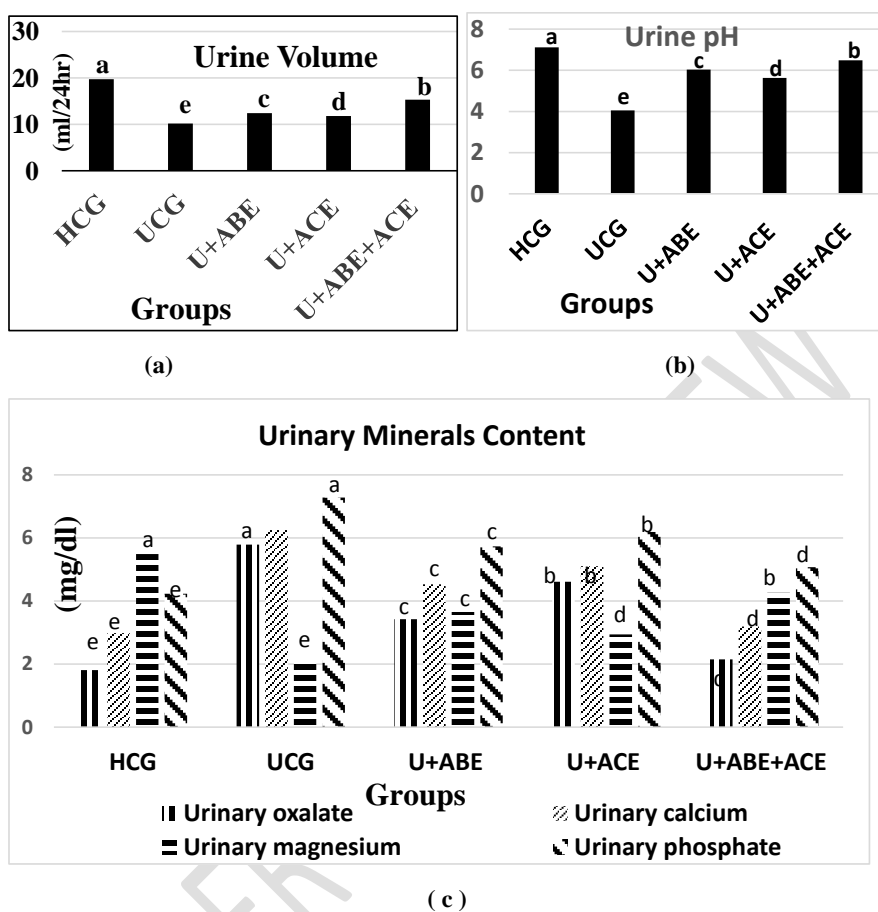


Figure (2): Effect of aqueous basil and/or celery leaves extracts on (a)urine volume (ml/24hr), (b)urine pH and (c) urinary oxalate, calcium, magnesium and phosphate levels (mg/dl) in urolithiatic rats. Values are expressed as means \pm S. D, n=10. Column of histogram with different letters are significantly different at ($p \leq 0.01$).

Comment [H19]: redraw

Table (1): Effect of aqueous basil and/or celery leaves extracts on renal oxalate, calcium, magnesium and phosphate levels in urolithiatic rats

Parameter Group	Renal oxalate (mg/g)	Renal calcium (mg/g)	Renal magnesium (mg/g)	Renal phosphate (mg/g)
Healthy control group	1.44 \pm 0.19 ^c	2.48 \pm 0.09 ^c	6.92 \pm 2.03 ^a	2.07 \pm 0.18 ^c
Urolithiatic control group	6.53 \pm 1.34 ^a	5.77 \pm 0.79 ^a	2.84 \pm 0.41 ^c	4.78 \pm 0.83 ^a
Urolithiatic rats supplemented with	3.84 \pm 0.62 ^c	3.89 \pm 0.51 ^c	4.14 \pm 0.93 ^c	3.19 \pm 0.45 ^c

aqueous basil extract				
Urolithiatic rats supplemented with aqueous celery extract	5.13±0.84 ^b	4.53±0.18 ^b	3.65±0.60 ^d	4.02±0.53 ^b
Urolithiatic rats supplemented with aqueous basil and celery extract	2.32±0.71 ^d	3.12±0.31 ^d	5.26±1.01 ^b	2.64±0.06 ^d

Values are expressed as means ±S.D, n=10.

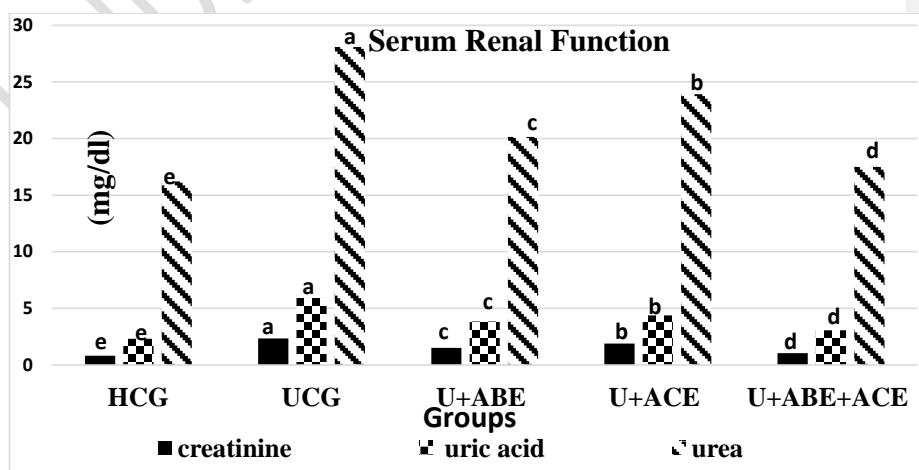
There was no significant difference between means have the same alphabetical superscripts letter in the same column. ($p \leq 0.01$).

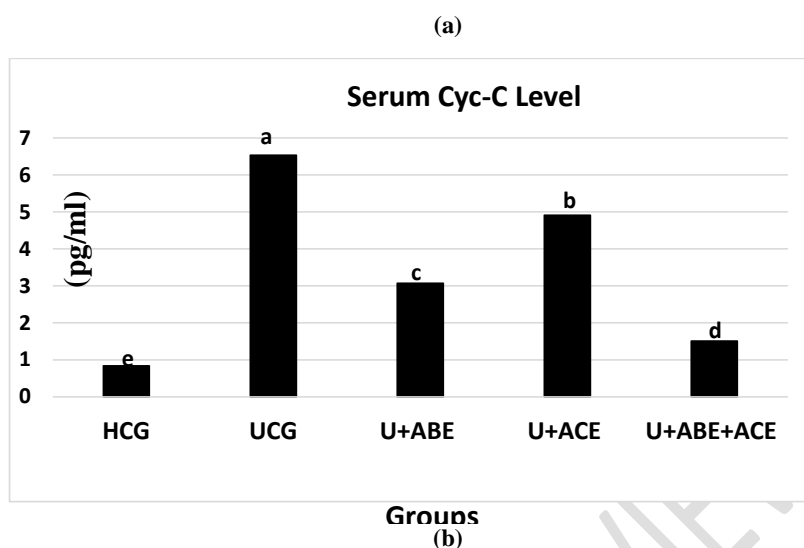
3.3. Impact of aqueous basil and/or celery leaves extracts on serum creatinine, uric acid, urea and Cyc-C levels in urolithiatic rats

As a result of increased mineral precipitation leading to formation of urinary and kidney crystals and stones that causes obstruction of urinary tract and retention in renal tubules leading to renal tissues damage, decreasing the glomerular filtration rate and facilitating accumulation of different waste products especially nitrogenous substances in blood [38-40]. Figure 3 (a and b) illustrated that administration of EG and AC resulted in increased serum level and accumulation of nitrogenous waste products like creatinine, uric acid and urea, associated with increased serum cystatin C (Cyc-C) level significantly ($p \leq 0.01$). Cys-C is a preliminary marker of renal deterioration compared to familiar markers as creatinine and can reveal mild to moderate kidney problems. Cyc-C is a produced non-glycosylated protein present in all nucleated cells and is refined by glomeruli and then metabolized in proximal renal tubule cells. Cys-C is the fundamental protector of the glomerular membrane from destruction by cysteine proteinases. The impaired renal tissue is indicated by decreased glomerular filtration rate and identified by the raised serum cystatin C [41].

Basil and celery extract supplementation to urolithiatic rats, counteracted kidney tissues deteriorations and improved kidney function as well as glomerular filtration rate significantly ($p \leq 0.01$) in all treated groups especially that group that supplemented with both extracts as basil and celery active constituents prevented salts precipitation and increased urine flow that maintained normal kidney functions.

Comment [H20]: Fig





Figure(3): Impact of aqueous basil and/or celery leaves extracts on (a) serum renal function(creatinine, uric acid and urea) and (b) Cyc-C levels in urolithiatic rats. Values are expressed as means \pm S. D, n=10. Column of histogram with different letters are significantly different at ($p \leq 0.01$).

Comment [H21]: redraw in higher resolution and name it Fig 3

3.4. Effect of aqueous basil and/or celery leaves extracts on renal ACP, ALP, ALT,AST and LDH activities in urolithiatic rats

The present research results (table 2) revealed that EG and AC administration to rats induced a significant ($p \leq 0.01$) renal deterioration associated with kidney tissues degeneration resulting in increased enzymes activities of ACP, ALP, ALT and AST in renal homogenates of urolithiatic control group accompanied by decreased LDH activity when compared to healthy control group. The alterations in these injury marker enzymes in urolithiatic control group suggested damage to the brush border membrane of the renal tubules associated with progressive damage in the membrane integrity, which appears to associate with the retention and deposition of crystals in the kidney [40,42, 43]. On the other hand administration of basil and /or celery extracts normalized these enzymes activities by preventing crystals deposition and maintaining kidney integrity and functions

Comment [H22]: τ

Table(2):Effect of aqueous basil and/or celery leaves extracts on renal ACP, ALP, ALT,AST and LDH activities in urolithiatic rats

Parameter Group	ACP (U/L)	ALP (U/L)	ALT (U/L)	AST (U/L)	LDH (U/L)
Healthy control group	0.64 \pm 0.04 ^c	10.48 \pm 1.33 ^c	32.10 \pm 1.67 ^c	59.19 \pm 3.01 ^c	6.02 \pm 0.38 ^a
Urolithiatic control group	2.38 \pm 0.41 ^a	27.84 \pm 3.56 ^a	66.93 \pm 5.83 ^a	87.42 \pm 6.829 ^a	2.30 \pm 0.16 ^c

Urolithiatic rats supplemented with aqueous basil extract	1.37±0.16 ^c	20.50±1.05 ^c	48.96±2.30 ^c	69.37±2.15 ^c	4.23±0.18 ^c
Urolithiatic rats supplemented with aqueous celery extract	1.82±0.32 ^b	23.37±1.21 ^b	54.07±1.24 ^b	73.25±4.08 ^b	3.10±0.20 ^d
Urolithiatic rats supplemented with aqueous basil and celery extract	0.91±0.08 ^d	18.42±0.95 ^d	43.38±1.08 ^d	60.04±2.05 ^d	5.81±0.69 ^b

Values are expressed as means ±S.D, n=10.

There was no significant difference between means have the same alphabetical superscripts letter in the same column. ($p \leq 0.01$).

3.5. Impact of aqueous basil and/or celery leaves aqueous extracts on renal mitochondrial function, apoptosis and oxidative status in urolithiatic rats

Mitochondrial function is essential to regulate energy production and redox signaling in healthy well acting cells. Kidney stone disease were found to impair renal mitochondrial functions as indicated by decreased complex I activity in urolithiatic control group significantly ($p \leq 0.01$). Complex I (NADH: ubiquinone oxidoreductase) has many important functions including; help in movement of protons across the inner mitochondrial membrane that promote ATP production for mitochondrial and cell function as well as movement of solute across the membrane [40,44].

Increased caspase-3 activity (an important mediator of programmed cell death), progressing to apoptosis was recorded in urolithiatic rats and were stated previously leading to the mitochondrial apoptotic pathway activation in the kidney tissue during forming stone [45,46]. On the contrary, supplementation with plants extracts reversed back the caspase-3 activity indicating the potential inhibitory role of basil and /or celery against programmed cell death.

Free radicals generation and oxidative stress was induced as indicated in table (3) by increased renal MDA level associated with decreased GSH level and SOD activity. Oxidative stress influenced complex I activity and it is probably the most susceptible component of the electron transport chain. Patients with kidney stones were found to have less activity of antioxidant enzyme with increased lipid peroxidation [47-49]. Increased activities of complex I and SOD as well as GSH level associated with decreased MDA level and caspase-3 activity in the kidney of animals administered basil and /or celery aqueous extracts could be attributed to the polyphenols and flavonoids contents that give an antioxidant potential of the extracts as seen in the current study.

Comment [H23]: T

Table (3): Impact of aqueous basil and/or celery leaves extracts on renal mitochondrial function , apoptosis and oxidative status in urolithiatic rats

Parameter Group	Complex 1 ($\mu\text{mol NADH}$ oxidized/min/mg)	Caspase-3 (ng/mg)	MDA ($\mu\text{mol/g}$)	SOD (U/g)	GSH (mg/g)
Healthy control group	1.04±0.12 ^a	3.17±0.21 ^c	0.58±0.03 ^c	6.08±1.82 ^a	9.85±2.04 ^a
Urolithiatic control	0.37±0.03 ^c	10.95±1.84 ^a	4.69±0.73 ^a	2.70±0.23 ^c	5.04±1.14 ^c

group					
Urolithiatic rats supplemented with aqueous basil extract	0.63±0.04 ^c	7.36±0.87 ^c	1.94±0.18 ^c	4.63±0.75 ^c	6.93±0.82 ^c
Urolithiatic rats supplemented with aqueous celery extract	0.49±0.05 ^d	9.08±1.23 ^b	3.21±0.28 ^b	3.29±0.59 ^d	6.07±0.36 ^d
Urolithiatic rats supplemented with aqueous basil and celery extract	0.81±0.07 ^b	4.70±0.52 ^d	1.17±0.09 ^d	5.72±1.19 ^b	7.89±1.53 ^b

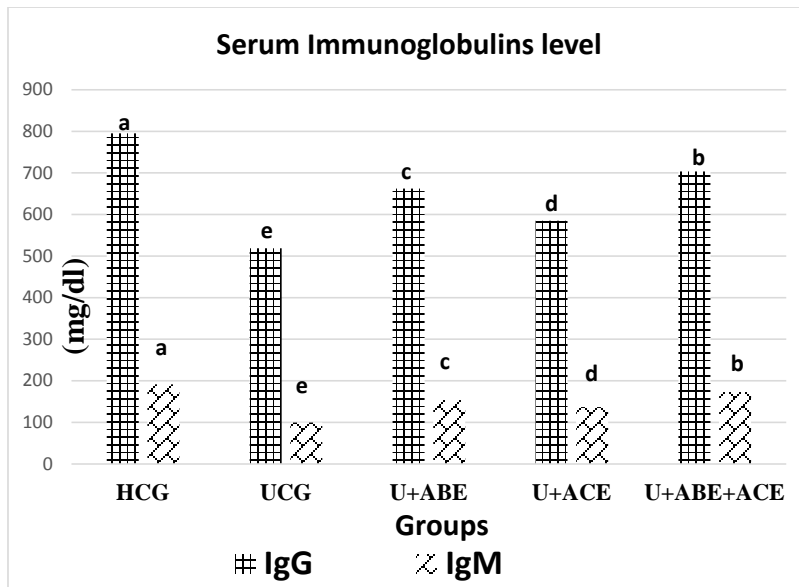
Values are expressed as means ±S.D, n=10.

There was no significant difference between means have the same alphabetical superscripts letter in the same column. ($p \leq 0.01$).

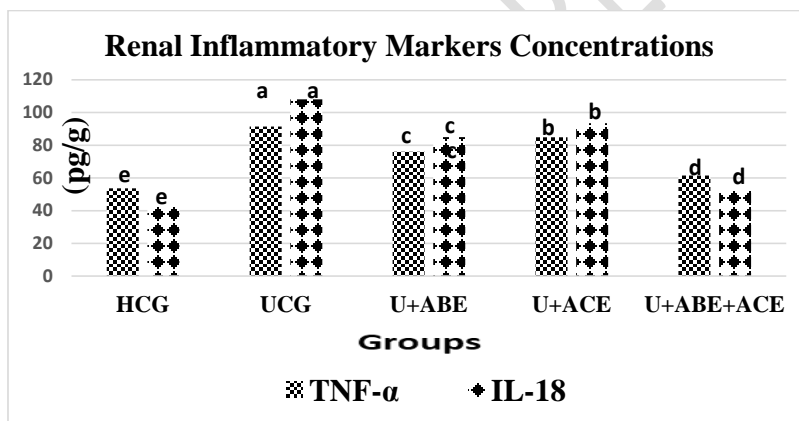
3.6. Effect of aqueous basil and/or celery leaves extracts on serum IgG, IgM and renal TNF- α and IL-18 levels in urolithiatic rats

The results tabulated in figure 4 (a and b) magnified that EG and AC water contamination inducing urolithiatic rat model caused suppression of immune system ability to fight infection by decreased serum levels of immunoglobulins G and M significantly ($p \leq 0.01$) in urolithiatic control rats in comparison with healthy control rats and that was associated with significant renal inflammation impressed in high concentration of TNF- α and IL-18 in renal tissues of urolithiatic control rats. Urolithiasis caused a state of oxidative stress that suppress B cells functions leading to suppressed immune function associated with decreased IgG and IgM levels. Oxidative stress also initiate inflammatory cascades leading to increased inflammatory markers expression especially at kidney tissues [49]. Pro-inflammatory cytokines are released at the onset of the inflammation and they initiate the release of other cytokines and activate inflammatory cells. They are essential to the initiation and sustenance of immune response. Main pro-inflammatory cytokine in human immune response is TNF- α . IL-18 as an early diagnostic biomarker of acute renal damage and increased expression of IL-18 was associated with renal damage [50,51]. Aqueous basil and/or celery extracts active constituents fight oxidants, ameliorated oxidative stress and were found to be able to suppress inflammatory cascades and strengthen immune system and its ability to fight microbes in urolithiatic rats.

Comment [H24]: Fig



(a)



(b)

Figure(4):Effect of aqueous basil and/or celery leaves extracts on (a)serum IgG, IgM and (b) renal TNF- α and IL-1 β levels in urolithiatic rats. Values are expressed as means \pm S. D, n=10. Column of histogram with different letters are significantly different at ($p \leq 0.01$).

Comment [H25]: Fig

3.7. Impact of aqueous basil and/or celery leaves extracts on urinary calculi weight

Rats that were drunk water contaminated with EG and AC caused precipitation of minerals in the urinary bladder and ureters forming urinary calculi. Results tabulated in table (4) showed that formation of urinary calculi in urolithiatic control group and supplementation with aqueous basil and /or celery extracts prevented and decreased mineral precipitation and formation of the calculi and urolithiatic rats that supplemented with both aqueous extracts had

Comment [H26]: T

the least calculi formation and weight due to the synergetic effect between basil and celery active constituents.

Table (4):Impact of aqueous basil and/or celery leaves extracts on renal calculi weight

Parameter Group	Calculi weight (g)
Healthy control group	-
Urolithiatic control group	1.12±0.23
Urolithiatic rats supplemented with aqueous basil extract	0.56±0.12
Urolithiatic rats supplemented with aqueous celery extract	0.84±0.09
Urolithiatic rats supplemented with aqueous basil and celery extract	0.23±0.02

Values are expressed as means ±S.D, n=10.

4. CONCLUSION

From this research results, it can be concluded that both aqueous basil and celery extracts have high content of flavonoids and polyphenols that compete with and prevent serious and dangerous effects resulted from drinking water contaminated with EG and AC for 28 days. Aqueous extracts maintained and improved renal health. The most significant improvements were recorded in the group that supplemented with both extracts. It is advised to drink basil and celery tea and adding their leaves to soups, food recipes and salads due to their health benefits, low cost and ease of availability all the year.

ETHICAL APPROVAL

This research was done following "Principles of laboratory animal care" (NIH publication No. 8523, revised 1985), as well as specific national laws. All experiments have been examined and approved by the appropriate ethics committee.

REFERENCES

- 1-Sharma S. and Bhattacharya A. Drinking water contamination and treatment techniques Applied Water Science.2017 ; 7(1): 1043–1067]
- 2-Kumar A. and Xagorarakis I. Pharmaceuticals, personal care products and endocrine-disrupting chemicals in U.S. surface and finished drinking waters: a proposed ranking system. Science of the Total Environment.2010; 408 (23):5972-89.
- 3-Loriaux D, Bergin S P and Patel S M.Ethylene glycol toxicity in the setting of recurrent ingestion: A Case Report and Literature Review. Cureus. 2019 ;11(4): 4375.

- 4- Kharicha SM , Kharicha A, Mogeritsch J, Wu M and Ludwig A. Review of ammonium chloride–water solution properties *J. Chem. Eng. Data* .2018; 63(9): 3170–3183
- 5-Lonkala S. In-vitro anti-urolithiatic evaluation of tamsulosin against urolithiasis induced in wistar albino rats. *J Forensic Sci Toxicol*. 2020; 3(1): 1011.
- 6-Kifayatullah M., Rahim H, Jan N U, Abbas A, Khan MS and Ikram M .Anti-urolithiatic effect of *Pericampylus glaucus* against ethylene glycol induced urolithiasis in male sprague dawley rats. *Sains Malaysiana*.2019; 48(5): 1075–1081
- 7-Goyal PK, Verma S K and Sharma A K. Evaluation of antiurolithiatic effects of *Parmelia perlata* against calcium oxalate calculi in hyperoxaluric rats. *Journal of Applied Pharmaceutical Science* .2018; 8 (01): 129-135
- 8-Li X, Wang W, Su Y, Yue Z, Bao J. Inhibitory effect of an aqueous extract of *Radix Paeoniae Alba* on calcium oxalate nephrolithiasis in a rat model. *Renal Failure*. 2017; 39(1) 120-129.
- 9-Ushakiran CH, MURTHY PPA, Lakshmi P S, Mounika V, Mani J , Yothi N and Anitha P .Evaluation and antiurolithiatic activity of rapanus sativus extract by *in-vivo* on experimentally induced urolithiasis in rats . *International journal of pharmacy and pharmaceutical analysis* .2017; 1(2) :71- 78.
- 10- Rachmawati NA, Wasita B and Kartikasari LR. Basil leaves (*Ocimum sanctum linn.*) extract decreases total cholesterol levels in hypercholesterolemia sprague dawley rats model .*IOP Conf. Series: Materials Science and Engineering*.2019; 546 (6): 1-6.
- 11- Kooti W and Daraei N.A Review of the Antioxidant Activity of Celery (*Apium graveolens L.*).*Journal of Evidence-Based Complementary & Alternative Medicine*. 2017; 22(4): 1029-1034.
- 12-Fan J, Glass MA and Chandhoke PS. Impact of ammonium chloride administration on a rat ethylene glycol urolithiasis model .*Scanning Microscopy*.1999; 13(2-3): 299-306.
- 13-(NRC), National Research Council. Nutrient requirements of laboratory animals 4th ed. 1995.National Academy Press, Washington, DC.
- 14- Farag MFS. Utilization of basil extract as a radioprotector in male rats .*Arab Journal of Nuclear Science and Applications*.2013; 46(1): 274-281.
- 15-Hardani A, Afzalzadeh MR, Amirzargar A, Mansouri E, Meamar Z. Effects of aqueous extract of celery (*Apium graveolens L.*) leaves on spermatogenesis in healthy male rats. *Avicenna J Phytomed*. 2015; 5 (2): 111
- 16-Arnous A, Makrisand DP and Kefalas P. Effect of principal polyphenol components in relation to antioxidant characteristics of aged red wines. *J. Agric. Food Chem*.2001; 49: 5736.
- 17-Joyeux M, Lobestein A, Anton R, and Morier F. Comparative anti- lipoperoxidant, anti-necrotic and scavenging potencies of terpenes and bio-flavones from ginkgo and some flavonoids. *Planta Med*.1995; 61: 126-29.
- 18-Mariappan A, Ganapathy G and Banumathi V. Anti-urolithiatic evaluation of siddha formulation seenakara parpam against zinc disc implantation induced urolithiasis in wistar albino rats. *Int J Adv Res Biol Sci*. 2016;3(12):7-13.

- 19-Bhave AL, Bhatt JD, Hemavathi KG. Antiulcer effect of amlodipine and its interaction with H₂blocker and proton pump inhibitor in pylorus ligated rats. *Indian J Pharmacol.* 2006;38(6):403-7.
- 20-Fossati P, Prencipe L, Berti G. Use of 3, 5- dichloro-2-hydroxybenzenesulfonicacid/4-aminophenazone chromogenic system in direct enzymic assay of uric acid in serum and urine. *Clinical Chemistry.* 1980;26: 227-231.
- 21-Kaplan A. Urea, Kaplan A, et al. *Clin Chem The CV Mosby Co St Louis. Toronto. Princeton.* 1984;33:1257-1260.
- 22- Murray RL. Creatinine, Kaplan A, et al. *Clin Chem the C.V. Mosby Co, St Louis, Toronto, Princeton.* 1984;32:1261–1266.
- 23- Pergande M, Jung K. Sandwich enzyme immunoassay of cystatin C in serum with commercially available antibodies. *Clinical Chemistry.* 1993;39(9):1885- 1890.
- 24-Draper HH and Hadley M. Malondialdehyde determination as index of lipid peroxidation. *Meth. in Enzymol.*1990;186:421-31.
- 25-Beutler E, Duroun O, Kelly BM. Improved method for the determination of blood glutathione. *J Lab Clin Med.* 1963;61: 882-8.
- 26-Nishikimi M., Roa N.A. and Yogi K. The occurrence of superoxide anion in the reaction of reduced phenazine methosulphate and molecular oxygen. *J.Biochem. Biophys. Res. Commun.* 1972; 46:849- 853.
- 27-Birch-Machin MA and Turnbull DM .Assaying mitochondrial respiratory complex activity in mitochondria isolated from human cells and tissues. *Methods Cell Biol.*2001; 65:97–117.
- 28-Dowlati Y, Herrmann N, Swardfager W, Liu H, Sham L, Reim EK and Lanctôt KL. A meta- analysis of cytokines in major depression. *Biological Psychiatry.* 2010; 67:446–457.
29. Zhong F, Xu J, Yang X, Zhang Q, Gao Z, Deng Y, Zhang L and Yu C. miR-145 eliminates lipopolysaccharides-induced inflammatory injury in human fibroblast-like synovocyte MH7A cells. *J Cell Biochem .*2018;119:10059-10066.
- 30-Lonkala S. In-Vitro Anti-urolithiatic evaluation of tamsulosin against Urolithiasis induced in wistar albino rats. *J Forensic Sci Toxicol.* 2020; 3(1): 1011.
- 31-Levesque R. SPSS programming and data management: A guide for SPSS and SAS users. 4th ed. SPSS Inc, Chicago, IL; 2007.
- 32-Sebastian MRA and George AM. Evaluation of tocolytic activity of aqueous seed extract of *Syzygium Cumini* on oxytocin induced preterm labor . *Asian J of Pharma and Clinl Res.*2020; 13Suppl 5: 162-70.
- 33-Mojzer EB, Hrnčič MK, Škerge M, Knez Z, Bren U. Polyphenols: extraction methods, antioxidative action, bioavail- ability and anticarcinogenic effects. *Molecules.* 2016;21(901):1- 38.
- 34- Taie HAA, Salama ZA, Radwan S. Potential activity of basil plant as a source of antioxidants and anticancer agents as affected by organic and bio-organic fertilization *Not. Bot. Hort. Agrobot. Cluj .*2010;38 (1) : 119-127

- 35- Siska S, Abdul Mun'im , Bahtiar A and Suyatna F D.Effect of *Apium graveolens* Extract Administration on the Pharmacokinetics of Captopril in the Plasma of Rats .*Sci. Pharm.* 2018; 86: 6.
- 36-Tzou, DT, Taguchi K, Chi T and Stoller ML. Animal models of urinary stone disease. *International Journal of Surgery.*2016; 36: 596-606.
- 37- Atmani F, Slimani Y, Mimouni M and Hacht B, Prophylaxis of calcium oxalate stones by *Herniaria hirsute* on experimentally induced nephrolithiasis in rats, *BJU Int.*2003 ;92 : 137–140.
- 38- Goyal PK, Verma SK and Sharma AK .Evaluation of antiurolithiatic effects of *Parmelia perlata* against calcium oxalate calculi in hyperoxaluric rats .*Journal of Applied Pharmaceutical Science.*2018; 8 (01): 129-135.
- 39-Salama A.A. ,El-Kassaby M I.and Hassan A. Anti-urolithiatic activity of *Solanum nigrum* hydroalcoholic extract in ethylene glycol-induced urolithiasis in rats .*Egyptian Pharmaceutical Journal.* 2019;18:311–319
- 40- Olayeriju O S, Crown O O , Elekofehinti O O, Akinmoladun AC, Olaleye MT and Akindahunsi A A. Effect of moonseed vine (*Triclisia gillettii* Staner) on ethane-1,2-diol-induced urolithiasis and its renotoxicity in Wistar albino rats. *Afr J Urol.*(2020) ;26:4
- 41-Tousson E, Keshta ATH, Hussein Y, Fekry RM, Abo-Ghaneima WK. Renal protective effect of *Ginkgo biloba* and l-carnitine extracts against pentylenetetrazol induced toxicity, oxidative stress, injury and proliferation alternation in epileptic rats. *Annual Research & Review in Biology.* 2019;32(2):1-13.
- 42- Baheti D G and Kadam S S. Antiurolithiatic activity of a polyherbal formulation against calcium oxalate induced urolithiasis in rats *Journal of Advanced Pharmacy Education & Research.* 2013 ;3 (1):31-41.
- 43-Sudhahar V, Veena CK, Varalakshmi P. Antiurolithic effect of lupeol and lupeol linoleate in experimental hyperoxaluria. *J Nat Prod.*2008; 71(9):1509–1512
- 44-Taylor ER, Hurrell F, Shannon RJ, Lin TK, Hirst J, Murphy MP.Reversible glutathionylation of complex I increases mitochondrial superoxide formation. *J Biol Chem.*2003;278(22):19603–19610
- 45-Zhai W, Zheng J, Yao X, Peng B, Liu M, Huang J, Wang G, Xu Y. Catechin prevents the calcium oxalate monohydrate induced renal calcium crystallization in NRK-52E cells and the ethylene glycol induced renal stone formation in rat. *BMC Complement Altern Med.* 2013; 13: 228.
- 46-Keleş R, Şen A, Ertaş B, Kayalı D, Eker P, Şener TE, Doğan A, Çetinel Ş, Şener G. The effects of *Urtica dioica* L. ethanolic extract against urinary calculi in rats. *J Res Pharm.* 2020; 24(2): 205-217.
- 47-Divakar K, Pawar AT, Chandrasekhar SB, Dighe SB, Divakar G. Protective effect of the hydro-alcoholic extract of *Rubia cordifolia* roots against ethylene glycol induced urolithiasis in rats. *Food Chem Toxicol.*2010;48(4):1013–1018

48-Patel PK, Patel MA, Saralai MG, Gandhi TR. Antiurolithiatic effects of solanum xanthocarpum fruit extract on ethylene-glycol-induced nephrolithiasis in Rats. *J Young Pharm.* 2012; 4(3): 164–170.

49- Aslan Z and Aksoy L. Anti-inflammatory effects of royal jelly on ethylene glycol induced renal inflammation in *Int Braz J urol.* 2015; 41: 1008-1013

50-Parikh CR, Mishra J, Thiessen-Philbrook H, Dursun B, Ma Q and Kelly C. Urinary IL-18 is an early predictive biomarker of acute kidney injury after cardiac surgery. *Kidney Int.* 2006;70:199-203.

51- Faubel S, Lewis EC, Reznikov L, Ljubanovic D, Hoke TS and Somerset H. Cisplatin-induced acute renal failure is associated with an increase in the cytokines interleukin (IL)1beta, IL-18, IL-6, and neutrophil infiltration in the kidney. *J Pharmacol Exp Ther.* 2007;322:8-15.

UNDER PEER REVIEW