

Case study

A rare case of recurrent Blastomycosis in North America

Comment [N1]: Check whether e or i

Abstract

Blastomycosis is a chronic granulomatous and suppurative mycoses caused by *Blastomyces dermatitidis*. The majority of cases show a primary pulmonary disease. We report a 65-year-old male patient with two painless, violaceous skin lesions over the left chest wall and right inner thigh. Initially, differential diagnoses of disseminated Blastomycosis, Pneumonia, and Diffuse large B-cell lymphoma made based on past and present clinical history and presentation. The final diagnosis of disseminated with secondary cutaneous Blastomycosis in a followup case of Diffuse large B-cell lymphoma made based on skin biopsy, broncho-alveolar lavage, and bronchial brushing showing budding yeasts of *Blastomyces*. The patient responded well to therapy with Amphotericin B and Itraconazole along with intravenous methylprednisolone.

Comment [N2]: What it indicates is it disease

Comment [N3]: And also

Comment [N4]: Not clear what the author conclude?

Introduction

Blastomycosis is a rare systemic pyogranulomatous infection caused by thermally dimorphic fungus *Blastomyces dermatitidis* (1, 2). Gilchrist first reported it in the year 1894 (3). It first involves the lungs due to inhalation of the conidia of this organism (1). It can spread hematogenously to any organ but commonly spread to the skin, bones, and the urogenital system (1). Blastomycosis of lungs can present as asymptomatic infection or acute or chronic Pneumonia (4). Skin lesions are a result of primary pulmonary disease, which spreads lympho-hematogenously to involve the skin (5). The primary pulmonary infection is subclinical in up to 50% of patients in secondary cutaneous Blastomycosis (5). Cases of Primary cutaneous Blastomycosis are uncommon (6).

Comment [N5]: Check the citation

Many blastomycosis cases have been present in North America (7). The southeastern and south-central states bordering the Mississippi and Ohio river basins, the Canadian provinces bordering the Great Lakes, the midwestern states, New York and Canada area along the St. Lawrence River are all endemic of Blastomycosis (1,7). It is also reported sporadically in Nigeria, Tunisia, Zimbabwe, Israel, Lebanon, India, and Saudi Arabia (1).

This case report describes disseminated Blastomycosis with the cutaneous presentation in a follow-up case of diffuse large B-cell lymphoma in an old male patient.

Case report

A 65-year-old male presented in the emergency department with progressive fatigue for the last month. The patient also had a fever, chills, and night sweats. On examination, two painless, violaceous skin lesions over the left chest wall and right inner thigh were noted (Figure 1). The rest of the physical examination was within normal limits. The patient also complained of dysuria, hesitancy, and urinary obstruction for three days with no history of cough, chest pain, and shortness of breath. In 2006, the patient diagnosed with diffuse large B-cell lymphoma. The patient treated with chemotherapy and radiation, currently in remission. The patient had hypogammaglobulinemia (receiving intravenous immunoglobulins for six weeks, last treatment 9/05/19). The patient had long QT interval. In family history, father died from sudden cardiac death at 76 years of age. Mother has breast carcinoma. Sister has rheumatoid arthritis.

Laboratory and radiological findings are shown below in the table (Table 1);

Table 1: Laboratory and radiological findings

Parameters	Results(9/29)	Units	Comments	Results(10/7)	Comments
Hemogram					
Hemoglobin	11.8		Low	12.6	
RBC count	4.58				

Hematocrit	35.6		Low		
MCV	77.8		Low		
MCH	25.8		Low		
MCHC	33.1				
RDW	14.5				
WBC count	8.6			6.7	
Neutrophils	83		High		
Lymphocytes	7				
Monocytes	8				
Eosinophils	1				
Basophils	1				
Platelets	293			352	
Chemistry analysis					
Total protein	5.8		Low		
Albumin	3.2		Low		
Total Bilirubin	0.6				
AST	16				
ALT	11				
ALP	121		High		
Urea	13				
Creatinine	1				
Calcium	7.9		Low		
Na	133				
K	3.7				
Cl	99				
Glucose	116		High		
e-GFR	75				
BNP				130	High
CRP	21.7		High	29.8	High

Procalcitonin	0.27		High	1.17	High
Urine analysis					
Colour	Yellow				
Turbidity	Cloudy		Abnormal		
SG	1.024				
pH	6.5				
Protein	100		Abnormal		
Glucose	Negative				
Bilirubin	Negative				
Ketones	Negative				
Blood	2		Abnormal		
Urobilinogen	Normal				
Ester	3		Abnormal		
Nitrate	Negative				
Hyaline	0-2				
Epithelial	Negative				
WBC	51-100		Abnormal		
RBC	21-50				
Epithelial cells	Negative				
Squamous cells	Negative				
Mucous	Negative				
Amorphous	1				
Granular cast	Negative				
Crystals	Negative				
CXR (Figure 2 and 3)	New Right hilar prominence with posterior midlung opacification Left base shows small patchy nodular opacities.				

CT scan Chest, abdomen and pelvis(Figure 4)	Bulky diffuse adenopathy Broad area of consolidation in superior right lower lobe- largest area being 7.9x5.5 cm Diffuse septal thickenings Groundglass opacities throughout both lungs				
Blastomycosis antigen, Serum	0.66		Positive		
Blastomycosis antigen, Urine	6.80		Positive		
Blood Culture	No growth				
Punch Biopsy, skin lesions (9/30) (Figure 5)	Medium sized spore forms and possible broad budding yeast of Blastomyces				
Bronchoscopy BAL and brushings (10/1)	Superior segment of right lower and right middle lobe shows rare yeast cells resembling Blastomyces				

Comment [N6]: Too large

Differential diagnosis of Disseminated Blastomycosis, Pneumonia, and Diffuse large B-cell lymphoma made based on clinical history and presentation.

The patient treated with Amphotericin B x 4 doses and IV Methylprednisolone TID x 3 days, then transferred to oral Itraconazole 200 mg BID and discharged on 10/04/2019. Initially, he felt well for one day after discharge. Later, he represented on 10/07/2019 with shortness of breath. The patient also complained of orthopnoea, loose stools, one episode of dizziness, and tripped and fell.

The patient treated with 3L O2, one dose of methylprednisolone x40 mg, and a loading dose of Itraconazole 200mg TID for three days. After that, respiratory status started improving and weaned off from O2. He received 200 mg Itraconazole and Amphotericin B. The Patient will likely need to be on Itraconazole for life.

The final diagnosis of Disseminated Blastomycosis with secondary cutaneous Blastomycosis in a followup case of diffuse large B-cell lymphoma made.

Discussion

Comment [N7]: Check whether independently written result and discussion?

Blastomycosis of the skin can present as primary cutaneous and as a sign of a disseminated form. Cutaneous lesions are usually symmetrical, single or multiple, and commonly on the trunk region (6). The characteristic skin lesion is verrucous with crusting, and central punctuate draining microabscesses. However, ulcers, violaceous nodules, and pustules are also reported (8). Primary Blastomycosis of the skin is a sporadic disease. It commonly occurs due to skin trauma leading to the introduction of fungus (6). Skin is the most usual site (40-80%) of the dissemination of pulmonary (as seen in our case), followed by bone (10-50%), genitourinary tract (10-30%), and central nervous system (1-5%) (3, 9). The mortality is very high with central nervous system (CNS) involvement (3).

Differential diagnosis of Pneumonia was ruled out due to lack of evidence on chest x-ray and computed tomography scan. All the lung and skin findings were consistent with Blastomycosis only. The patient had no lymphadenopathy, and the skin biopsy did not show the presence of lymphoma cells. Thus, Diffuse large B cell lymphoma recurrence also ruled out.

In our case, It has developed in an immunocompromised patient (known case of diffuse large B cell lymphoma in remission). Literature states that Blastomycosis is not an opportunistic infection, but immunosuppression is a risk factor for more severe lung disease (1). Patients with compromised cell-mediated immunity are more prone to symptomatic infection. Previous studies have also reported its incidence in hematological cancers and solid organ transplant recipients (8).

Blastomyces dermatitidis is a thermally dimorphic variety of fungus, depicting its mycelial form at room temperature and the yeast form at 37°C (9). The isolation in the laboratory shows it in the mycelial phase incubated at 30°C. However, identification is confirmed by its conversion to the yeast phase at 37°C or the use of nucleic acid amplification techniques that detect mycelial-phase growth. On microscopic examination, the yeast cells are multinucleate, with a diameter of 8–15 µm having thick refractile cell walls, and a single, large, broad-based bud (1). The diagnosis of Blastomycosis is made by visualizing yeast forms in tissues and body fluids (3). For rapid

Comment [N8]: Use small letter

diagnosis, respiratory secretions smear microscopy or histopathological examination of tissue specimens was done (8). In our case, yeast and spores detected in smears and tissue specimens. Yeast forms can be seen in hematoxylin and eosin-stained sections but are better visualized with methenamine silver stain or PAS stain, as reported in the literature. In our case, yeast forms of Blastomycosis visualized on PAS stain. Confirmation of the diagnosis of Blastomycosis is made by culture from either bronchial washings, pus, sputum, or biopsy material (1, 4). Although culture remains the gold standard method, it is positive in only 3.2% of the patients. The present case shows negative blood culture.

The sensitivity and specificity of a urine antigen assay for the cell wall polysaccharide of this fungus is 93% and 79%, respectively (8). This test was reported positive in the present case. However, the test is not specific for Blastomycosis, and cross-reactivity can occur with Paracoccidioidomycosis, Histoplasmosis, and Penicilliosis (8). The rate of sensitivity and specificity of the serological test is very less. The commercially available assays for complement fixation and immunodiffusion are also not beneficial in the diagnosis (8). The antigen detection test shows higher sensitivity in urine than serum (1). However, serum antigen samples showed positivity in our report.

The drug of choice is Itraconazole for immunocompetent cases having mild to moderate disease. Treatment continued for 6–12 months. Amphotericin B (AmB) preferred in immunocompromised patients with a life-threatening illness or CNS manifestations or showed disease progression during treatment with Itraconazole. Amphotericin B is also the drug of choice for disseminated forms of Blastomycosis whereas, Itraconazole preferred for cutaneous Blastomycosis. Itraconazole is the agent of choice for mild-to-moderate cases and also for step-down therapy after initial amphotericin B treatment in severe cases (8). Both these drugs are given for the treatment in our case. The use of Ketoconazole and Fluconazole has also reported (6). Surgical procedures like excision or incision and drainage may be performed if required (6). The duration of treatment for both pulmonary and disseminated forms will depend on

the disease severity or the host's immunity. Pulmonary Blastomycosis and disseminated infection with mild-to-moderate illness generally require 6 to 12 months of treatment (10). The severely ill patients with disseminated disease and those who have an osteoarticular infection got treated for 12 months (6).

Comment [N9]: Check the way of citation

As Blastomycosis is generally a diagnosis of exclusion, delays in diagnosis are common. Treatment should continue for 6 to 12 months for a complete cure. Itraconazole, 200 mg daily, is recommended life-long for immunosuppressed patients (8).

Conclusion

Comment [N10]: Make bold

To conclude, Blastomycosis is an uncommon, but potentially lethal infection. A high index of clinical suspicion is thus required to recognize this infection early, make a timely diagnosis, and prevent further dissemination.

References

1. Donna C. Sullivan; Rathel L. Nolan, III. Blastomycosis. Kasper DL, Fauci AS, Hauser SL, Longo DL, Jameson JL, Loscalzo J, and editors. Harrison's principles of the internal medicine 19th ed. McGraw-Hill Education; 2015. pp. 1137-39.
2. Litvinov IV, Paradis M, Sheppard DC. Blastomycosis in Quebec, Canada: Highlighting the Importance of Exposure to Decaying Wood in Patients. *J Infect Dis Ther* 2014;2: 129. DOI: 10.4172/2332-0877.1000129
3. Rao GR, Narayan BL, Durga Prasad BK, Amareswar A, Sridevi M, Raju B. Disseminated Blastomycosis in a child with a brief review of the Indian literature. *Indian J Dermatol Venereol Leprol.* 2013; 79(1): 92-96. DOI:10.4103/0378-6323.104676
4. Kumar A, Kunoor A, Eapen M, Singh PK, Chowdhary A. Blastomycosis Misdiagnosed as Tuberculosis, India. *Emerg Infect Dis.* 2019;25(9):1776-1777. DOI:10.3201/eid2509.190587

5. Kline L. Cutaneous blastomycosis: A case report and review of the literature. *Journal of the American Academy of Dermatology*, Volume 64, Issue 2, AB105
6. Dhamija A, D'Souza P, Salgia P, Meherda A, Kothiwala R. Blastomycosis presenting as solitary nodule: a rare presentation. *Indian J Dermatol*. 2012;57(2):133-135. DOI:10.4103/0019-5154.94285
7. Yan L, Rohra P, Cheng L, Gattuso P. Pleural Effusion in Pulmonary and Extrapulmonary Blastomycosis. *Acta Cytol*. 2020;64(3):241-247. DOI:10.1159/000500973
8. Smith JA, Kauffman CA. Blastomycosis. *Proc Am Thorac Soc*. 2010;7(3):173-180. DOI:10.1513/pats.200906-040AL
9. Putman MS, Shah NS, Husain AN, David MZ. Extrapulmonary intrathoracic Blastomycosis: a case report and systematic literature review. *JMM Case Rep*. 2015;2(1). <https://doi.org/10.1099/jmmcr.0.000022>.
10. Chapman SW, Dismukes WE, Proia LA, Bradsher RW, Pappas PG, Threlkeld MG, Kauffman CA. Clinical practice guidelines for the management of Blastomycosis: 2008 update by the Infectious Diseases Society of America. *Clin Infect Dis* 2008;46:1801–1812. DOI:10.1086/588300.

Legends

Figure 1: Shows painless, violaceous skin lesions over left chest wall and right inner thigh.

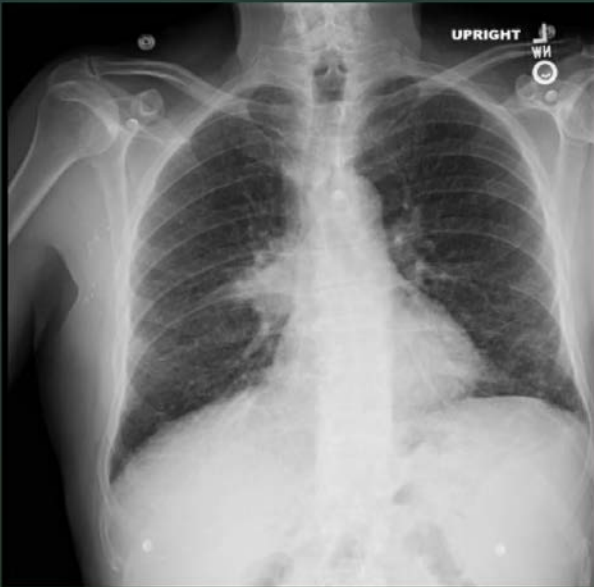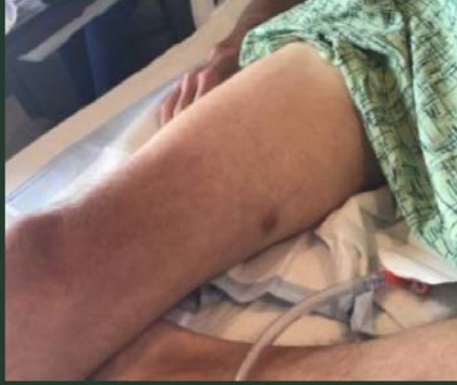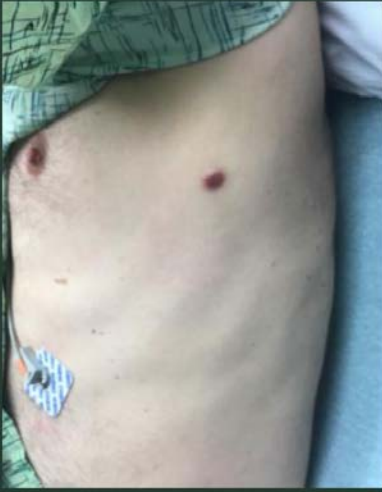Figure 2&3: New Right hilar prominence with posterior midlung opacification
Left base shows small patchy nodular opacities.

Figure 4: Bulky diffuse adenopathy. Broad area of consolidation in superior right lower lobe- largest area being 7.9x5.5 cm. Diffuse septal thickenings. Groundglass opacities throughout both lungs

Figure 5: Medium sized spore forms and possible broad budding yeast of Blastomyces

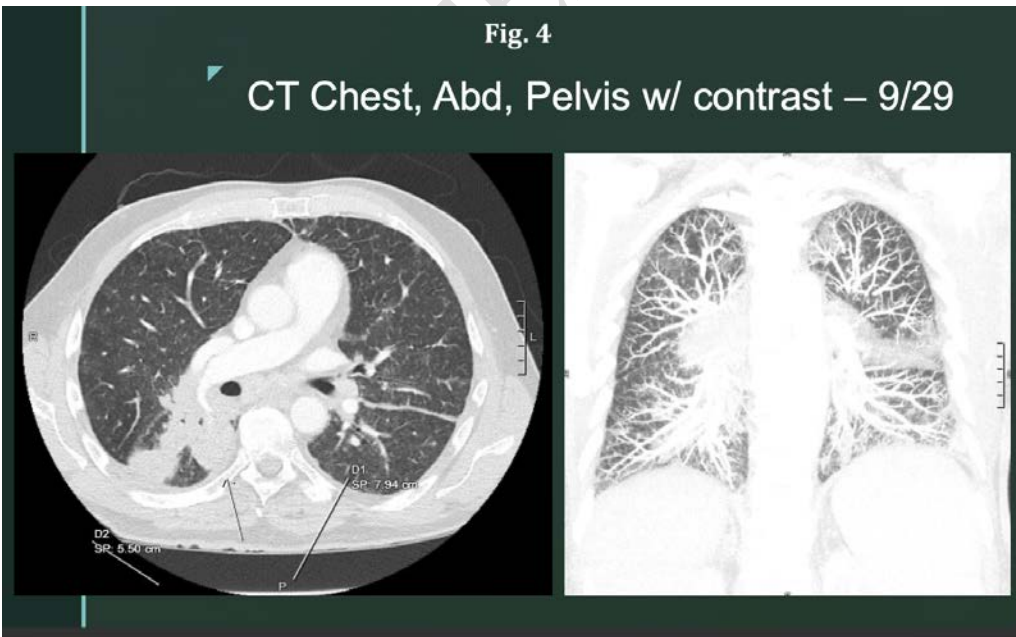
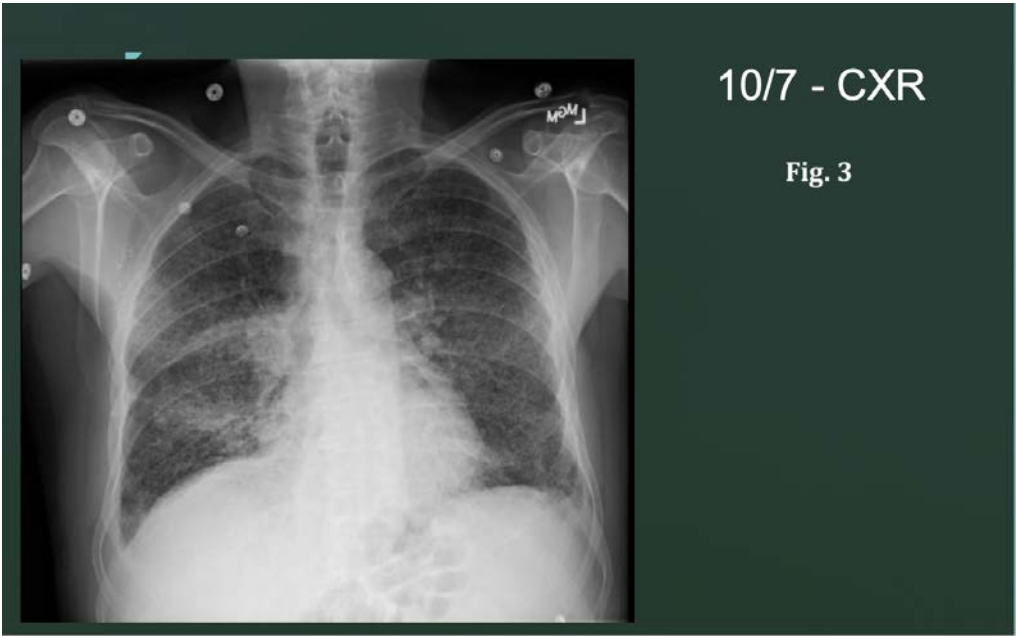
Fig.1

Skin Lesions



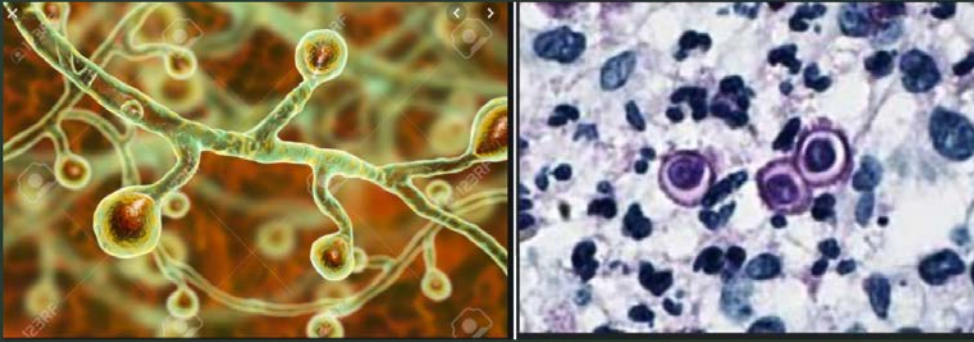
CXR on 9/29

Fig. 2



BLASTOMYCOSIS

Fig. 5



UNDER PEEI