

Case study

Mycobacterium Avium Complex Presenting as a Lung Mass, broncho-pleural fistula and Empyema in an Immunocompetent Patient-A Case Report and Review of Literature

Abstract

Mycobacterium avium complex (MAC) is a non-tuberculous mycobacteria (NTM) that causes subacute or chronic nodular bronchiectasis, cavitory or fibro-cavitory pneumonia in patients with chronic structural lung pathology including emphysema, chronic bronchitis, and bronchiectasis. It is also known to cause pulmonary and extrapulmonary infections in patients with impaired cell mediated immunity such as transplant recipients, and AIDS where it can cause disseminated infections. Empyema from MAC has been reported in immunocompromised patients and is a rare phenomenon. Here we report a patient who presented with chronic left pleural effusion and a left lower lobe lung mass that went undiagnosed for 2 years, ~~despite extensive work up~~. Later in his course, he presented with a large effusion complicated by a bronchopleural fistula and was diagnosed as MAC empyema. To our knowledge, this is the first case of MAC empyema, that presented as a chronic lung mass, complicated by a bronchopleural fistula. In this

Formatted: Font: Italic

article, we present the clinical, laboratory, and radiological features, with emphasis on a combined medical and surgical approach in the management of MAC empyema. We also provide a brief overview of cases of MAC associated pleurisy and empyema that have been reported in literature.

Keywords

Broncho-pleural fistula, ~~C~~hronic pleural effusion, COPD, empyema, lung mass, ~~COPD~~, MAC, *Mycobacterium avium* complex, ~~broncho-pleural fistula~~.

Formatted: Font: Italic

Background

The most common clinical presentation of NTM infection is that of pulmonary disease, often diagnosed in patients with underlying structural airway disease such as bronchiectasis, chronic obstructive pulmonary disease (COPD), or cystic fibrosis. In recent years, there has been a gradual increase in the incidence and prevalence of NTM pulmonary disease around the world, particularly in the elderly and those with COPD and bronchiectasis (1-4). The reasons for this increase is unclear but presumed to be multifactorial including alterations in the environment, host, and microbes (5-8).

The most common slow- growing NTM belong to the *Mycobacterium avium* complex which now consists of 12 different species. The most common to cause pulmonary disease are *M. avium*, *M. intracellulare*, and *M. chimaera*. Other important NTM causing pulmonary disease are *M. kansasii* and *M. xenopi* (9). *M. abscessus* and *M. fortuitum* are the most common causative agents of

Formatted: Font: Italic

pulmonary disease ~~due to rapidly growing mycobacteria and frequently cause lung abscess~~ (10, 11). Most of these mycobacteria, have not been associated with pleural involvement or empyema.

It is well known that the most frequent causes of pulmonary empyema are *Streptococci, Staphylococcus aureus, Enterobacteriaceae* or other anaerobes.

Formatted: Font: Italic

Among mycobacteria, *M. tuberculosis* is likely to cause pleurisy, pleural effusion, broncho-pleural fistula, and empyema. Pleural inflammation resulting in pleurisy, and empyema is a rare complication of -non-tuberculous mycobacterial infection of the lung.

Pleural involvement with pleurisy and pleural effusion is a frequent finding in *M. tuberculosis* but uncommon with MAC (12). Few studies of pulmonary MAC presenting as a lung mass, pleural effusion or empyema have been reported in literature (13-15). Prior studies have reported that 3.5-6% patients with pulmonary MAC present with pleurisy and pleural effusion, with a mortality rate of 37-66% at 1 year (16).

To our knowledge, this is the first case of MAC empyema, that presented as a chronic lung mass, complicated by a bronchopleural fistula and empyema. In this article, we present the clinical, laboratory, and radiological features, and discuss medical and surgical management of MAC empyema in a patient. We also provide

a brief overview of cases of MAC associated pleurisy and empyema that have been reported in literature.

Case Report

A 72-year old caucasian male with past medical history of chronic smoking with COPD, Atrial fibrillation, GERD, AVM ascending colon, abdominal aortic aneurysm, known 6 cm left lower lobe lung mass admitted with chief complaints of progressively worsening shortness of breath associated with left sided chest discomfort and productive cough with yellowish sputum for about 2-3 weeks. He also stated that he has had the lung mass for over 2 years, has had a -lung biopsy that was negative for cancer. He also had sputum tested in the past and was negative. His only travel outside the country was to South Korea in 1960s. No known sick contacts, exposure to tuberculosis, has had PPD test done twice over the last 3 years that was reported negative. He denied any fevers, chills, abdominal pain, loss of- appetite, loss of weight, night sweats, exposure to birds or animals. He also denied being homeless or incarcerated that would place him under a high risk for pulmonary tuberculosis.

Reviewing his past records, a chest X-ray done 3 months ago revealed a left lower lobe cavitory lesion. ~~A-~~ The CT thorax at that time showed the cavity plus a left lower lobe 6 cm mass lesion with a small effusion. He underwent extensive work

up at that time including PET scan, a core biopsy by intervention radiology, sputum cultures for acid fast bacilli, -cytology and pathology all of which came back negative. This admission he had a chest X-ray that showed left moderate effusion (Figure 1), CT thorax showed a complex loculated left pleural effusion with broncho-pleural fistula, significant mediastinal/para-aortic lymphadenopathy and the known LLL mass (Figure 2). He was started on empiric therapy for community acquired bacterial pneumonia with levaquin, placed in air borne isolation to rule out tuberculosis and infectious disease team was consulted who and was switched to Vancomycin and Moxifloxacin. Work up included sputum for bacterial Gram stain and cultures, fungal stain and cultures, AFB stain and cultures, histoplasma urine antigen, serum galactomannan antigen, thoracentesis was performed that showed turbid purulent fluid but all cultures were reported negative. Histoplasma urine antigen and pleural fluid galactomannan antigen tests were negative. Thoracic surgery was consulted and patient underwent left thoracotomy, lysis of extensive adhesions in the left pleural space, disruption of multiple loculated pockets of gelatinous fluid and fibrin debris. This was followed by decortication of the lung around the pleural peel. The left lower lobe mass that was visualized on CT thorax, adjacent to the diaphragm was found to be significant inflammatory tissue. AFB stain was positive, *Mycobacterium tuberculosis* DNA amplification was negative, sputum cultures 2 weeks later showed *Mycobacterium*

Formatted: Font: Italic

avium intra-cellulare (MAC). Stains for Mycobacteria and fungi on pathology tissue specimens were negative. However, pathology showed -fibrin, granulation tissue, fibrosis, inflamed fibroid tissue interspersed with fibrinopurulent exudate. Airborne isolation was discontinued, antibiotics were stopped and patient was started on 3-drug therapy for MAC with azithromycin 500_mg once daily, ethambutol 1.3_gm once daily, and rifampin 600_mg once daily. His baseline liver function tests were normal, he was advised to have visual acuity and color discrimination exams every 2 months with ophthalmology team and discharged home. He tolerated his medications, was adherent to MAC therapy and was treated for a total of 12 months from the day of negative AFB sputum. He was clinically back to baseline with no shortness of breath, cough, or sputum production. He was doing fine during his 3 month follow-up clinic appointment after stopping MAC therapy. His pulmonary function tests were stable with no worsening. ~~A-~~ The CT thorax was repeated that showed complete resolution of the left pleural effusion and the areas of both the left lower lobe mass and left upper lobe cavity now showed scarring, band of fibrosis with atelectasis.

Discussion

Mycobacterium avium complex (MAC) causes subacute or chronic nodular bronchiectasis, cavitary or fibro-cavitary pneumonia in patients with chronic structural lung pathology including emphysema, chronic bronchitis, and

Formatted: Font: Italic

bronchiectasis (16, 17). Disseminated infection has been reported in patients with AIDS and those with immunocompromised conditions. Our patient had local pulmonary pathology and not a disseminated MAC infection.

Although frequently seen in *M. tuberculosis*, bronchopleural fistula with empyema secondary to MAC is a rare phenomenon (12). To date, very few cases of -MAC empyema have been reported in literature. Most infections are chronic and indolent in nature and symptoms and signs may go on for months or years before a diagnosis is made as in this case (18-20).

Several cases of pneumothorax have been reported with pulmonary MAC infection (21, 22). Another unique risk factor for MAC empyema has been reported to be gamma interferon autoantibodies, a late-onset adult immune-deficiency disorder. Pulmonary infection with pleurisy, empyema and disseminated MAC have been reported in these patients (23-25).

One of the largest collection of cases of NTM related pleurisy was recently reported by [Ando et al. ????](#) It was a retrospective chart study over a 10-year period. They identified 1,044 cases with pulmonary NTM, the mean age was 69 years, NTM pleuritis occurred in 15 cases (1.4%), 6 cases (40.0%) were complicated by pneumothorax, subpleural cavities were radiologically detected in 11 cases (73.3%), and extrapulmonary air-fluid level was detected in 14 cases

(93.3%). Eleven patients were treated with combinations of 2–4 antimycobacterial drugs, including clarithromycin, and 2 patients were treated with isoniazid, rifampicin, and ethambutol. Chest tube drainage was performed in 11 cases, and surgical approach was added in 6 cases. The pleural effusion of 2 patients treated with only antimycobacterial medications gradually deteriorated. Two patients died from NTM pleuritis, and 1 patient died from pneumonitis during a mean of 1.8 years of follow-up (13).

It is important to understand that isolation of MAC from respiratory specimens, by itself, is not diagnostic for pulmonary MAC because it is known to colonize the airways of patients with chronic structural lung diseases. According to guidelines recently released by the American Thoracic society (ATS) and Infectious Disease Society of America (IDSA), diagnosis of pulmonary MAC infection requires the presence of clinical, laboratory (culture) and radiological criteria. Patients who have evidence of colonization alone, need to be closely followed for any pulmonary symptoms or new radiographic abnormalities. Authors recommend that clinicians need to perform a careful assessment of the pathogenicity of the organism, risks and benefits of therapy, and detailed discussion with patients regarding their wish to adhere to long term therapy prior to initiating combination drug treatment. In some instances, if all criteria for treatment are not met,

“watchful waiting” with close follow up for clinical or radiological deterioration may be the preferred course of action. (26).

Although the clinical, radiological features may resemble *M. tuberculosis*, pulmonary MAC rarely presents with pleural effusion, mass, bronchopleural fistula, or empyema. Interestingly our patient presented with all the above unique and rare features. The initial presentation was a mass 2 years prior to his diagnosis during which time malignancy was suspected, but lung biopsy showed benign lung with chronic inflammation. Subsequently patient developed left sided chronic pleural effusion, thoracentesis revealed an exudate but mycobacterial, fungal, and bacterial cultures were negative a year ago. Diagnosis was finally made when patient presented with an empyema and broncho-pleural fistula requiring both medical and surgical management.

The pathophysiology of pleural involvement in our patient is likely from disruption of the sub-pleural inflammatory left lower lobe mass into the left pleural space causing empyema and progressive worsening of symptoms and signs. As stated earlier the left lower lobe mass was inflammatory tissue that had significantly decreased in size at the time of thoracotomy and was not clearly visualized. The mass/ inflammatory tissue was likely bridging one of the terminal bronchioles and the pleura. Necrosis and spontaneous disruption of the inflammatory mass is likely to have resulted in the broncho-pleural fistula and empyema. Performance of

video-assisted thoracoscopic surgery (VATS) with debridement, drainage, and decortication followed by triple drug combination treatment with azithromycin, ethambutol and rifampin resulted in a successful outcome in our patient.

This case emphasizes the fact that pulmonary MAC could masquerade as a lung mass, and have a chronic indolent presentation. Undiagnosed and untreated, it could linger on for years prior to presenting with complications such as pleural effusion, bronchopleural fistula, and empyema. Medical treatment alone for empyema and bronchopleural fistula has been associated with clinical failure and poor prognosis. Combined medical and surgical approach in a timely fashion is essential for a successful outcome (27-29). A high index of clinical suspicion, appropriate testing for NTM and a timely medical and surgical interventions are keys to successful management that would result in improved morbidity and mortality in complicated cases.

References

1. Marras TK, Mendelson D, Marchand-Austin A, May K, Jamieson FB. Pulmonary nontuberculous mycobacterial disease, Ontario, Canada, 1998–2010. *Emerg Infect Dis* 2013; 19:1889–91.
2. Adjemian J, Olivier KN, Seitz AE, Holland SM, Prevots DR. Prevalence of nontuberculous mycobacterial lung disease in US Medicare beneficiaries. *Am J Respir Crit Care Med* 2012; 185:881–6.
3. Prevots DR, Marras TK. Epidemiology of human pulmonary infection with nontuberculous mycobacteria: a review. *Clin Chest Med* 2015; 36:13-34.

4. Henkle E, Hedberg K, Schafer S, Novosad S, Winthrop KL. Population-based incidence of pulmonary nontuberculous mycobacterial disease in Oregon 2007 to 2012. *Ann Am Thorac Soc* 2015; 12:642–7.
5. van Ingen J, Hoefsloot W, Dekhuijzen PN, Boeree MJ, van Soolingen D. The changing pattern of clinical *Mycobacterium avium* isolation in the Netherlands. *Int J Tuberc Lung Dis* 2010; 14:1176–80.
6. Simons S, van Ingen J, Hsueh PR, Van Hung N, Dekhuijzen PN, Boeree MJ, van Soolingen D: Nontuberculous mycobacteria in respiratory tract infections, eastern Asia. *Emerg Infect Dis* 2011; 17: 343–349.
7. Namkoong H, Kurashima A, Morimoto K, Hoshino Y, Hasegawa N, Ato M, Mitarai S: Epidemiology of pulmonary nontuberculous mycobacterial disease, Japan. *Emerg Infect Dis* 2016; 22: 1116–1117.
8. Cassidy PM, Hedberg K, Saulson A, McNelly E, Winthrop KL: Nontuberculous mycobacterial disease prevalence and risk factors: a changing epidemiology. *Clin Infect Dis* 2009; 49:e124–e129.
9. van Ingen J, Turenne CY, Tortoli E, Wallace RJ Jr, Brown-Elliott BA. A definition of the *Mycobacterium avium* complex for taxonomical and clinical purposes, a review. *Int J Syst Evol Microbiol* 2018; 68:3666–77.
10. Jo KW, Kim JW, Hong Y, Shim TS: A case of empyema necessitans caused by *Mycobacterium abscessus*. *Respir Med Case Rep* 2012; 6: 1–4.

11. Matsumoto T, Otsuka K, Tomii K: *Mycobacterium fortuitum* thoracic empyema: a case report and review of the literature. *J Infect Chemother* 2015; 21: 747–750.
12. Inzirillo, Francesco & Giorgetta, Casimiro & Ravalli, Eugenio & Tiberi, Simon & Robustellini, Mario & Della Pona, Claudio. (2014). Bronchopleural fistula, tuberculous empyema and bilateral lung destruction treated in various stages by medical and surgical intervention. *Indian Journal of Thoracic and Cardiovascular Surgery*. 30. 241-243. 10.1007/s12055-014-0298-5.
13. Ando T, Kawashima M, Matsui H, Takeda K, Sato R, Ohshima N, Nagai H, Kitani M, Hebisawa A, Ohta K: Clinical Features and Prognosis of Nontuberculous Mycobacterial Pleuritis. *Respiration* 2018;96:507-513.
14. Asai K, Urabe N. Acute empyema with intractable pneumothorax associated with ruptured lung abscess caused by *Mycobacterium avium*. *Gen Thorac Cardiovasc Surg*. 2011 Jun;59(6):443-6.
15. Haider A, Schliep T, Zeana C. Nontuberculous mycobacterium disease with pleural empyema in a patient with advanced AIDS. *Am J Med Sci*. 2009 Nov;338(5):418-20.
16. Griffith DE, Aksamit T, Brown-Elliott BA, Catanzaro A, Daley C, Gordin F, Holland SM, Horsburgh R, Huitt G, Iademarco MF, Iseman M, Olivier K,

- Ruoss S, von Reyn CF, Wallace RJ Jr, Winthrop K: An official ATS/IDSA statement: diagnosis, treatment, and prevention of nontuberculous mycobacterial diseases. *Am J Respir Crit Care Med* 2007; 175: 367–416.
17. Raju S, Ghosh S, Mehta AC. Chest CT Signs in Pulmonary Disease: A Pictorial Review. *Chest*. 2017 Jun;151(6):1356-1374.
18. Wassilew N, Hoffmann H, Andrejak C, Lange C: Pulmonary disease caused by non-tuberculous mycobacteria. *Respiration* 2016; 91: 386–402.
19. Lim JG, O SW, Lee KD, Suk DK, Jung TY, Shim TS, Chon GR: *Mycobacterium intracellulare* pleurisy identified on liquid cultures of the pleural fluid and pleural biopsy. *Tuberc Respir Dis (Seoul)* 2013; 74: 124–128.
20. Shu CC, Lee LN, Wang JT, Chien YJ, Wang JY, Yu CJ: Non-tuberculous mycobacterial pleurisy: an 8-year single-centre experience in Taiwan. *Int J Tuberc Lung Dis* 2010; 14: 635–641.
21. Kobashi Y, Mouri K, Obase Y, Kato S, Oka M: Clinical analysis of patients with pulmonary nontuberculous mycobacterial disease complicated by pneumothorax. *Intern Med* 2013; 52: 2511–2515.
22. Ikeda M, Takahashi K, Komatsu T, Tanaka T, Kato T, Fujinaga T: The frequency and treatment of pneumothorax associated with pulmonary

nontuberculous mycobacterial infection. *Gen Thorac Cardiovasc Surg* 2017; 65: 117–121.

23. DeLeon TT, Chung HH, Opal SM, Dworkin JD. Mycobacterium avium complex empyema in a patient with interferon gamma autoantibodies. *Hawaii J Med Public Health*. 2014 Sep;73(9 Suppl 1):15-7.
24. Patel SY, Ding L, Brown MR, et al. Anti-IFN- γ autoantibodies in disseminated nontuberculous mycobacterial infections. *Journal of Immunology*. 2005;175:4769–4776.
25. Tanaka Y, Hori T, Ito K, Fujita T, et al. Disseminated Mycobacterium avium complex infection in a patient with autoantibody to IFN- γ *Internal Medicine*. 2007;46:1005–1009.
26. Charles L. Daley, Jonathan M. Iaccarino, Christoph Lange, Emmanuelle Cambau, Richard J. Wallace, Jr. Treatment of Nontuberculous Mycobacterial Pulmonary Disease: An Official ATS/ERS/ESCMID/IDSA Clinical Practice Guideline *Clinical Infectious Diseases*® 2020;71(4):e1–e36
27. Aznar ML, Zubrinic M, Siemienowicz M, Hashimoto K, Brode SK, Mehrabi M, Patsios D, Keshavjee S, Marras TK. Adjuvant lung resection in the management of nontuberculous mycobacterial lung infection: A retrospective matched cohort study. *Respir Med*. 2018 Sep;142:1-6.

28. Kotani K, Hirose Y, Endo S, Yamamoto H, Makihara S. Surgical treatment of atypical *Mycobacterium intracellulare* infection with chronic empyema: a case report. J Thorac Cardiovasc Surg. 2005 Sep;130(3):907-8.
29. Park S, Jo KW, Lee SD, Kim WS, Shim TS: Clinical characteristics and treatment outcomes of pleural effusions in patients with nontuberculous mycobacterial disease. Respir Med 2017; 133: 36–41.

Table 1: Clinical, Laboratory and Radiological features of case patient

Serum WBC	12.4
Hemoglobin	10.2
Platelets	358
Serum BUN	24
Creatinine	0.9
Liver function tests	Normal
Pleural fluid appearance	Turbid and purulent
WBC	17035 (76% PMNs, 19% M, 5% L)
RBC	5000
Pleural fluid Protein	4.1
Pleural fluid LDH	2362
Pleural fluid Glucose	1
Sputum and Pleural Fluid Microbiology	Bacterial, Fungal cultures negative MAC culture positive <i>M. tuberculosis</i> DNA probe negative

Pleural Fluid Antigen	Galactomannan, β - D glucan negative
Pleural Tissue Pathology	Fibrin, granulation tissue, fibrosis, inflamed fibroid tissue interspersed with granulomatous inflammation, and fibrinopurulent exudate. AFB, Fungal stains negative
Serum Galactomannan Antigen	Negative
Urine Histoplasma Antigen	Negative
Serum TB Quantiferon	Negative
Medical management	Azithromycin, Rifampin & Ethambutol for 12 months post negative sputum culture.
Surgical Management	VATS, drainage, decortication

Table 2

Clinical, Radiological and PFT Changes Pre and Post MAC treatment

Changes	Pre- Treatment	Post-Treatment
Clinical features	Shortness of breath, productive cough with yellow sputum, left chest pain, Loss of weight from 200 pounds to 165.5 pounds in 3 months	Resolution of all symptoms. Weight gain from 165.5 to 194 pounds in 8 months
Pulmonary Function Tests	FEV1: 3.27 FVC: 4.75 DLCO: 60	3.2 4.49 53
CT Thorax	Left lower lobe mass,	Resolution of left lower lobe

	bronchopleural fistula, complex loculated left pleural effusion, emphysematous changes, fibronodular changes.	mass, bronchopleural fistula. loculated effusion with band like atelectasis and scarring in LLL. Persistent emphysematous changes.
--	---------------------------------------------------------------------------------------------------------------	------------------------------------------------------------------------------------------------------------------------------------

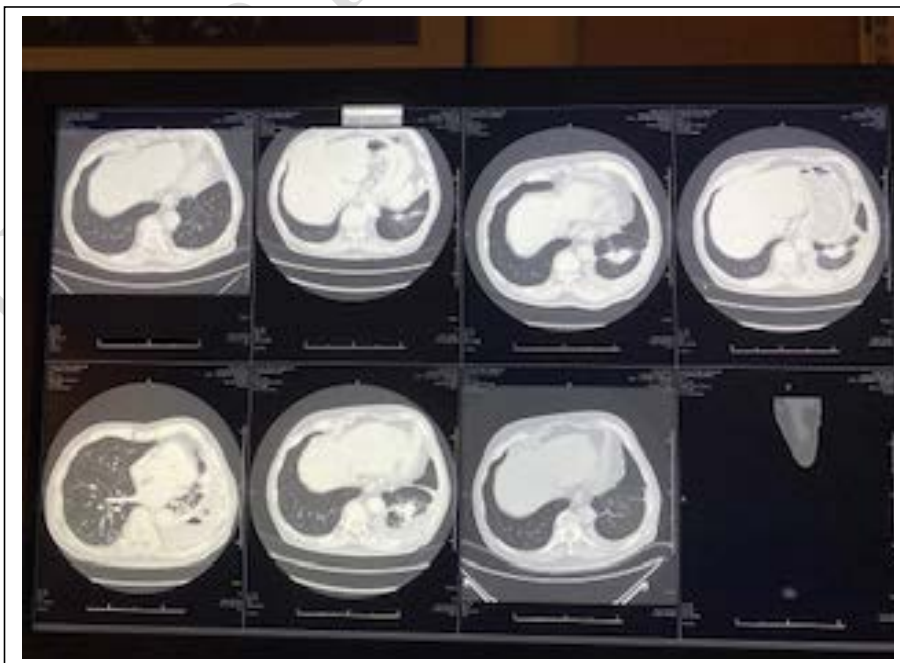
Figure 1.

Left lower lobe consolidation/mass with pleural effusion

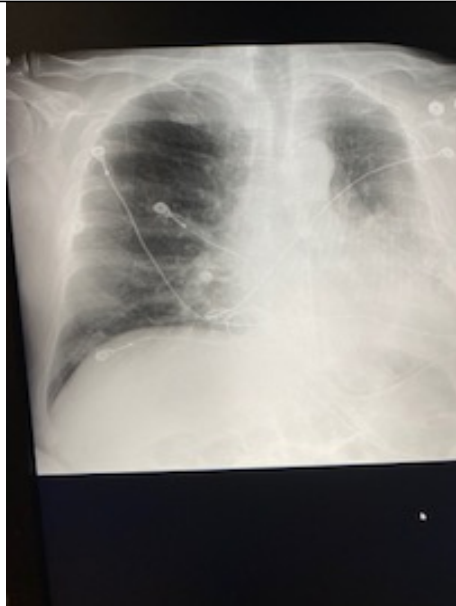

Figure 2.

Left Lower Lobe Mass, bronchopleural fistula and loculated effusion



Sequential CT thorax images, last image showing complete resolution of effusion, and mass.

UNDER PEER REVIEW

