

Antiseptic Use in Orthopaedic Wounds

Abstract

Objectives:

The aim of this study is to review the available literature addressing the safety and efficacy of antiseptics in surgical wounds. The different antiseptic solutions, irrigation volumes, time scales and delivery methods have been compared so that evidence-based recommendations on antiseptic use in orthopaedic, foot and ankle surgical procedures can be proposed.

Methods:

A literature search to identify in-vivo and in-vitro studies both in humans and animals has been carried out. They have been summarised and presented herein in a narrative format.

Results:

There is strong evidence that skin preparation with antiseptics before orthopaedic procedures reduces the risk of post-operative infection.

Conclusions:

A single agent or solution is not effective against all organisms with the logical implication that the best antiseptic preparation remains a matter of debate.

Comment [E11]: Specify study characteristics (e.g., PICOS, length of follow-up) and report characteristics (e.g., years considered, language, publication status) used as criteria for eligibility, giving rationale.

Introduction

Deep wound infections are a devastating complication of orthopaedic surgery, particularly in the presence of implants. The bacterial load required to cause clinical infection is markedly reduced in complex orthopaedic wounds (1). Two-thirds of such infections are mono-microbial, the most commonly isolated bacteria being *Staphylococcus aureus* and *Staphylococcus epidermidis* (2). Such bacteria are able to colonise the surface of implanted materials by molecular mechanisms of adherence. Microbes then form biofilms which constitute a multi-layered defence mechanism innately resistant to antimicrobial penetration. Prosthetic joint infections are thus notoriously difficult to treat, requiring prolonged courses of systemic antibiotics and implant exchange.

The focus of management should therefore be primary prevention. Peri-operative antibiotics and topical antimicrobial agents are standard practice. Wound debridement and irrigation also have major roles in prophylaxis and management of infections. However, the incidence of complex wound infections remains unacceptably high. The problem is compounded further by continuing emergence of multiply resistant bacteria. The challenge therefore remains to find an antiseptic able to eliminate targeted pathogens while being safe for the patient. This study aims to review available literature addressing the safety and efficacy of antiseptics in surgical wounds. Antiseptic solutions, irrigation volumes, time scales and delivery methods are compared.

In-Vitro Studies

Efficacy and Use of Antiseptics

The efficacy of an irrigation solution relies on solution composition and delivery. To be useful in orthopaedic practice, antiseptics must eradicate commonly encountered pathogens and act on both tissues and orthopaedic metalwork. Gainor et al (3) showed that benzalkonium chloride is more effective than saline to disinfect bovine muscle contaminated with *Staphylococcus aureus* (*S. aureus*), *Staphylococcus epidermidis* (*S. epidermidis*) or *Pseudomonas aeruginosa* (*P. aeruginosa*). Moussa et al (4) colonised stainless-steel screws with a preformed biofilm of these bacteria then immersed them in benzalkonium chloride solution, confirming its efficacy when used to disinfect orthopaedic hardware. Presterl et al (5) used biofilms of *S. epidermidis* isolated from patients with catheter-related bacteraemia and cardiac implant infections, showing that hydrogen peroxide 3% and 5% and N-propanol significantly reduced biofilm thickness, while povidone-iodine proved less effective.

Anglen et al (6) compared various solutions and delivery methods using *S. aureus*-coated stainless-steel screws. Irrigation with saline, liquid soap or antibiotics (bacitracin, neomycin and polymyxin/neomycin) had the greatest effect on *S. aureus* when using liquid soap. Washout by bulb syringe or jet lavage highlighted the importance of administration technique used; bacterial removal increased by over 100-fold with jet lavage, regardless of the solution used. A follow-up study (7) revealed bacterial elimination depends on the interplay between the irrigation solution, species present, and surface involved. Three surface types (cortical bone, stainless-steel and titanium) coated with *S. aureus*, *S. epidermidis* or *P. aeruginosa* were irrigated with normal saline, soap solution, bacitracin or neomycin. Jet lavage using all solutions resulted in considerably fewer bacteria compared to an unwashed control group. Soap solution proved superior at removing all bacteria from all three surfaces. Authors therefore concluded that when removing some species from metallic surfaces, soap solution may serve as a better irrigation additive, especially with jet lavage delivery.

The efficacy of soap solutions is concentration and time-dependent; Krueger et al (8) contaminated porcine bone segments with *S. aureus*. Soaking in normal saline, 2% chlorhexidine, or 4% chlorhexidine then re-imaging after 5, 10, 20, 30, and 60-minute intervals showed significantly fewer bacteria at all time intervals in the chlorhexidine groups compared with the saline group, but no significant difference between chlorhexidine groups. Given the potential cytotoxicity of chlorhexidine, the authors recommended soaking contaminated bone segments with 2% chlorhexidine for 20 minutes.

Cytotoxic Effects of Antiseptics

The clinical suitability of antiseptics in irrigation fluids depends on their ability to remove pathogens from orthopaedic wounds and prostheses without damaging the osteoblasts, chondrocytes, fibroblasts, keratinocytes and lymphocytes. *In-vitro* studies have enabled careful evaluation of the varying degrees of cytotoxicity associated with these cell-types.

Table 1 summarises these adverse effects associated with different antiseptics.

UNDER PEER REVIEW

UNDER PEER REVIEW

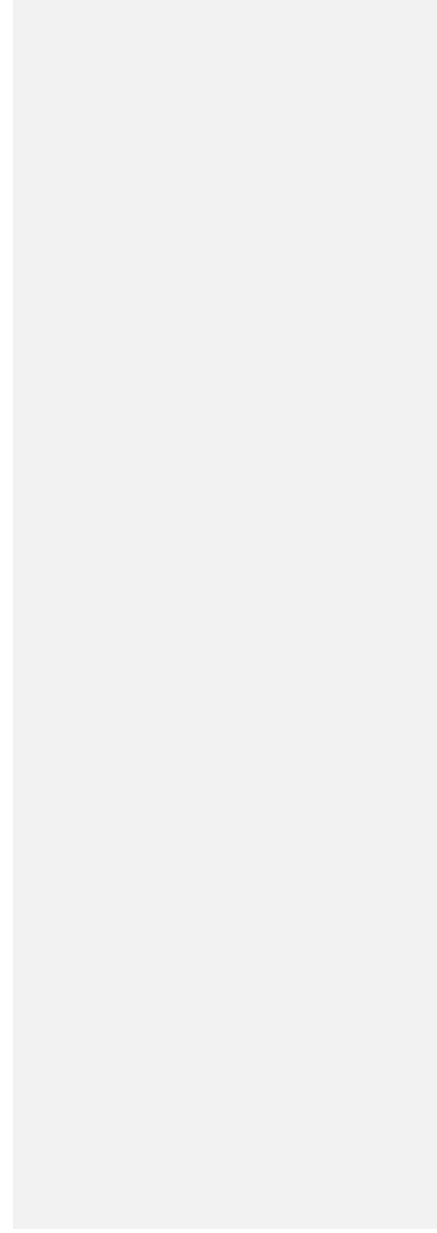


Table 1. Cytotoxic effects established by *in-vitro* studies:

Affected cell-type	Cytotoxicity					References
	Bacitracin	Hydrogen Peroxide	Povidone-iodine (PI/Betadine)	Chlorhexidine gluconate (CHX)	Other solutions	
Bone	Osteoblasts unaffected. (9, 10)	Cytotoxic to osteoblasts at high concentrations. (9, 10)	Osteoblasts: Affected in dose-(11, 12) and time- ¹⁴ dependent manner. Cytotoxicity was shown at high concentrations. (9, 10) At concentrations of up to 5% for up to 1-minute osteoblast activity was not impaired.(11) Osteoclasts: Affected in time-dependent manner.(13)	Osteoblasts: Affected in dose-(11, 12) and time- ¹⁴ dependent manner. Osteoclasts: Affected in time-dependent manner. ¹⁴ Safe at concentrations of 0.2% for up to 1 minute and 1% for up to 30 seconds.(11)	Sodium hypochlorite: Limits osteoblast growth in dose dependent manner.(11) Soap solution: Affects osteoblasts and osteoclasts in time dependent manner but preserved the greatest number of osteoclasts compared with PI and CHX.(13)	<ul style="list-style-type: none"> • Kellam et al (1994)(9) • Kaysinger et al (1995)(10) • Verdugo et al (2011)(11) • Cabral et al (2007)(12) • Bhandari et al (2001)(13)
Cartilage	Not assessed by these reviewers.	Cytotoxic to chondrocytes.(14-16)	Not assessed by these reviewers.	Not assessed by these reviewers.	Not assessed by these reviewers.	<ul style="list-style-type: none"> • Bates et al (1985)(14) • Asada et al (1999)(15) • Asada et al (2001)(16)
Connective tissue	Not assessed by these reviewers.	Reduced fibroblast activity with cytotoxicity shown at bactericidal concentrations.(18)	Reduced fibroblast activity.(18) Fibroblast cytotoxicity resulted at bactericidal concentrations.(19) Fibroblast viability retained at 1.3g/L with moderate bactericidal effect.(21)	Increased fibroblast proliferative potential at low doses.(18) Fibroblast cytotoxicity resulted at bactericidal concentrations.(19-21) Cytotoxic to stromal cells.(21)	Silver sulfasalazine: Increased fibroblast proliferative potential at low doses.(18) Therapeutic doses of local antibiotics did not damage fibroblasts.(21)	<ul style="list-style-type: none"> • Sanchez et al (1988)(18) • Mariotti et al (1999)(19) • Meurs et al (2014)(20) • Damour et al (1992)(21)
Epidermal	Not assessed by these reviewers.	Not assessed by these reviewers.	Cytotoxicity to keratinocytes was shown at bactericidal concentrations. (21)	Cytotoxicity to keratinocytes was shown at bactericidal concentrations.(21)	Therapeutic doses of local antibiotics did not damage keratinocytes.(21)	<ul style="list-style-type: none"> • Damour et al (1992)(21)

Antiseptics and MRSA

Multi-drug-resistant infections pose an even bigger challenge for eliminating pathogens while avoiding adverse effects. Methicillin-resistant *Staphylococcus aureus* (MRSA) is increasingly responsible for intra-operative infection and subsequent morbidity(22). While vancomycin is the antibiotic of choice for MRSA infections, multidrug-resistant strains with moderate vancomycin resistance have been isolated (23). This resistance increases post-operative complication rates and is further compounded by MRSA's tendency to form biofilms. Various studies have looked specifically at reducing the operative risk of MRSA by evaluating the efficacy of irrigation solutions and debridement techniques. Haley et al (24) found Povidone-iodine to be the most rapidly effective antiseptic against both MRSA and MSSA, maximal effectiveness being evident at 1:100 dilutions, which killed all strains within 15 seconds. The other three antiseptic solutions (chlorhexidine gluconate-alcohol (4%), p-chloro-m-xyleneol (1%), and hexachlorophene (3%)) tested produced 2-log reductions in the MRSA CFU count after 15 seconds of exposure but failed to kill all MRSA, even after 240 seconds of exposure.

More recent studies however, support chlorhexidine as the most effective irrigation solution for eradicating MRSA infection. Schwechter et al(25) evaluated the efficacy of a number of *in vitro* irrigation and debridement techniques for treating MRSA peri-prosthetic joint infection, using MRSA biofilm-coated titanium alloy discs as model. Irrigation and scrubbing were not shown to be more effective than irrigation alone. Both chlorhexidine and povidone-iodine scrubs reduced MRSA CFU counts pre-incubation, however, chlorhexidine was found to be the most bactericidal while the results for povidone-iodine were not statistically significant. The study therefore concluded that chlorhexidine solutions have the greatest potential to decrease biofilm load on orthopaedic implants. Determining the minimum concentration of chlorhexidine required to eradicate MRSA is important to reduce the risk of antiseptic-induced cytotoxicity. This was evaluated in an *in vitro* study by Smith et al (26) where a series of MRSA biofilm-coated titanium discs were irrigated with varying concentrations of chlorhexidine. MRSA CFUs were counted before and after a 24-hour re-incubation period. The study showed a significant reduction in CFUs at all irrigation concentrations before re-incubation. However, post re-incubation counts only demonstrated a significant decrease with 4% and 2% chlorhexidine solutions, indicating that 2% was the minimum effective chlorhexidine concentration.

In-vitro studies have generated variable and at times conflicting, data for the different irrigation solutions. Many of the *in-vitro* studies discussed in this review address either the efficacy of the antiseptic or its potential cytotoxicity which would limit its overall clinical applicability. For example, the efficacy of chlorhexidine against MRSA has been demonstrated in a number of studies (25, 26) but other studies have demonstrated potential cytotoxicity to osteoblasts, fibroblasts, stromal cells and keratinocytes which would discourage its use in clinical practice. *In-vitro* studies are limited in that they do not assess the antiseptic in the presence of all cells, chemicals, mediators and other factors that would be present in a living animal or human and which may have a role in the post-operative healing process, immune response to an invading organism, and reaction to the antiseptic itself. *In-vivo* studies are therefore essential to clarify the optimal choice and use of irrigation solutions.

Animal Studies

In the living organism, factors in addition to those monitored through in-vitro studies determine the effect of the irrigating solution. The components of the irrigating solution or the physical forces from pressure lavage may delay wound healing or facilitate wound colonisation by bacteria that may be present. Tissues in contact with the solution may mount an inflammatory response that could lead to complications, including joint fibrosis and prosthesis failure. Absorption of lavage fluid components may also lead to systemic side-effects. *In vivo* studies are therefore important to give a clearer demonstration of how an irrigating solution will perform in clinical practice.

Conroy et al (27) designed an animal study using rat models, to test the efficacy of a number of wound irrigation solutions which included normal saline, castile soap, benzalkonium chloride and bacitracin. The effectiveness of sequential irrigation with 1L each of benzalkonium, castile soap and normal saline was also tested. Orthopaedic wounds contaminated with *S. aureus* or *P. aeruginosa* were washed with 3L of the specified solution and inspected daily for 14 days. Benzalkonium irrigation alone significantly lowered the rate of *S. aureus* positive wound cultures compared with normal saline but increased the rate of *P. aeruginosa* positive wound cultures. In contrast, irrigation with either castile soap alone or sequential irrigation with benzalkonium/castile soap/saline reduced the rate of *P. aeruginosa* cultures compared to irrigation with normal saline alone. The authors proposed that benzalkonium may cause lysis of gram-negative cells leading to release of endotoxin and producing an inflammatory response. They therefore suggested that in wounds containing *P. aeruginosa*, benzalkonium can only be used safely if combined in a sequential irrigation with castile soap and normal saline.

The effectiveness of a sequential surfactant irrigation protocol in overcoming bacterial adhesion in contaminated orthopaedic implants was explored further in a randomised animal study carried out by Marberry et al (2). This study suggested that the sequential surfactant irrigation protocol is an effective method of wound irrigation in orthopaedic implants contaminated with *S. aureus* alone, while in mono-microbial *S. epidermidis* infections normal saline irrigation alone may suffice.

Irrigation devices are also applied in the treatment of open wounds, however there is currently no clear consensus for its use. Owens et al (28) compared the results of normal saline versus multiple other irrigation solutions using either a bulb syringe or pulsatile lavage. They found that both irrigation devices reduced bacterial counts but these had rebounded to almost pre-treatment levels in the pulsed lavage group while the bulb syringe group showed a significantly lower rebound. They also found that all irrigation solutions initially lowered bacterial counts, however, 48 hours after irrigation, all groups showed a rebound in bacterial counts. This rebound was the lowest with normal saline while the other solutions showed rebounds approaching or even surpassing pre-treatment levels. These findings suggested that although solutions other than normal saline may be better at initial bacterial removal, these solutions may have deleterious effects to the host tissue and these effects may be compounded by use of high-pressure devices used for their delivery. The authors therefore recommended saline solution delivered by a low-pressure device to irrigate wounds in order to reduce the risk of complications.

Povidone-iodine (Betadine) lavage is used prophylactically in various surgical sub-specialities and its efficacy in preventing surgical site infection is well established. There have, however, been concerns about its effect on fibroblasts and its potential to damage intra-capsular tissues. Baird et al (29) found 0.1% povidone-iodine lavage to be safe to use on equine tendon, as it caused only a mild synovitis similar to that caused by balanced electrolyte solution. However, 0.5% povidone iodine and 0.5% chlorhexidine caused severe synovitis and therefore should not be used for tendon sheath lavage. Moreover, chlorhexidine causes greater detriment to joints, as concentrations of just 0.05% have been shown to cause intense synovitis. Keudell et al (30) evaluated the potential chondrotoxicity of various povidone-iodine concentrations and exposure times in a cadaveric animal model. The higher concentrations all showed greater chondrotoxicity with increased exposure times,

therefore this should be considered in articular cartilage-retaining procedures, such as unicompartmental knee arthroplasty, and opting to use saline may be prudent, as reduced chondrocyte viability can contribute to early development of osteoarthritis and osteoarthritis in the residual cartilage, leading to early failure of partial knee arthroplasty. This would not, however, be a problem in total joint arthroplasties where articular cartilage is not retained.

Acute post-operative arthroplasty infection was evaluated in a rabbit prosthetic knee infection model (31). Metalwork inoculated with *S. aureus* was inserted into the knee joints for a total of seven days, following which a polyethylene washer exchange was performed and irrigation with either dilute 3.5% povidone-iodine solution or normal saline. Culture of the harvested screw, polyethylene washer, bone and joint tissue with bacterial quantification showed a significant reduction in bacterial burden on both the screw and polyethylene washer that had received povidone-iodine lavage, although there was no difference in soft-tissue growth. The study thus showed that povidone-iodine lavage may be a useful treatment adjunct in acute post-operative arthroplasty infection, and it may improve the rate of component retention.

Chlorhexidine gluconate 0.05% peritoneal lavage has been shown to be effective in reducing the rate of abscess formation following peritoneal contamination (32). However, its suitability and ideal concentration for use in joint lavage remains in dispute. Sanchez et al showed that bactericidal concentrations of chlorhexidine diacetate are lethal to canine embryonic fibroblasts *in-vitro* (18). However, a subsequent study by the same team showed that irrigation with chlorhexidine diacetate 0.05% or 0.005% provided bactericidal activity and improved wound healing compared to irrigation with saline alone, indicating that chlorhexidine diacetate concentrations that are cytotoxic to cultured fibroblasts *in-vitro* do not interfere with wound healing *in-vivo*.

Contrastingly, in a study on open fractures, Barwell et al found that both chlorhexidine and saline reduced bacterial load equally (33). However, they concluded that although chlorhexidine has an initial bactericidal benefit, the necrotic tissue caused by chlorhexidine exposure may promote a “rebound” of bacterial growth in the wound bed. They therefore suggested that saline remains the best choice for orthopaedic wound irrigation, however if chlorhexidine is preferred, a concentration of 0.05% should be used and the wound should undergo a final saline rinse to remove any residue before closure. The authors also urged particular caution with chlorhexidine lavage in wounds containing large amounts of tissue of borderline viability as such wounds may be more susceptible to the toxic effects of chlorhexidine.

The potential role of the antibacterial allicin in preventing biofilm formation in joint infection was investigated in a rabbit prosthetic joint infection model by Zhai et al (34). Biofilm counts of *S. epidermidis* were found to be lowest in rabbits treated with allicin plus vancomycin. The authors therefore concluded that allicin/vancomycin combination may have a role in treatment of prosthetic joint infections as allicin appears to inhibit biofilm formation and it can have a synergistic bactericidal effect when combined with vancomycin.

The use of different irrigation solutions in preparing bony surfaces before cementing of total joint replacement components was evaluated by Howells et al (1992)(35). Cement fixation following hydrogen peroxide irrigation was found to be statistically better than that achieved with either povidone iodine or saline. Clinically, dilute povidone-iodine lavage is generally performed following implant insertion and it therefore should not affect the bone-cement interface. However, if performing single-stage revision, the potential benefit of hydrogen peroxide should be considered.

UNDER PEER REVIEW

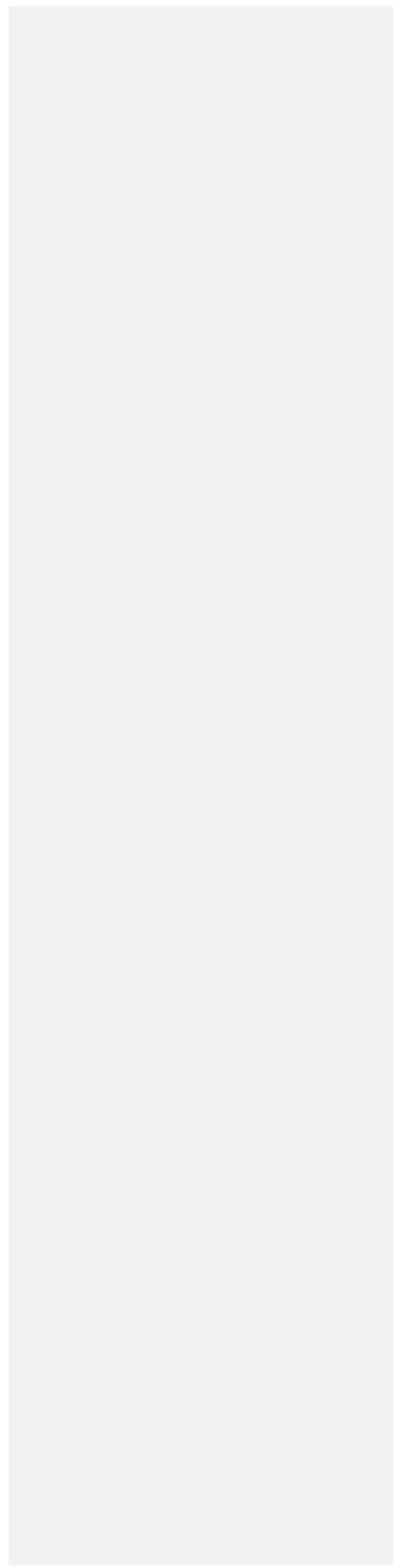


Table 2. Efficacy of irrigation solutions, as established by animal studies:

Animal Model	Irrigation solution	Recommended Irrigation Solution			References
		<i>Staphylococcus aureus</i>	<i>Staphylococcus epidermis</i>	<i>Pseudomonas aeruginosa</i>	
Rat	Normal saline (NS)	✗ (27)	✓ (2)	✗ (27)	<ul style="list-style-type: none"> • Conroy et al (1999)(27) • Marberry et al (2002)(2) • Penn-Barwell et al (2012)(33)
	Castile soap (CS)	✗ (27)	-	✓ (27)	
	Benzalkonium chloride (BzC)	✓ (27)	-	✗ (27)	
	Bacitracin	✗ (27)	-	✗ (27)	
	Chlorhexidine	✗ (27)	-	-	
	Sequential irrigation: BzC + CS + NS	✓ (2)	-	✓ (27)	
Rabbit	Normal saline	✗ (31)	✗ (34)	-	<ul style="list-style-type: none"> • Gilotra et al (2015)(31) • Zhai et al (2014)(34)
	Povidone-iodine	✓ (31)	-	-	
	Vancomycin	-	✓ (34)	-	
	Allicin + Vancomycin	-	✓ (34)	-	
Goat	Normal saline	-	-	✓ (28)	<ul style="list-style-type: none"> • Owens et al (2009)(28)
	Castile soap	-	-	✗ (28)	
	Benzalkonium chloride	-	-	✗ (31)	

✓ : Solution demonstrated statistically significant decrease in bacterial count

✗ : Solution did not demonstrate statistically significant decrease in bacterial count

- : Bacteria/solution combination not tested

Human Studies

A number of human studies have evaluated the optimal irrigation fluid composition and volume to prevent or control of the musculoskeletal infection. Though the use of lavage fluid in arthroplasty has been studied extensively, a gold standard of care has yet to be determined. Studies have shown that pre-operative skin preparation with chlorhexidine reduces the incidence of periprosthetic joint infections but its superiority over other agents such as povidone-iodine in periprosthetic joint infection is inconclusive (36). The National Institute for Health and Care Excellence (NICE, 2019) authorise the pre-operative preparation of skin using chlorhexidine (0.5% chlorhexidine in 70% alcohol solution prior to minor surgical procedures and 2.0% chlorhexidine in 70% alcohol applicators prior to invasive medical procedures), or povidone-iodine if chlorhexidine is contraindicated (37).

Although no “gold standard” of irrigation fluid currently exists for the management of open fracture wounds, a survey completed by 1764 surgeons found that the majority of surgeons’ favour both normal saline and low-pressure lavage as part of the initial treatment (38). In a recent document from the 2nd International Consensus Meeting on Musculoskeletal Infection no particular recommendation was made with regards the use of dilute povidone-iodine (betadine) irrigation or other antiseptic irrigation solutions during total ankle arthroplasty (TAA) or other foot and ankle procedures due to lack of good quality evidence (39).

Hansen and Parvizi (40) described a specific irrigation and debridement regimen involving five steps to eradicate periprosthetic infection: (1) soak the surgical site in Dakin’s solution or hydrogen peroxide for 3 minutes, (2) irrigate wound thoroughly with 3 litres of sterile saline, (3) add 0.3% dilute betadine for another three minutes while continuing to mechanically scrub and debride the surgical site, (4) irrigate surgical site again with 3 litres of sterile saline, and (5) irrigate site with 3 litres of saline containing 500,000 units of polymyxin B and 50,000 units of bacitracin. As yet, there is no secondary peer-reviewed research to affirm this protocol, although studies do describe debridement and copious irrigation of the surgical site for operative management of infection. Table 3 summarises efficacy of antiseptic solutions in humans.

Table 3. Efficacy of antiseptic solutions in humans

Study	Procedure	Variant	Indication	Antiseptic(s)	Type of Study	Outcomes Assessed	Results
Patrick et al (2017) (36)	Elective spinal surgery	Pre-op preparation	Primary prophylaxis	Skin disinfection with sequential povidone-iodine + chlorhexidine vs povidone-iodine alone twice	Randomised controlled trial	Surgical site contamination + internal bacterial contamination	Reduced risk of 30% and 37% in surgical site contamination and internal bacterial contamination with sequential disinfection
Woo et al (2018) (41)	Knee joint replacement	Intra-operative irrigation	Primary prophylaxis	Taurolidine (synthetic broad-spectrum antibiotic) irrigation	Case-control	Lower CRP + ESR values 3 days after surgery but less significant 6 days post-op with taurolidine vs control	Irrigation with taurolidine did not decrease the risk of infection
Chundamala et al (2007) (42)	General, cardiovascular, orthopaedic spine, and urologic surgery	Intra-operative irrigation	Primary prophylaxis	Povidone-iodine vs normal saline irrigation	Meta-analysis	Post-operative infection	Reduced risk of infection with povidone-iodine (p = 0.015 and p = 0.007, p < 0.05)
Brown	Hip and	Intra-	Primary	Povidone-	Case-	Post-	Significant

et al (2012) (43)	knee joint replacement	operative irrigation	prophylaxis	iodine vs normal saline irrigation	control	operative infection	reduction with povidone-iodine (0.15 vs 0.97%)
Frisch et al (2017) (44)	Hip and knee joint replacement	Intra-operative irrigation	Primary prophylaxis	Chlorhexidine 0.05% vs povidone-iodine (<2%) for hip replacement, and chlorhexidine 0.05% vs 0.9% saline for knee replacement	Case-control	Deep and superficial site infections	No significant difference
Ulivieri et al (2011) (44)	Elective spinal surgery	Intra-operative irrigation	Primary prophylaxis	Combination irrigation protocol (soak with 10 cc of 10% povidone-iodine, 5cc of water and 1cc of hydrogen peroxide and after a minute irrigation with copious sterile saline)	Case-control	Post-operative infection	Significant reduction with combination irrigation protocol (0% vs 1.5%)
Kosashvili et al (2011) (45)	Multiple and first time revision spinal surgery	Intra-operative irrigation	Primary prophylaxis	Combination irrigation protocol (povidone-iodine, hydrogen	Case-control	Post-operative infection	Reduced risk of infection with combination irrigation protocol (2.14% in multiple revision

				peroxide and bacitracin)			cases and 1.35% in first time revision cases)
Patterson et al (2005) (46)	External pin	Pin dressing	Primary prophylaxis	Half-strength peroxide and Xeroform dressing vs soap and water cleansing	Case-control	Pin-site infection	Lower infection rate with half-strength peroxide and Xeroform dressing
Woolridge et al (2013) (47)	High-grade soft tissue sarcoma resection	Adjuvant local irrigation	Primary prophylaxis	Hydrogen peroxide solution	Retrospective case-control	Local recurrence and surgical site infection	Reduced local control and infection rates
Anglen et al (2005) (48)	Lower limb open fracture	Open wound irrigation	Primary prophylaxis	Bacitracin solution vs a non-sterile castile soap solution	Randomised controlled trial	Post-operative infection	No advantage and may increase the risk of wound-healing problems with bacitracin solution
Conroy et al (1999) (27)	Complex contaminated orthopaedic wound	Open wound irrigation	Primary prophylaxis	Castile soap vs benzalkonium chloride vs anracin	Case-control	Post-operative infection	No benefit of antibiotic solutions over normal saline
Bhandari et al (2015) (49)	Open fracture	Wound irrigation	Primary prophylaxis	Castile soap versus normal saline irrigation and its pressure	Randomised controlled trial	Re-operation rate	Reduced with saline regardless of irrigation pressure
Yung Han et	Contaminated	Wound irrigation	Treatment of	3L 2% chlorhexidine	Controlled	Post irrigation	Disinfection using 3L 2%


al (2011) (50)	anterior cruciate ligament grafts	n	contaminated ligament grafts	power irrigation	laboratory study	disinfection and weakness of the anterior cruciate ligament.	chlorhexidine power irrigation does not significantly weaken the tendon.
Burd et al (2000) (51)	Contaminated Achilles tendon-calcaneus allografts	Wound irrigation	Treatment of contaminated tendon grafts	Benzalkonium chloride vs castile soap vs castile soap followed by benzalkonium chloride vs triple antibiotic vs chlorhexidine gluconate vs chlorhexidine gluconate/triple antibiotic combination	Case-control	Post-irrigation infection	2% chlorhexidine irrigation solution is effective in decontaminating bone-tendon allografts infected with <i>Staphylococcus aureus</i> , <i>Staphylococcus epidermidis</i> , <i>pseudomonas aeruginosa</i> or <i>Klebsiella pneumoniae</i> .
Ostrand et al (2005) (52)	Procedures involving the hallux, toes and tibia.	Pre-op preparation	Primary prophylaxis	DuraPrep (0.7% iodine and 74% isopropyl alcohol) vs Techni-Care (3.0% chloroxylenol) vs ChloraPrep (2% chlorhexidine gluconate and 70% isopropyl	Prospective study	Post-preparation infection of the hallux nailfold, web spaces between the 2 nd /3 rd and 4 th /5 th digits, and the anterior tibia (control)	All three solutions were effective. Of the three, ChloraPrep was most effective at bacterial elimination (p < 0.0001).

				alcohol)			
Saltzman et al (2009) (53)	Shoulder surgery	Pre-op preparation	Primary prophylaxis	ChlorPrep vs DuraPrep vs 0.75% povidone-iodine scrub + 1% iodine paint	Prospective study	Post-preparation infection of the shoulder	ChlorPrep was most effective at bacterial elimination (p < 0.0001).
Hunter et al (2016) (54)	Foot and ankle surgery	Pre-op preparation	Primary prophylaxis	70% isopropyl alcohol then 4% chlorhexidine gluconate vs 4% chlorhexidine gluconate then 70% isopropyl alcohol	Randomised prospective study	Post-preparation colonisation of the operative site.	The combination of 70% isopropyl alcohol followed by 4% chlorhexidine gluconate was more effective.
Mankovecky et al (2014) (55)	Ankle septic arthritis	Arthroscopic joint irrigation	Septic arthritis	Irrigation with lactated Ringer's solution impregnated with Bacitracin sterile powder	Case series	Infection control	Successful elimination of infection in all 15 cases
Acello et al (1995)	Open foot and ankle	Open wound irrigation	Primary prophylaxis	50,000 units bacitracin vs 25mg	Retrospective study	Post-operative infection	Irrigation with bacitracin or polymyxin is

(56)	fractures	n		polymyxin per L vs sterile saline			beneficial in reducing infection in open fracture repairs.
Wu et al (2008) (57)	Foot and ankle external fixation	Pre-op preparation	Primary prophylaxis	Chlorhexidine gluconate-impregnated polyurethane patches vs standard pin care.	Pilot trial	Post-operative infection	There were significantly lower infection rates in the group receiving chlorhexidine patches on the pin sites (0% versus 25%, P = 0.047)
Ruder et al (2017) (58)	Total joint arthroplasty	Open wound irrigation	Primary prophylaxis	17.5ml 10% povidone-iodine diluted in 500-1000cc normal saline	Expert opinion report	Post-operative infection	In primary total joint arthroplasty, 10% povidone-iodine reduces the risk of infection.
George et al (2015) (59)	Hip and knee arthroplasty	Open wound irrigation	Prosthetic joint infection	1% povidone iodine and a 50:50 dilution of 3% hydrogen peroxide	Case series	Post-operative infection	There were no recurrences of infection in 11 hips at a mean of 5 years and 28 knees at a mean of 6.5 years
Riesgo et al (2018) (60)	Total joint arthroplasty	Open wound irrigation	Prosthetic joint infection	Vancomycin povidone-iodine + irrigation and debridement with modular component and linear exchange (IDLE) vs	Case-control	Post-operative infection	Vancomycin povidone-iodine is effective in treating prosthetic joint infection with irrigation and debridement. Its use resulted in failure (infection)

				IDLE alone.			in 16.7% (6/36), lower than the control group (37%, i.e. 14/38).
--	--	--	--	-------------	--	--	---

UNDER PEER REVIEW



Adverse Effects of Irrigation

Table 4 summarises adverse effects associated with different antiseptic solutions in human.

Antiseptic fluid	Adverse Effect
Chlorhexidine	Chondrolysis(61,62)
Hydrogen peroxide	Chondrolysis (15-17), pneumocephalus and air embolism (63-67)
Povidone-iodine	Acute kidney injury (68-71), induce hyperthyroidism (68, 72-74)
Alcohol-based solutions:Chlorhexidine, povidone-iodine	Electrocautery-associated surgical fire (75-78)

Table 4. Adverse effects associated with antiseptic fluids

It is important to give numbers of studies screened, assessed for eligibility, and included in the review, with reasons for exclusions at each stage, ideally with a flow diagram.

Summarize the main findings including the strength of evidence for each main outcome; consider their relevance to key groups (e.g., healthcare providers, users, and policy makers).

Conclusion

Routine intraoperative irrigation with antiseptic solutions for the prevention or treatment of established infection should be undertaken with caution. It is advisable to consider a number of circumstances where it may be detrimental, in particular with the use of Chlorhexidine and Hydrogen Peroxide within native joint cavities in view of their chondrotoxicity. Systemic complications such as thyroid (67, 71-73) and kidney (67-70) dysfunction, air embolism and even death have been reported (63-66). There is strong evidence that skin preparation with antiseptics before orthopaedic procedures reduces the risk of post-operative infection. Although the best antiseptic preparation remains a matter of debate. A single agent or solution is also not effective against all organisms (Table 2) leading to the development of some complex regimens that are difficult to validate.

The social and economic burden of bone and joint infections associated with implants are high and life altering for the afflicted individual. The treatment invariably requires multiple procedures, prolonged inpatient stay and leads to poor functional outcomes. This combined with the emergence of resistant strains of micro-organisms and ever more compromised hosts make prevention an essential tool in the armamentarium of the surgeon. Therefore, further research is required to assess efficacy of different antiseptic solutions for prevention and treatment of infection.

Comment [E12]: Provide a general interpretation of the results in the context of other evidence, and implications for future research.

References

1. Gristina AG, Naylor PT and Webb LX. Molecular mechanisms in musculoskeletal sepsis: the race for the surface. *Instr Course Lect.* 1990;39:471-82.
2. Marberry KM, Kazmier P, Simpson WA, Christensen GD, Phaup JG, Hendricks KJ, Anglen JO and Gainor BJ. Surfactant wound irrigation for the treatment of staphylococcal clinical isolates. *ClinOrthopRelat Res.* 2002(403):73-9.
3. Gainor BJ, Hockman DE, Anglen JO, Christensen G and Simpson WA. Benzalkonium chloride: a potential disinfecting irrigation solution. *J Orthop Trauma.* 1997;11(2):121-5.
4. Moussa FW, Gainor BJ, Anglen JO, Christensen G and Simpson WA. Disinfecting agents for removing adherent bacteria from orthopaedic hardware. *ClinOrthopRelat Res.* 1996(329):255-62.
5. Presterl E, Suchomel M, Eder M, Reichmann S, Lassnigg A, Graninger W and Rotter M. Effects of alcohols, povidone-iodine and hydrogen peroxide on biofilms of *Staphylococcus epidermidis*. *J AntimicrobChemother.* 2007;60(2):417-20.
6. Anglen JO, Apostoles S, Christensen G and Gainor B. The efficacy of various irrigation solutions in removing slime-producing *Staphylococcus*. *J Orthop Trauma.* 1994;8(5):390-6.
7. Anglen JO and DiPasquale T. The reliability of detecting screw penetration of the acetabulum by intraoperative auscultation. *J Orthop Trauma.* 1994;8(5):404-8.
8. Krueger CA, Masini BD, Wenke JC, Hsu JR and Stinner DJ. Time-dependent effects of chlorhexidine soaks on grossly contaminated bone. *J Orthop Trauma.* 2012;26(10):574-8.
9. Kellam J, Ramp W, Nicholson N and Kaysinger K. Effects of Wound Irrigation Solution on Osteoblast Function. *Journal of Orthopaedic Trauma.* 1994;8(3):271.
10. Kaysinger KK, Nicholson NC, Ramp WK and Kellam JF. Toxic effects of wound irrigation solutions on cultured tibiae and osteoblasts. *J Orthop Trauma.* 1995;9(4):303-11.
11. Verdugo F, Saez-Roson A, Urizarri A, Martinez-Conde R, Cabezas-Olcoz J, Moragues MD and Ponton J. Bone microbial decontamination agents in osseous grafting: an in vitro study with fresh human explants. *J Periodontol.* 2011;82(6):863-71.
12. Cabral CT and Fernandes MH. In vitro comparison of chlorhexidine and povidone-iodine on the long-term proliferation and functional activity of human alveolar bone cells. *Clin Oral Investig.* 2007;11(2):155-64.
13. Bhandari M, Adili A and Schemitsch EH. The efficacy of low-pressure lavage with different irrigating solutions to remove adherent bacteria from bone. *J Bone Joint Surg Am.* 2001;83(3):412-9.
14. Bates EJ, Johnson CC and Lowther DA. Inhibition of proteoglycan synthesis by hydrogen peroxide in cultured bovine articular cartilage. *BiochimBiophysActa.* 1985;838(2):221-8.
15. Asada S, Fukuda K, Oh M, Hamanishi C and Tanaka S. Effect of hydrogen peroxide on the metabolism of articular chondrocytes. *Inflamm Res.* 1999;48(7):399-403.
16. Asada S, Fukuda K, Nishisaka F, Matsukawa M and Hamanishi C. Hydrogen peroxide induces apoptosis of chondrocytes; involvement of calcium ion and extracellular signal-regulated protein kinase. *Inflamm Res.* 2001;50(1):19-23.
17. Thomas GW, Rael LT, Bar-Or R, Shimonkevitz R, Mains CW, Slone DS, Craun ML and Bar-Or D. Mechanisms of delayed wound healing by commonly used antiseptics. *J Trauma.* 2009;66(1):82-90; discussion -1.

18. Sanchez IR, Nusbaum KE, Swaim SF, Hale AS, Henderson RA and McGuire JA. Chlorhexidine diacetate and povidone-iodine cytotoxicity to canine embryonic fibroblasts and *Staphylococcus aureus*. *Vet Surg*. 1988;17(4):182-5.
19. Mariotti AJ and Rumpf DA. Chlorhexidine-induced changes to human gingival fibroblast collagen and non-collagen protein production. *J Periodontol*. 1999;70(12):1443-8.
20. van Meurs SJ, Gawlitta D, Heemstra KA, Poolman RW, Vogely HC and Kruyt MC. Selection of an optimal antiseptic solution for intraoperative irrigation: an in vitro study. *J Bone Joint Surg Am*. 2014;96(4):285-91.
21. Damour O, Hua SZ, Lasne F, Villain M, Rousselle P and Collombel C. Cytotoxicity evaluation of antiseptics and antibiotics on cultured human fibroblasts and keratinocytes. *Burns*. 1992;18(6):479-85.
22. Tsukayama DT, Goldberg VM and Kyle R. Diagnosis and management of infection after total knee arthroplasty. *J Bone Joint Surg Am*. 2003;85-A Suppl 1:S75-80.
23. Hood J, Edwards GFS, Cosgrove B, Curran E, Morrison D and Gemmell CG. Vancomycin-intermediate *Staphylococcus aureus* at a Scottish Hospital. *Journal of Infection*. 2000;40(2):A11.
24. Haley CE, Marling-Cason M, Smith JW, Luby JP and Mackowiak PA. Bactericidal activity of antiseptics against methicillin-resistant *Staphylococcus aureus*. *J Clin Microbiol*. 1985;21(6):991-2.
25. Schwechter EM, Folk D, Varshney AK, Fries BC, Kim SJ and Hirsh DM. Optimal irrigation and debridement of infected joint implants: an in vitro methicillin-resistant *Staphylococcus aureus* biofilm model. *J Arthroplasty*. 2011;26(6 Suppl):109-13.
26. Smith DC, Maiman R, Schwechter EM, Kim SJ and Hirsh DM. Optimal Irrigation and Debridement of Infected Total Joint Implants with Chlorhexidine Gluconate. *J Arthroplasty*. 2015;30(10):1820-2.
27. Conroy BP, Anglen JO, Simpson WA, Christensen G, Phaup G, Yeager R, and Gainor BJ. Comparison of castile soap, benzalkonium chloride, and bacitracin as irrigation solutions for complex contaminated orthopaedic wounds. *J Orthop Trauma*. 1999;13(5):332-7.
28. Owens BD, White DW and Wenke JC. Comparison of irrigation solutions and devices in a contaminated musculoskeletal wound survival model. *J Bone Joint Surg Am*. 2009;91(1):92-8.
29. Baird AN, Scruggs DW, Watkins JP and Taylor TS. Effect of antimicrobial solution lavage on the palmar digital tendon sheath in horses. *Am J Vet Res*. 1990;51(9):1488-94.
30. von Keudell A, Canseco JA and Gomoll AH. Deleterious effects of diluted povidone-iodine on articular cartilage. *J Arthroplasty*. 2013;28(6):918-21.
31. Gilotra M, Nguyen T, Jaffe D and Sterling R. Dilute betadine lavage reduces implant-related bacterial burden in a rabbit knee prosthetic infection model. *Am J Orthop (Belle Mead NJ)*. 2015;44(2):E38-41.
32. Shams WE, Hanley GA, Orvik A, Lewis N and Shurbaji MS. Peritoneal lavage using chlorhexidine gluconate at the end of colon surgery reduces postoperative intra-abdominal infection in mice. *J Surg Res*. 2015;195(1):121-7.
33. Penn-Barwell JG, Murray CK and Wenke JC. Comparison of the antimicrobial effect of chlorhexidine and saline for irrigating a contaminated open fracture model. *J Orthop Trauma*. 2012;26(12):728-32.
34. Zhai H, Pan J, Pang E and Bai B. Lavage with allicin in combination with vancomycin inhibits biofilm formation by *Staphylococcus epidermidis* in a rabbit model of prosthetic joint infection. *PLoS One*. 2014;9(7):e102760.
35. Howells RJ, Salmon JM and McCullough KG. The effect of irrigating solutions on the strength of the cement-bone interface. *Aust N Z J Surg*. 1992;62(3):215-8.
36. Patrick S, McDowell A, Lee A, Frau A, Martin U, Gardner E, McLorinan G and Eames N. Antisepsis of the skin before spinal surgery with povidone iodine-alcohol followed by chlorhexidine gluconate-alcohol versus povidone iodine-alcohol applied twice for the prevention of contamination of the wound by bacteria: a randomised controlled trial. *Bone Joint J*. 2017;99-b(10):1354-65.

37. Excellence NICE. Surgical site infections: prevention and treatment (NICE Guideline125) 2019 [Available from: [https://www.nice.org.uk/guidance/ng125/chapter/recommendations - antiseptic-skin-preparation](https://www.nice.org.uk/guidance/ng125/chapter/recommendations-antiseptic-skin-preparation).
38. Petrisor B, Jeray K, Schemitsch E, Hanson B, Sprague S, Sanders D, Bhandari M and the FLOW Investigators. Fluid lavage in patients with open fracture wounds (FLOW): an international survey of 984 surgeons. *BMC MusculoskeletDisord*. 2008;9:7.
39. Englund K and Heidari N. Is There a Role for the Use of Dilute Povidone-Iodine (Betadine) Irrigation or Other Antiseptic Irrigation Solutions During Total Ankle Arthroplasty (TAA) or Other Foot and Ankle Procedures? *Foot Ankle Int*. 2019;40(1_suppl):14s-5s.
40. Hansen E PJ. Eradicate periprosthetic infection with irrigation and debridement. *Orthop Today*. 2012;32(34).
41. Woo YH, Jeong JS, Kim OG and Lee IS. Efficacy of Taurolidine Irrigation in Primary Total Knee Arthroplasty. *Knee SurgRelat Res*. 2018;30(2):142-6.
42. Chundamala J and Wright JG. The efficacy and risks of using povidone-iodine irrigation to prevent surgical site infection: an evidence-based review. *Can J Surg*. 2007;50(6):473-81.
43. Brown NM, Cipriano CA, Moric M, Sporer SM and Della Valle CJ. Dilute betadine lavage before closure for the prevention of acute postoperative deep periprosthetic joint infection. *J Arthroplasty*. 2012;27(1):27-30.
44. Frisch NB, Kadri OM, Tenbrunsel T, Abdul-Hak A, Qatu M and Davis JJ. Intraoperative chlorhexidine irrigation to prevent infection in total hip and knee arthroplasty. *Arthroplast Today*. 2017;3(4):294-7.
44. Olivieri S, Toninelli S, Petrini C, Giorgio A and Oliveri G. Prevention of post-operative infections in spine surgery by wound irrigation with a solution of povidone-iodine and hydrogen peroxide. *Arch Orthop Trauma Surg*. 2011;131(9):1203-6.
45. Kosashvili Y, Backstein D, Safir O, Lakstein D and Gross AE. Dislocation and infection after revision total hip arthroplasty: comparison between the first and multiply revised total hip arthroplasty. *J Arthroplasty*. 2011;26(8):1170-5.
46. Patterson MM. Multicenter pin care study. *OrthopNurs*. 2005;24(5):349-60.
47. Wooldridge AN, Kolovich GP, Crist MK, Mayerson JL and Scharschmidt TJ. Predictors of local recurrence in high-grade soft tissue sarcomas: hydrogen peroxide as a local adjuvant. *Orthopedics*. 2013;36(2):e207-15.
48. Anglen JO. Comparison of soap and antibiotic solutions for irrigation of lower-limb open fracture wounds. A prospective, randomized study. *J Bone Joint Surg Am*. 2005;87(7):1415-22.
49. Bhandari M, Jeray KJ, Petrisor BA, Devereaux PJ, Heels-Ansdell D, Schemitsch EH, Anglen J, Della Rocca GJ, Jones C, Kreder H, Liew S, McKay P, Papp S, Sancheti P, Sprague S, Stone TB, Sun X, Tanner SL, Tornetta P 3rd, Tufescu T, Walter S and Guyatt GH. A Trial of Wound Irrigation in the Initial Management of Open Fracture Wounds. *N Engl J Med*. 2015;373(27):2629-41.
50. Han Y, Giannitsios D, Duke K, Steffen T and Burman M. Biomechanical analysis of chlorhexidine power irrigation to disinfect contaminated anterior cruciate ligament grafts. *Am J Sports Med*. 2011;39(7):1528-33.
51. Burd T, Conroy BP, Meyer SC and Allen WC. The effects of chlorhexidine irrigation solution on contaminated bone-tendon allografts. *Am J Sports Med*. 2000;28(2):241-4.
52. Ostrander RV, Botte MJ and Brage ME. Efficacy of surgical preparation solutions in foot and ankle surgery. *J Bone Joint Surg Am*. 2005;87(5):980-5.
53. Saltzman MD, Nuber GW, Gryzlo SM, Marecek GS and Koh JL. Efficacy of surgical preparation solutions in shoulder surgery. *J Bone Joint Surg Am*. 2009;91(8):1949-53.
54. Hunter JG, Dawson LK, Soin SP and Baumhauer JF. Randomized, Prospective Study of the Order of Preoperative Preparation Solutions for Patients Undergoing Foot and Ankle Orthopedic Surgery. *Foot Ankle Int*. 2016;37(5):478-82.
55. Mankovecky MR and Roukis TS. Arthroscopic synovectomy, irrigation, and debridement for treatment of septic ankle arthrosis: a systematic review and case series. *J Foot Ankle Surg*. 2014;53(5):615-9.

56. Acello AN, Wallace GF and Pachuda NM. Treatment of open fractures of the foot and ankle: a preliminary report. *J Foot Ankle Surg.* 1995;34(4):329-46.
57. Wu SC, Crews RT, Zelen C, Wrobel JS and Armstrong DG. Use of chlorhexidine-impregnated patch at pin site to reduce local morbidity: the ChIPPS Pilot Trial. *Int Wound J.* 2008;5(3):416-22.
58. Ruder JA and Springer BD. Treatment of Periprosthetic Joint Infection Using Antimicrobials: Dilute Povidone-Iodine Lavage. *J Bone Jt Infect.* 2017;2(1):10-4.
59. George DA, Konan S and Haddad FS. Single-Stage Hip and Knee Exchange for Periprosthetic Joint Infection. *J Arthroplasty.* 2015;30(12):2264-70.
60. Riesgo AM, Park BK, Herrero CP, Yu S, Schwarzkopf R and Iorio R. Vancomycin Povidone-Iodine Protocol Improves Survivorship of Periprosthetic Joint Infection Treated With Irrigation and Debridement. *J Arthroplasty.* 2018;33(3):847-50.
61. M. Douw C, Bulstra S, Vandenbroucke J, Geesink R and Vermeulen A. Clinical and pathological changes in the knee after accidental chlorhexidine irrigation during arthroscopy: Case Reports and Review of the Literature. *The Journal of Bone and Joint Surgery British volume.* 1998;80-B:437-40.
62. van Huyssteen AL and Bracey DJ. Chlorhexidine and chondrolysis in the knee. *J Bone Joint Surg Br.* 1999;81(6):995-6.
63. Chhabra R, Pathak A and Ray P. Fatal posterior fossa pneumocephalus due to hydrogen peroxide irrigation of lumbar wound. *Br J Neurosurg.* 2000;14(6):549-51.
64. Kleffmann J, Ferbert A, Deinsberger W and Roth C. Extensive ischemic brainstem lesions and pneumocephalus after application of hydrogen peroxide (H₂O₂) during lumbar spinal surgery. *Spine J.* 2015;15(4):e5-7.
65. Spiriev T, Prabhakar H, Sandu N, Tzekov C, Kondoff S, Laleva L and Bernhard Schaller. Use of hydrogen peroxide in neurosurgery: case series of cardiovascular complications. *JRSM Short Rep.* 2012;3(1):6.
66. Timperley AJ and Bracey DJ. Cardiac arrest following the use of hydrogen peroxide during arthroplasty. *J Arthroplasty.* 1989;4(4):369-70.
67. Henley N, Carlson DA, Kaehr DM and Clements B. Air embolism associated with irrigation of external fixator pin sites with hydrogen peroxide. A report of two cases. *J Bone Joint Surg Am.* 2004;86(4):821-2.
68. Zamora JL. Chemical and microbiologic characteristics and toxicity of povidone-iodine solutions. *Am J Surg.* 1986;151(3):400-6.
69. Kim CS, Kim SS, Bae EH, Ma SK and Kim SW. Acute kidney injury due to povidone-iodine ingestion: A case report. *Medicine.* 2017;96(48):e8879-e.
70. Pietsch J and Meakins JL. Complications of povidone-iodine absorption in topically treated burn patients. *Lancet.* 1976;1(7954):280-2.
71. Lavelle KJ, Doedens DJ, Kleit SA and Forney RB. Iodine absorption in burn patients treated topically with povidone-iodine. *ClinPharmacolTher.* 1975;17(3):355-62.
72. Rath T and Meissl G. Induction of hyperthyroidism in burn patients treated topically with povidone-iodine. *Burns InclTherm Inj.* 1988;14(4):320-2.
73. Shetty KR and Duthie EH, Jr. Thyrotoxicosis induced by topical iodine application. *Arch Intern Med.* 1990;150(11):2400-1.
74. Block SH. Thyroid function abnormalities from the use of topical betadine solution on intact skin of children. *Cutis.* 1980;26(1):88-9.
75. Hoshijima H, Takeuchi R, Sato E and Kikuchi H. Accidental skin burns by fire of an antiseptic agent ignition by the spark of electric cautery. *Masui.* 2010;59(11):1438-40.
76. Toohar R, Maddern GJ and Simpson J. Surgical fires and alcohol-based skin preparations. *ANZ J Surg.* 2004;74(5):382-5.
77. Uetake A, Nakaigawa Y, Kohno Y, Yamada M and Ishii R. Fire caused by a spark of electric scalpel igniting alcoholic antiseptic containing chlorhexidine. *Masui.* 2007;56(6):718-9.
78. Vo A and Bengezi O. Third-degree burns caused by ignition of chlorhexidine: A case report and systematic review of the literature. *PlastSurg (Oakv).* 2014;22(4):264-6.

TRANSPARENCY DECLARATION:

Access to data: This article is distributed under the terms of the Creative Commons Attribution 4.0 International License (<http://creativecommons.org/licenses/by/4.0>), which permits unrestricted use, distribution, and reproduction in any medium, provided you give appropriate credit to the original authors and the source.

UNDER PEER REVIEW