

# Maxillary prosthodontic rehabilitation with Fixed-Removable Partial Denture using extra coronal attachment: A clinical case report

## ABSTRACT:

The rehabilitation of partially edentulous patients is a real challenge for prosthodontists. Attachment retained cast partial dentures can be an excellent option when economic or anatomic conditions do not permit the use of dental implants. They give functionally and esthetically good results. This article describes rehabilitation of a partially edentulous patient with attachment retained hybrid prosthesis.

**Keywords:** Fixed denture, removable partial denture, extra coronal attachment

## Introduction:

Rehabilitation of partial edentulism can be done by several methods out of which one treatment modality is implant retained prosthesis: This option needs a sufficient residual bone, a good general health status and a good economic situation of patients. Fixed dentures may not be recommended when remaining teeth are unable to withstand oral changes or when the edentulism is terminal or extended. [1]

Combined prosthesis constitutes a feasible option if implant retained or fixed prosthesis are not possible and a good alternative to a conventional clasp retained removable partial denture. This type of prosthesis not only provide an esthetic result, also it gives functional advantage of fixed denture that leads to decreased compression of edentulous ridge and enhanced phonetics and mastication. [2]

This clinical case report describes a maxillary prosthodontic rehabilitation with a combined prosthesis: a fixed dental prosthesis designed to interfere with a removable cast framework partial denture (RPD) retained by an extra coronal attachment type Rhein<sup>83</sup>: (RHEIN 83 ATTACHMENT USA)

## Clinical case presentation:

A 52 years old female, with good general health status, was addressed to the Prosthodontics Department at the *FACULTY OF DENTAL MEDICINE, UNIVERSITY OF MONASTIR, TUNISIA*.

She was unsatisfied with her smile and suffered from compromised masticatory function.

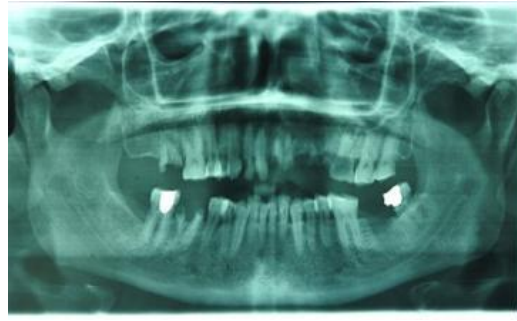

Figure 1: Orthopantomogram before extraction of compromised teeth

Clinical and radiographic examinations (**Fig.1**) revealed lack of posterior support, a little loss of occlusal vertical dimension, an alteration in the occlusal plane and a reduced vertical space. The diagnosis of Kennedy-Applegate class I modified 1 edentulism in the maxillary arch was made. Dental caries -were found in the 11, 12 and 44 (**Fig. 2**) After compromised teeth were extracted and periodontal clinical status established, remaining teeth were: 16, 15, 14, 13, 12, 11, and 27 presented good periodontal support.

Considering the extensive carious lesions, the maxillary right central and lateral incisor, were endodontically treated. Lateral incisor was reconstituted by an inlay core to get best retention value.

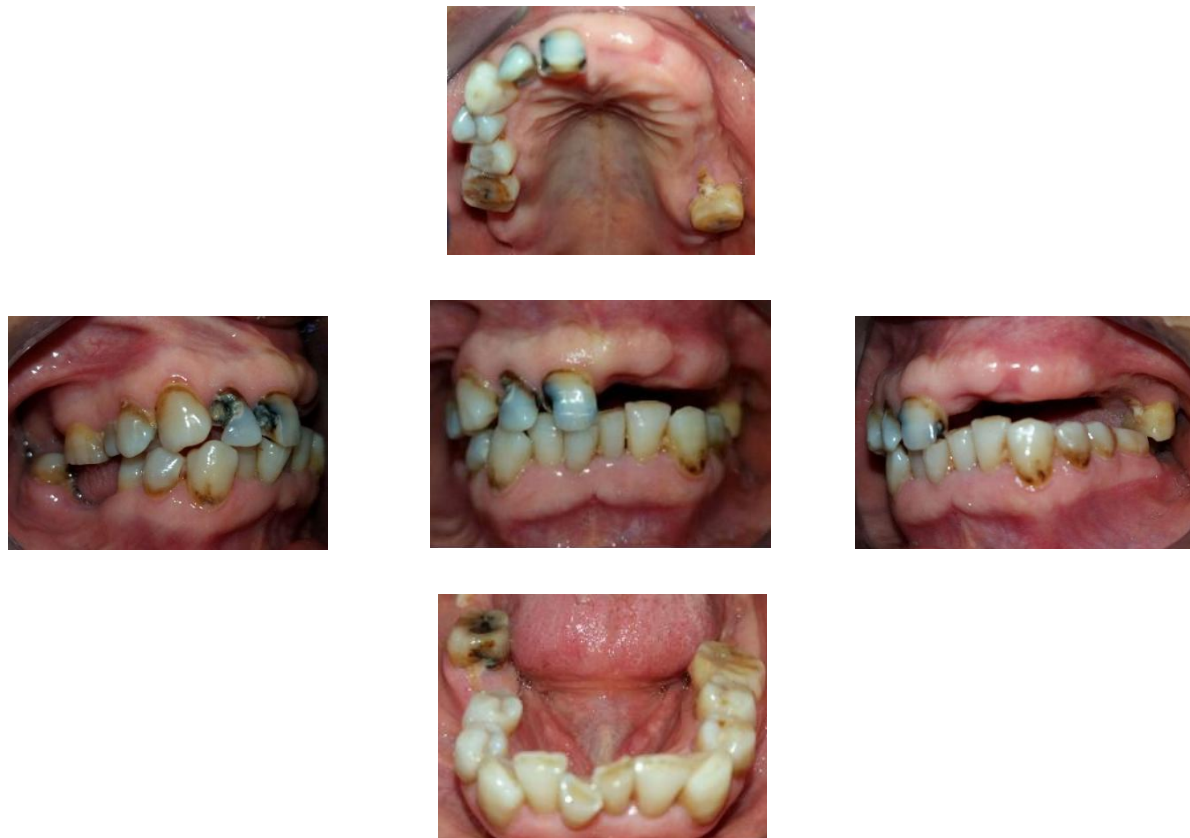

Figure 2 : pretreatment intraoral view

Diagnostic casts were articulated at the correct occlusal vertical dimension, and the treatment was carefully planned taking into account patient's esthetic demand and economical condition. Inter-arch space was adequate for the use of precision attachments.

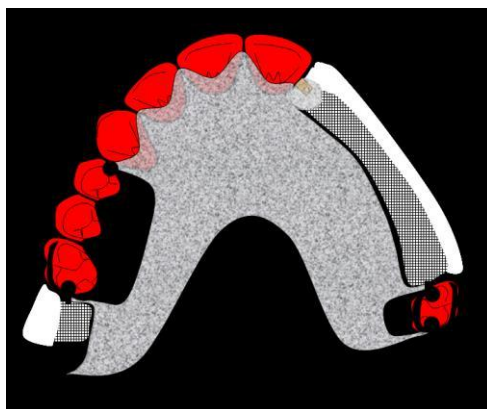


Figure 3: Design of the prosthesis frame

Treatment plan included rehabilitation of maxillary arch with combined fixed/removable prosthesis (using RHEIN<sup>83</sup> precision attachment) (**Fig.3**) and fixed prosthesis in the mandibular arch. It was established and presented to the patient to obtain her consent.

Preparation of all maxillary remaining teeth was done (**Fig. 4, 5**) in order to be restored with fixed metal-ceramic bridge as well as 45 and 47.

Provisional acrylic resin crowns were fabricated and a provisional removable partial denture was created to replace missing teeth. Provisional restorations are an integral part of prosthodontic treatment pertaining to their importance as regard margin fidelity, function, occlusion, and esthetics. [3]

Once the prosthodontic project had been restored by provisional restorations, we started the clinical steps. Gingival retraction was achieved by double wire methods and maxillary Impression was made with wash technique using silicone of low and heavy viscosity. (VANNINI, FRANCE) (**Fig. 6**)

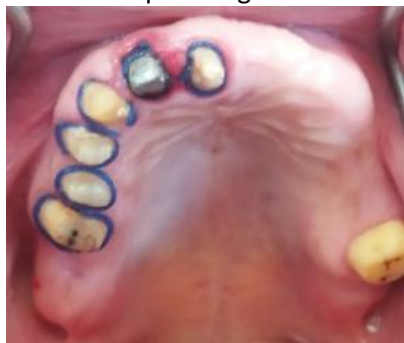

Figure 4: preparation of all remaining maxillary teeth

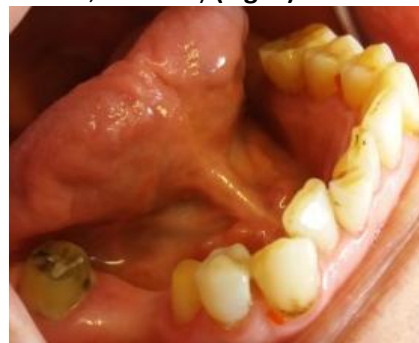

Figure 5: preparation of 45, and 47

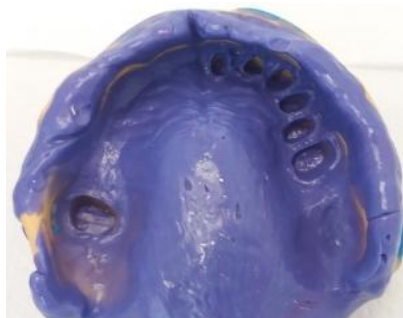


Figure 6: Maxillary impression

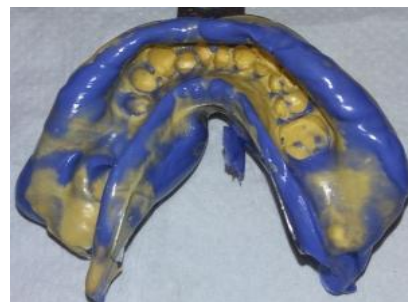

Figure 7: Mandibular impression

The final model was made in gypsum type IV mounted on semi adjustable articulator using a face bow. References are the centric relation and a correct occlusal vertical dimension.

In laboratory, the crowns have been waxed (**Fig.8**) and the Patrice of the attachment was added to the distal surfaces of the abutment using a dental surveyor, lingual to the centre of proximal contour (**Fig.9**). This ensures that the matrice parts do not interfere with esthetic and that fixed elements were made according to an insertion path; in this case it's the vertical path.

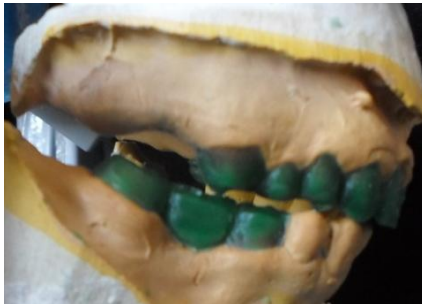

Figure 8: Waxed Crowns

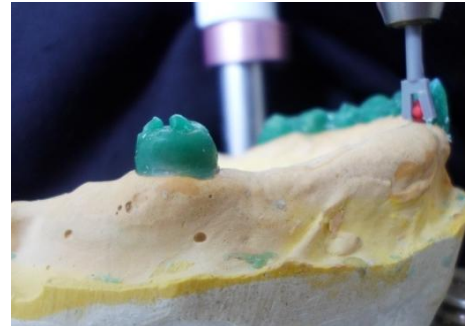


Figure 9: Fixing the patrice of the attachment

In the laboratory the metal framework was made (**Fig.10**) and the extra-coronal attachment attached. The lingual surfaces of the maxillary teeth were flattened to guide the insertion /removal path of the removable partial denture. The metal copings were examined and the marginal limits were verified. An adequate interocclusal distance allowed ceramic application. The unglazed ceramic was clinically tried and returned to the definitive cast. The dental surveyor was again used to check the previously established insertion/removal path of the RPD. Porcelain buildup of fixed denture was completed. (**Fig. 11**)

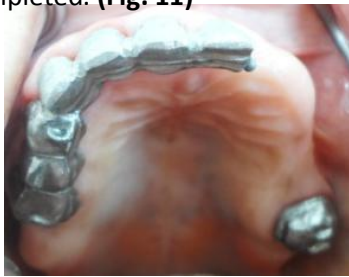

Figure 10: Metal framework try-in

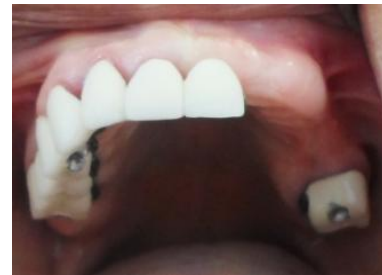

Figure 11: clinical try-in of fixed denture

The fixed component including veneered metal-ceramic crowns and the patrices were tried in the patient mouth (**Fig. 12**) and a pick-up impression with acrylic custom tray and polyether was made. (**Fig. 13**) Polyether (3M ESPE Impregum™ Soft FRANCE) seems to be ideal for a pick up impression it s known for its precision and rigidity.

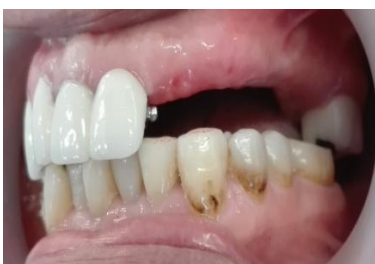

Figure 12: Trying the finished bridge

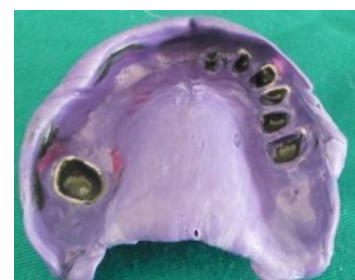


Figure 13: Pick-up impression

Female replica of the attachment was attached to the cast male component (**Fig. 14**). The Fixed partial denture /cast assembly was duplicated with reversible hydrocolloid, and a refractory cast was produced. The RPD framework was cast in a cobalt-chromium alloy and clinically tried to check the fitting. The artificial teeth were selected and positioned using the interim prostheses as form and color reference.

Wax-up of the cast framework was completed on the master cast, (**Fig 15**) and care was taken during the finishing and sandblasting procedures of the casted fixed denture to avoid abrasive wear of the attachment (**Fig. 16**)

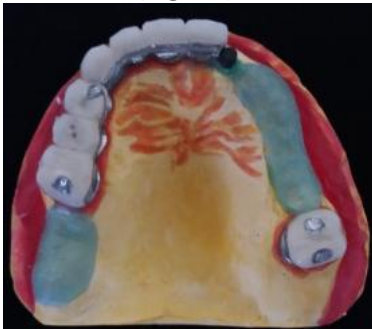

Figure 14: Female replica fixed denture

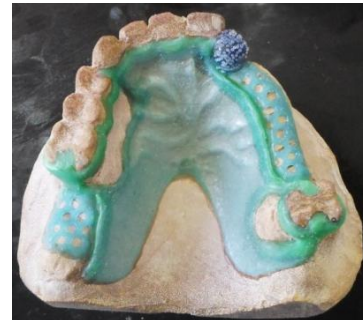

Figure 15: Wax pattern fabrication of cast partial

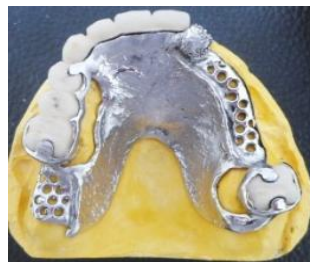

Figure 16: Framework of maxillary cast partial

Maxillomandibular relation was recorded and mounted on semi-adjustable articulator immediately after framework try in. Teeth arrangement was done and wax try in done.

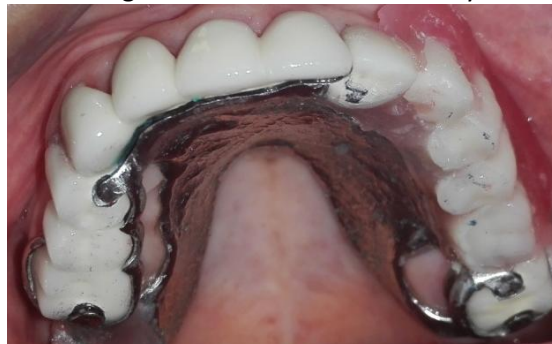

Figure 17: Clinical try-in of RPD framework.

Occlusion and esthetics was verified in patient's mouth. Cast partial denture for maxillary arch was fabricated in heat cure denture base resin.

Female components of attachments were attached to cast partial denture by relining method after verifying occlusal contacts. It's a critical step because an incorrect positioning can result in a wrong fitting of the removable partial denture.

So, crowns had to be cemented and the framework had to be inserted simultaneously.

Retention was found to be satisfactory after insertion of cast partial in patient's mouth. The patient was instructed regarding oral hygiene, how to remove and insert the denture and the time to recall for matrices check, in order to have a good functionality.

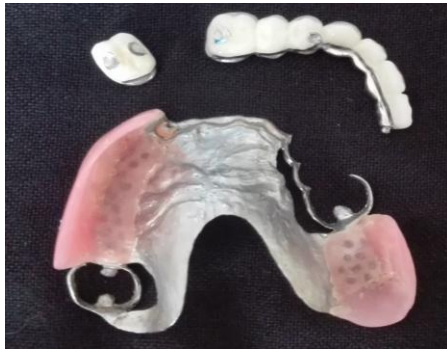

Figure 18: Different parts of the combined prosthesis smile

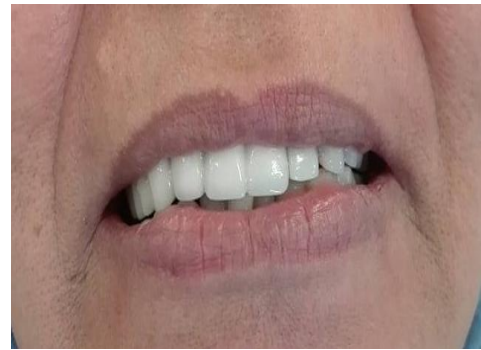

Figure 19: Post-treatment frontal smile

The end result has provided patient satisfaction regarding the combination of fixed dentures and removable skeletal dentures using an extra coronal attachment.

Occlusion stabilization was achieved, improved chewing and good aesthetics.

### Discussion:

The association between fixed and removable partial dentures by means of attachments is an important alternative for oral rehabilitation, particularly when the use of dental implants and fixed denture is limited or not indicated. [1]

Attachment is a connector consisting of two or more parts. They are classified as semi precision and precision devices. In our case, we used a semi precision attachment type Rhein<sup>83</sup> which is cast from calcinable patterns, while in precision attachments, the matrix portions are prefabricated on a metal alloy. [4]

Among the advantages of an attachment-retained removable partial denture are the improvement in esthetics, as clasps are not used in the anterior region, and biomechanics, considering that lower torque is applied to the abutment teeth in a cervical direction during functional movements. Moreover, attachment helps to distribute forces equally between soft and hard tissues. [5, 7]

Attachments may also allow better cross arch force transmission and stabilization than clasps but this is determined by the type of attachment used, the number of guiding surfaces and the design of the framework. [6, 8]

The extra coronal attachment used in our case has a vertical freedom of movement with elastic retention; this elasticity controls the flexure and constructs a resilient and shock absorbing prostheses.[9,10]

Most of the studies have shown that attachment retained cast partial dentures gives better comfort, function, esthetics, less adjustments, protect abutment teeth and easy to clean.[8]

The stress control on abutment is essential for the success of the prosthodontic rehabilitation which is achieved through accurate impression technique, broad coverage, stable denture base, a good shimming and proper selection of attachment. [8, 11]

Finally, long term success requires knowledge of important laboratory techniques, clinical skills; it depends also on biological factors, especially the periodontal ones. [9, 12]

## Conclusion:

Hybrid prosthesis is still a topical treatment despite advances in implantology. To succeed it, particularly in case of global rehabilitation, prosthodontists have to know how to state their indication and respect the chain of implementation. In fact, coordination between the prosthesis laboratory and the clinician is decisive.

In our case, through a composite prosthesis with attachment, we were able to restore masticatory and occlusal functions, namely the anterior guide, phonation and above all to ensure satisfactory esthetics. Maintenance is the key of a good long-term prognosis.

## References:

- 1- Chronopoulos V, Sarafianou A, Kourtis S: The use of dental implants in combination with removable partial dentures: a case report. *J Esthet Restor Dent* 2008; 20:355–364.
- 2- José Mauricio dos Santos Nunes Reis, Luciano Elias da Cruz Perez, Bruna Fernandes Moreira Alfenas and al: Maxillary Rehabilitation Using Fixed and Removable Partial Dentures with Attachments: A Clinical Report.  
*Journal of Prosthodontics* 00 (2013) 1–6 C \_ 2013 by the American College of Prosthodontists
- 3- Regish KM, Sharma D, Prithviraj DR: Techniques of fabrication of provisional restoration: An overview  
*International Journal of Dentistry* 2011(6):134659
- 4- Cristian Schuh, Jovito Adiel Skupien , Mauro Elias Mesko and al  
Resilient Attachments as an Alternative to Conventional Cast Clasp Removable Partial Denture: 3-Year Follow-up. *J Indian Prosthodont Soc (December 2014) 14(Suppl. 1):S273–S278*
- 5- Sakshi Gupta, Sapna Rani, Arpit Sikri, Aditya Kapoor  
Attachment Retained Cast Partial Denture: Conventional and Contemporary Treatment Perspectives  
*International Journal of Oral Care and Research, October-December 2016; 4(4):312-316*
- 6- Sharad Vaidya, Charu Kapoor, Yujika Bakshi, Sonam Bhalla  
Achieving an esthetic smile with fixed and removal prosthesis using extracoronar castable precision attachments  
*The Journal of Indian Prosthodontic Society | Jul-Sep 2015 | Vol 15 | Issue 3*
- 7- Gopinadh Anne, Krishna Kishore Kadiyala H, Ravi Rakesh Dev J, Mohan Krishna Badisa  
Full mouth rehabilitation using fixed partial denture & cast partial denture with attachments and conventional lower denture - A case report  
*International Dental Journal of Students Research; 5(1):25-28*
- 8- GulshanKumarTomar, Mirna Garhnayak,SitansuSekhar Das , Shelly Roy  
Cast Partial Denture Retained Using Precision Attachment – A Case Report  
*IOSR Journal of Dental and Medical Sciences; Volume 15, Issue7 Ver. V (July 2016), PP 94-99*
- 9- Agripina Zaharia, Aureliana Caraiane, Corina Ștefănescu, Rodica Murineanu and al  
Fixed Dentures Combined with Removable Dentures Retained with Extracoronar Attachments  
*Ovidius Dentistry Journal, vol. 1, no. 1, 2014*

10- S. Makkar, A. Chhabra, and A. Khare, "Attachment retained Removable partial denture: a case report, International Journal of Computing and Digital Systems, vol. 2, no. 2, pp. 39–43, 2011.

11- Naveen Gupta, Abhilasha Bhasin, Parul Gupta, and Pankaj Malhotra Combined Prosthesis with Extracoronar Castable Precision Attachments; Case Reports in Dentistry Volume 2013, Article ID 282617, 4 pages

12- D'Incau E, Séguéla V Prothèse composite maxillaire et prothèse fixée mandibulaire.  
Démarche thérapeutique pour un traitement global.  
Cah Prothèse 2008;143:13-24.