

Original Research Article

ASSESSMENT OF THE FEMORAL NECK-SHAFT ANGLES OF ADULTS IN NIGERIA: ESTABLISHING AN AGE AND GENDER STRATIFIED REFERENCE VALUES.

ABSTRACT

Background: The femoral neck-shaft angle (FNSA) has essential roles in the diagnosis of hip pathologies such as femoral neck fractures, developmental dysplasia of the hip and coxa vara, and in the templating of implants and prosthesis for surgical fixation of femoral neck fractures and arthroplasties for hip pathologies. Most studies on the FNSA were done in western countries, and current hip implants in use are based on these studies. Since anthropometric measurements differ among races, it is possible that the FNSA might be different in Africans compared to the Caucasians.

Aim: This study aims to establish normal FNSA for adults in Nigeria stratified by age and gender.

Method: This work was a cross-sectional study. We examined the pelvic x-rays of 75 patients, 30 males and 45 females, with no hip pathology. We also collected relevant biodata such as age, gender, weight and height. The ages of the subjects were categorized in a 10-year grouping from 20 to 99 years. The body mass index (BMI) was calculated for each participant, and each subject was classified as normal weight, overweight or obese based on the BMI value. The FNSA was measured with a Goniometer both for the right and left side. The values of the FNSA was compared for both genders and the age categories. We also compared the mean FNSA for the right and left sides, and assessed for significant differences in the FNSA among the groups of the body mass index.

Results: The mean age of the participants was 64 years \pm 16.93 years. The mean FNSA was $131.04^{\circ} \pm 3.86$, with a range of 20° ($120 - 140^{\circ}$). Males had a mean FNSA of 131.43° compared to females who had a mean FNSA of 130.78° , although the difference was not statistically

significant. Also, no significant differences in the mean FNSA were seen concerning age categories, sides and BMI groups.

Conclusion: The mean FNSA of adults in this study is different from the western textbook value of 125° . This should be borne in mind when manufacturing hip implants and prostheses for domestic use.

Keywords: Femur, Neck-Shaft angle, Adults, Nigeria.

INTRODUCTION

The femoral neck-shaft angle (FNSA) is formed by the intersection of the mid-axis line of the femoral neck and the mid-diaphyseal line of the femoral shaft. The normal FNSA in standard Anatomy and Orthopaedic textbooks is 160° at birth, decreasing to 125° in adults.^{1,2} The decrease in the FNSA as age increases is believed to be caused by weight bearing across the hip joint as the child starts mobilizing.³⁻⁵ The reduction in the FNSA increases the abductor muscles lever arm, thereby reducing the hip joint reaction force and making the abductors of the hip more efficient during gait. This observation is supported by the fact that there is minimal change in the FNSA from the neonatal value in children who do not resume normal weight bearing.^{4,5} Such high FNSA occurs in cases such as Developmental dysplasia of the hip (DDH), Cerebral palsy and Slipped upper femoral epiphysis (SUFE).

Knowledge of the normal FNSA has important ramifications in Orthopaedic Surgery. A displaced femoral neck fracture frequently causes a change in the FNSA. Also, diagnosis of congenital hip disorders such as DDH, Coxa vara and valga, and developmental problems such as SUFE considers the FNSA. When the FNSA is less than 120° , it is referred to as coxa vara and when greater than 140° it is coxa valga.² It has been hypothesized that increased FNSA increases the lever arm of the body weight acting on the greater trochanter during a fall on the side, thereby increasing the risk of a femoral neck fracture.⁶ The estimation of the FNSA is also crucial during templating for fixation of hip fractures and arthroplasties for hip pathologies. Implants such as the Dynamic Hip Screw (DHS), 135° blade Plate, Proximal Femoral Plate (PFP) and Proximal Femoral Nail (PFN) have an in-built angle to match the normal FNSA.

However, most studies on the normal FNSA were done in Caucasians, and current hip implants and prostheses are based on the values from such works. Anthropometric parameters show racial variations, and it is expected that the FNSA may vary in different races. Studies have revealed considerable differences among diverse populations.^{7,8} In his survey of more than 30 different populations, Anderson noted that people with a more sedentary lifestyle and increased mechanization have a higher FNSA than those with more active and non-mechanized life.⁸ If this is true, then it is expected that Africans, with occupations that warrant increased mobilization and higher transfer of forces across the hip joints, will have a lower FNSA than the largely mechanized Caucasians.

Few studies have been done locally to estimate the value of the normal FNSA in Nigeria.⁹⁻¹¹ However, none of these works attempts to stratified the FNSA according to the age groups, and to investigate the association between obesity and the FNSA. The current work is aimed to fill in this gap by estimating the FNSA in adults in the South-Eastern part of the country, creating a reference source according to gender and age categories. It is hoped that the findings of this research will aid implant manufactures to consider the racial variation, if a significant one exists, when designing hip implants for use in Africans in general and Nigeria, the largest African population, in particular.

SUBJECTS AND METHODS

This work was a cross-sectional study conducted at the radiography department of the National Orthopaedic Hospital in Enugu, South-East Nigeria. The hospital is a tertiary centre and the regional centre for Orthopaedics and trauma, receiving referrals from the entire South-East geopolitical zone and some parts of North-Central region. The study was conducted for 12 months, starting from November 2015 to October 2016. Ethical approval was obtained from the institutional Ethics committee and written informed consent was gotten from each subject. The study protocol was explicitly explained to the radiographers, and a research assistant collected the biodata, the weight and the height of the participants.

To calculate the sample size for this study, we scrutinize all AP pelvic x-rays that were done in the radiography department within the preceding year. Out of a total number of 827 AP pelvic x-

rays done 42 were free of any identifiable pathology. This gives a proportion of normal AP pelvic x-ray of 5.1%. Substituting this value into the equation, $n = z^2p(1-p)/d^2$, gives a sample size of 75 subjects. Here, d is precision, which was set at 5%.

All the patients coming for a pelvic x-ray within the study period were approached, and the study explained to them. The inclusion criteria were adults presenting to the radiology department for pelvic x-rays whose film indicated the absence of any pathology in both hip joints and the proximal femur. Both the radiologist and the Orthopaedic surgeon has to agree on the “normality” of the x-ray film. Two of the researchers measured the FNSA independently to ensure excellent reliability and the average measurement was taken. Exclusion criteria include hip pathologies, including fractures, dislocations, SUFE, Perthes disease, Osteoarthritis. Those that signed the consent form and met the inclusion were weighed, and their heights were measured.

Patients were supine, and the film-focus distance (FFD) was 100cm. All x-rays are digital, and magnification was set at 100%, with the beam centred on the pubic symphysis. The lower limbs were internally rotated such that the medial border of the toes abuts each other; this action neutralizes the 10^0 to 15^0 anteversion of the proximal femur. The mid-axis line of the femoral neck was determined by measuring the width of the neck and noting the central point at a proximal and a distal end of the neck and then joining these two central points with a straight line. The process was also used to draw the mid-diaphyseal line of the femoral shaft. The angle subtended by the intersection of the neck mid-axis line and the shaft mid-diaphyseal line is the femoral neck-shaft angle, see figure 1.

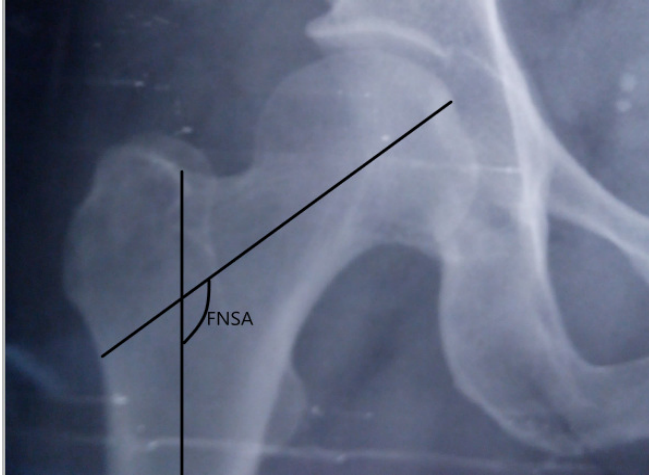


Figure 1 The Femoral Neck Shaft Angle (FNSA) is formed by the intersection of the neck mid-axis and shaft mid-diaphysis line.

We represented the data with the means and standard deviations for continuous variables and as frequencies for categorical variables. An independent samples t-test was used to test the difference in the mean FNSA between males and females, while a paired samples t-test was used to test the difference in the mean FNSA between the right and the left side of each subject. We ran a Pearson's correlation analysis between the subjects' age and the FNSA. All tests were 2-tailed, and a p-value of less than 0.05 was considered significant.

RESULTS

We examined 150 proximal femoral x-rays in 75 patients, 30 males (40%) and 45 females (60%). The mean age of the participants was 64 years \pm 16.93 years. Table 1 summarizes the age categories of the subjects, with their respective mean FNSA.

Table 1 The age categories of the participants and the mean FNSA.

<i>Age category(years)</i>	<i>frequency</i>	<i>Mean FNSA (°)</i>	<i>SD (°)</i>
20-29	7	132.3	4.42
30-39	1	130.0	-
40-49	4	134.3	4.92
50-59	23	130.4	4.14

60-69	25	131.7	3.08
70-79	11	130.0	4.00
80-89	4	128.5	3.51

The mean FNSA was $131.04^{\circ} \pm 3.86$, with a minimum value of 120° and a maximum value of 140° . Males have a mean FNSA of $131.43^{\circ} \pm 3.60^{\circ}$ while females have a mean value of $130.78^{\circ} \pm 4.02^{\circ}$. However, this difference is not statistically significant ($P = 0.48$). Also, the values of the mean FNSA between the right and the left side do not significantly differ. The right side has a mean value of $131.07^{\circ} \pm 3.87^{\circ}$, while the left side has a value of $131.04^{\circ} \pm 3.86^{\circ}$ ($P = 0.62$).

Although there is a general decrease in the FNSA as one age increases, the correlation between the age of the subjects and the FNSA is weak ($r = -0.19$, $P = 0.11$). Figure 2 is the scatter plot showing the relationship between age and FNSA. This weak association is further confirmed by the finding of a non-significant difference in the mean FNSA among the different age categories ($P = 0.27$). The majority of the study participants were overweight, see figure 3. However, there was no significant difference in the mean FNSA among the three categories of BMI. The categories of the BMI were normal weight ($18.5 - 24.9 \text{ kg/m}^2$), overweight ($25 - 29.9 \text{ kg/m}^2$) and obese ($>30 \text{ kg/m}^2$).

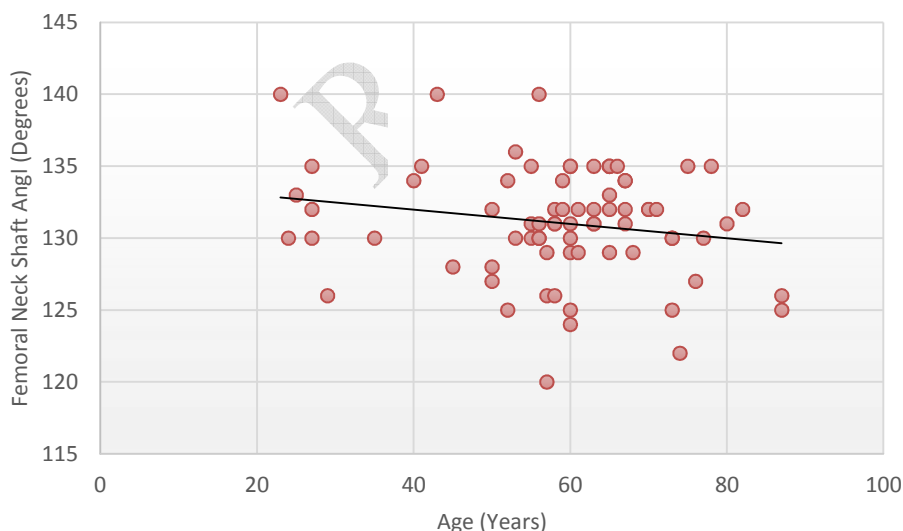


Figure 2 The Scatter diagram showing the weak negative correlation between age and FNSA.

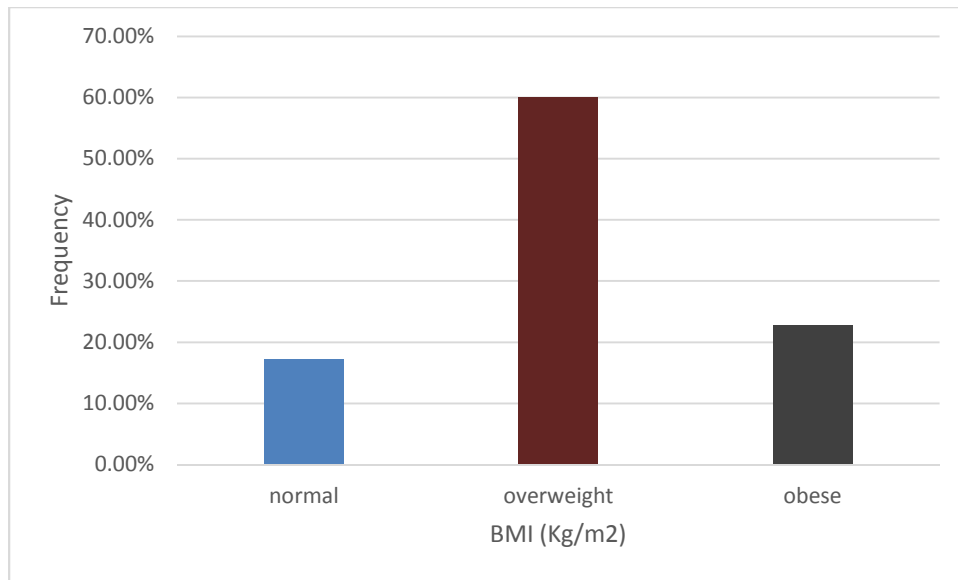


Figure 3 The distribution of the subjects based on their BMI.

DISCUSSION

This study, like other studies done in Nigeria, has found a higher value of the FNSA than the textbook value of 125⁰. The mean FNSA in this study was 131.04⁰, with males having a value of 131.43 and females 130.78, which is similar to the value of 132⁰ found by Adekoya in Lagos, South-west Nigeria.⁹ However, these values differ from the finding by Tahir et al. in Northern Nigeria. He found a mean value of 136.7⁰ in males and 126.65⁰ in females.¹¹ This difference may be related to the lifestyle of the studied population. The present study and that done in Lagos were done in the cities characterized by individuals who live a primarily urbanized life while the northern community are comprised of mixed people, mostly nomads and an agrarian lifestyle.

Other studies that were done in other African countries also showed similar values of the FNSA. Gilligan et al. found values of 132.5⁰ in Senegal, 132.3⁰ in Chad, 130.8⁰ in Mali and 130.5⁰ in Sudan.¹² There is a consistently higher value of the FNSA in the tropical countries compared to Caucasian and Asian values, see table 2. If the hypothesis that increased loading across the hip joint will result in lower FNSA, then could it be possible that the higher prevalence of obesity in the western world compared to Africa be responsible for the lower FNSA among Caucasians.⁹ However, this study has shown no difference in the mean values of the FNSA among the categories of BMI.

Table 2 Comparison of the mean FNSA among the different populations of the world.^{8,10,14-19.}

<i>Serial no</i>	<i>Author</i>	<i>Year</i>	<i>Sample size</i>	<i>Population</i>	<i>FNSA*</i>	<i>SD</i>
1	Rubin	1992	32	French	122.9 ⁰	7.6 ⁰
2	Yamaguchi	1993	60	Japanese	128.4 ⁰	0.9 ⁰
3	M	2004	446	French	132.8 ⁰	4.4 ⁰
4	Lequesue Liang J	2009	56	Chinese	126.2 ⁰	7.1 ⁰
5	HD Atkinson	2010	100	British	M= 129.0 ⁰ F= 128.0 ⁰	-
6	M Inam	2011	100	Pakistan	134.0 ⁰	5.6 ⁰
7	Adekoya C	2013	132	Nigerian	132.0 ⁰	3.9 ⁰
8	Present study	2016	75	Nigerian	131.0⁰	6.0⁰

*= All studies utilized either x-ray or computerized scan radiography.

The weak association between the BMI and the FNSA has also been noted in the study done by Filiz, who found no positive correlation between the two variables.¹³ Therefore, it seems that factors other than the BMI are responsible for the higher FNSA among Africans. It is also possible that the techniques of measurement might also explain some of the variations in the FNSA. Some studies utilized cadaveric femora, while others used radiography. Furthermore, measurements on the radiographs may also be done manually or using machine calibrations. All these might affect the values; however, there is no doubt that there is a racial difference in the FNSA.

Males were found to have a higher mean value of the FNSA than females, although not significant. This is consistent with that found in other studies.^{8,10,20} However, Akbar found a significant gender difference in the FNSA.²¹ Reasons that have been attributed for the lower FNSA in females include more proximal femoral inclination as the pelvis widens in the female. This is akin to the wider carrying angle at the elbows in the females due to the gynaecoid shape of the pelvis. The greater bicondylar angle and the generally short femora in the female has also been cited as reasons for the smaller FNSA.²⁰

We did not observe any significant differences in the mean FNSA between the right and the left sides of the body. Adekoya et al. and Gilligan et al. found a significant difference in the right and

left FNSA and attributed this to leg dominance probably.^{9,12} However, other works failed to demonstrate any systematic variation between the two sides.^{10,22} However, it is unclear whether leg dominance is as vital in influencing musculoskeletal development as hand dominance is. The reason is that normal gait requires an almost equal excursion and activation of both lower limbs, and a difference in greater activation of the dominant leg is doubtful.

Although increasing age led to a gradually decreasing FNSA, the correlation between age and FNSA was weak. The FNSA decreased from 160 in the neonate to the adult value at late adolescence as part of natural development.^{1,2} It appears that there is still a reduction as age increases, but it is insignificant. We hypothesize that this decrease might be due to the overall loss in bone mineral density as one ages. Just like what is obtainable in the vertebrae in old age, the proximal femur, experiencing a considerable load (the body weight) throughout life, may undergo plastic deformation through its lifetime.

CONCLUSION

Our study has re-echoed what other local studies have found; that the FNSA of Africans differs from the Caucasians and Asians. This information will be vital to the hip surgeon during templating for such surgeries as proximal femoral osteotomies and fracture fixation in an African patient.

CONSENT

A written informed consent was obtained from each subject.

REFERENCES

1. Chummy S.S. Last's Anatomy: Regional and Applied. 12th Edition. UK, Elsevier Ltd, 2011: 170.
2. Solomon L, Warwick D, Nayagam S. Apley's Systems of Orthopaedics and Fractures, 9th ed, United Kingdom, Hodder Arnold, a Hachette UK company, 2010: 843-859.
3. Morscher E. Development and clinical significance of the anteversion of the femoral neck. *Reconstr. Surg. Traumat.* 1967; 9:107-125.

4. Houston CS and Zaleski WA. The shape of vertebral bodies and femoral necks in relation to the activity. *Radiology* 1967;89: 59-66.
5. Houston CS. The radiologist's opportunity to teach bone dynamics. *Journal of the Association of Canadian Radiologists* 1978; 29:232-8.
6. Panula J. Surgically treated hip fracture in older people With Special Emphasis on Mortality Analysis, University of Turku, Turku, Finland [online] 2010. Available from URL:<https://www.doria.fi/bitstream/handle/10024/62845/AnnalesD907Panula.pdf?sequence=1>
7. Amith R. Analysis of the anteversion and neck shaft angle in dry femora of South Indians. Dissertation submitted to the Rajiv Gandhi University of Health Sciences, Karnataka, Bangalore. 2012. p. 5.
8. Anderson JY and Trinkaus E. Patterns of sexual, bilateral and interpopulational variation in human femoral neck-shaft angles *J. Anat* 1998;192: 279-85.
9. Adekoya-Cole TO, Akinmokun OI, Soyebi KO, Oguche OE. Femoral neck shaft angles: A radiological anthropometry study. *Niger Postgrad Med J* 2016; 23:17-20.
10. Nwoha PU. The Collodiaphyseal angle of the femur in adult Nigerians. *Afr J Med Med Sci* 1991; 20:143-7
11. Tahir A, Hassan AW, Umar IM. A study of the Collodiaphyseal angle of the femur in the North-Eastern sub-region of Nigeria. *Niger J Med* 2001; 10:34-6.
12. Gilligan I, Chandraphak S, Mahakkanukrauh P. Femoral Neck-Shaft Angle in Humans: Variation Relating to Climate, Clothing, Lifestyle, Sex, Age And Side. *Journal of Anatomy*. 2013;223(2):133-151.
13. HarvaT C, Meriheryavuz, M C. Comparison of femoral geometry among cases with and without hip fractures, *Yonsei Medical Journal* 2004;45(5): 901-907.
14. Yamaguchi O. A radiologic study of the hip joint in cerebral palsy. *Journal of the Japanese Orthopaedic Association* 1993; 67:1-11.
15. Atkinson HD, Johal KS, Owen CW, Zadow S, Oakeshott RD. Differences in hip morphology between the sexes in patients undergoing hip resurfacing. *Journal of Orthopaedic Surgery and Research* 2010; 5:76.

16. Rubin PJ, Leyvraz PF, Aubaniac LM, Argenson JN, Esteve P and de Rougin B. The morphology of the proximal femur. *Journal of Bone and Joint Surgery* 1991;74(B):28-32.
17. Lequesne M, Malghem J, Dion E. The normal hip joint space: Variations in width, shape and architecture on 223 pelvic radiographs. *Ann Rheum Dis* 2004; 63:1145–51.
18. Liang J, Li K, Liao Q, Lei G, Hu Y, Zhu Y, et al. Anatomic data of the proximal femur and its clinical significance. *J Cent South Univ (Med Sci)* 2009 Aug;34(8):811-4.
19. Inam M, Satar A, Arif M, Shabir M. Proximal femoral geometry of Khyber Pakhtoonkhwa (KPK) population. *The journal of Pakistan Orthopaedic Association* 2011 Jun;23(2).
20. Panula J, Savola M, Jaatinen P T, Aarnio P, Kivelä S I. The impact of proximal femur geometry on fracture type – a comparison between cervical and trochanteric fractures with two parameters. *Scandinavian Journal of Surgery*, 2008; 97: 266–271.
21. Akbar W. And Kalimullah, *Biomedica A Radiographic Study of Neck Shaft Angle in Population of Mardan Region, Khyber Pukhtonkhwa – Pakistan*. *Biomedica* 2015 Jun; 31(2):108-114.
22. Jing G, Yia-wei S, Xiao S; Mechanical analysis and computer simulation of the structure of femoral neck [online]. 2006 [cited April 2014]. Available from URL <http://asbweb.org/conferences/2006/pdfs/269.pdf>.