

---

## **Mandibular osteomyelitis in concurrence with Psoriasis: A rare case report and literature review**

Hong He<sup>\*1,2</sup>, Xinyu Xia<sup>1,2</sup>, Jinhan Zhou<sup>1,2</sup>, Xiaotong Deng<sup>1,2</sup>, Kejie Lu<sup>1,2</sup>, Er Li<sup>3</sup>, and  
Qingzhu Wu<sup>3</sup>

<sup>1</sup>The Affiliated Stomatology Hospital, Zhejiang University School of Medicine, Hangzhou, China.

<sup>2</sup>Key Laboratory of Oral Biomedical Research of Zhejiang Province, Hangzhou, China.

<sup>3</sup>Haishu Stomatology Hospital, Ningbo, China.

### **\*Correspondence**

Hong He

<sup>1</sup>The Affiliated Stomatology Hospital, Zhejiang University School of Medicine

<sup>2</sup>Key Laboratory of Oral Biomedical Research of Zhejiang Province

E-mail: [honghehh@zju.edu.cn](mailto:honghehh@zju.edu.cn)

**Funding:** This study was supported by the Co-construction Program WKJ-ZJ-1623 from the Provincial Bureau and National Commission of Hygiene & Health in China, the Nonprofit Specific Fund 201502018 from the National Hygiene and Health Commission of China, and the Education Reform Program (yxyb20172030) from the School of Medicine of Zhejiang University in China. National Key R&D Program of China 2016YFC 0902702

**Conflicts of interest:** None.

## ABSTRACT

Mandibular osteomyelitis in patient with psoriasis is an uncommonly clinical manifestation while there is an increasing number of reports and studies on involvements of stomatology in psoriasis, especially a death of a patient via or not via Allogeneic bone marrow transplantation has never been reported. To review the management and possible mechanisms in pathogenesis and treatment of psoriasis, as well as the relative involvements between stomatology and psoriasis the typical case with pictures and files is reviewed and literatures are collected. We keep the knowledge that psoriasis is either a primary keratinocyte disorder or an immunocyte-mediated chronic skin inflammatory disease while bone marrow is under suspected for immunopathogenesis. More association of stomatologic conditions with psoriasis is emerging. Conclusively, allogeneic BMT and new knowledge is worth to be stressed by both stomatological and dermatological doctors. Further insights of this kind of autoimmunologic disease are under its developing.

## Key Words

Psoriasis, immunopathogenesis, keratinocyte disorder, osteomyelitis

---

## INTRODUCTION

Psoriasis is a common while enigmatic inflammatory skin disorder that affects a population of approximately 2-3% of the world<sup>1-2</sup>. Development of Osteomyelitis in mandible of patient with psoriasis is an uncommonly clinical manifestation that has received little attention ever, but now is gaining some increasing care among the dermatological and stomatological literatures for a reason of the undiscovered essence in pathogenesis mechanism and the development of Allogeneic bone marrow transplantation (BMT) as a positively effective therapeutic strategy<sup>3,4</sup>.

Despite the elucidation of many aspects of psoriasis pathogenesis, some puzzling questions remain to be answered. A major question currently debated is whether psoriasis is a primary abnormality of the epidermal keratinocyte, or whether it is a reflection of the imbalance of immunocytes derived from bone marrow<sup>1</sup>. The authors here are devoting to the reviewing and discussing an irregular case from east China and relevant new knowledge about Psoriasis.

## MATERIALS

A 27-year-old man had been admitted to the affiliated hospital school of medicine Zhejiang University for two times, respectively during 8-28<sup>th</sup> September 2007 and from 17<sup>th</sup> November 2007 to 30<sup>th</sup> January 2008, diagnosed as Psoriasis, he had a history of 13

---

years of ankylosing spondylitis, infection in the left cheek, anemia, and chronic active hepatitis B. He died in July, 2009.

### *First time admission*

Due to a 2-year history of repeatedly systemic scaly erythema with a 2-month duration of accelerated recurrence, he was admitted to the department of Dermatology in our hospital during September 8<sup>th</sup> to 28<sup>th</sup> 2007. During the past 2 years he suffered from the scaly erythema in the forehead and scalp, accompanied with mild itching, which gradually spread to the body trunk, limbs, and face. He also suffered from recurrent rashes, without fever, chills, joint pain, or mouth ulcer. After treated with topical steroid ointment and vitamin internal medicine in his local hospital, he recovered a little. However, he was attacked by these again two months ago, with rashes on his whole body. And there was no effect even after taking above medicines. What were worse, rashes and itching increased significantly in the past 2 weeks. So, he was enrolled as an inpatient to receive a further therapy being diagnosed as “regular Psoriasis”. Additionally, he received two times of Abscess incision surgery in his left face one month ago, and then was extracted his left first mandibular molar 2 weeks ago. There were swelling and pain in his left face 2 days ago, with moderately limited mouth opening that was only 27mm width, he also got a small bug shape swelling of 1.5cm in the skin, yellow and soft of left check (Fig. 1). Fistula and pus discharge could be seen in the oral vestibular of the left mandibular molar. Besides, he had got anemia for more than 10 years and hepatitis B over 20 years, with a normal liver function that was

checked regularly. After incision and drainage treatment as well as anti-infective medicine, he recovered much with reduced swelling.

Laboratory data revealed the following values: PL73000/ml (normal values, 100000-300000/ml), Hb6.8g/dl, RBC $2.44 \times 10^{12}$  /, WBC $5.7 \times 10^9$  /, CRP97.5mg/L, N (Neutrophils) 67.5%, HBV-DNA  $4.13 \times 10^6$  copy/ml. Plasma fibro Fibrinogen (FBG) 6.4. Melt beads pro 3.93. Iron transferrin protein receptor 6.92 mg / l. Albumin ↓, Albumin to Globulin 0.92 (normally 1.50-2.50), Vit B12 152 (normally 187-1059pg/ml), Iron transferrin protein 1.68 (normally 2.12-3.60g / l). Report for his bone marrow aspiration was: iron deficiency anemia manifestation of bone marrow. Report for enhanced spiral CT scan of his Jaw was: left side muscle cystic lesion, a large cyst with infection probably (Fig. 2). Panoramic X-ray showed an osteomyelitis in his left mandible (Fig. 3). Ultrasonic B for his left cheek reported: the left cheek and left mandible shallow fluid exudate. Pancreatic splenic Ultrasonic B and EKG reported: no obvious abnormalities.

### *Second time admission*

After the remission of his last psoriasis, he was admitted again into our hospital for an over ten-day accelerated recurrence during 17<sup>th</sup> November, 2007 till to 30<sup>th</sup> January, 2008, after no therapeutic effect from his local Shengzhou City People's hospital. His clinical signs and symptoms were fever, joint pain, and increased erythema. The swelling and purulent secretion in his left cheek brought him a 10mm width mouth opening. Report of his ultrasonic B from Shengzhou City People's hospital was:

increased size of liver resulted from chronic liver disease. CT scan reported a probable left Mandible Osteomyelitis. Inpatient CT in our hospital reported a probability of chronic infectious diseases in left mandibular body and ramus. Via Bone marrow aspiration, the graphic report for cellular morphological examination of bone marrow was "Secondary increase in plasma cells. Poor platelet generation ability of megakaryocytes." And the biopsy report for BB plastic embedding of bone marrow was "Reactive Increase in plasma cells and deficiency of iron in bone marrow". Result of purulent secretion culture was MRSA (Staphylococcus aureus) +. Due to poor spirit, sleep quality, and general condition not suitable for surgery, he received local irrigation and rinse treatment with Clindamycin from the department of stomatology.

Following values were his Laboratory data: GPT alanine 403u / l, GTT aspartate 407u / l. PL34000-59000 / ml, Hb5.8g/dl, correspondingly diagnosis was made as Immune Secondary Anemia. Albumin↓ 3.47g/dl, ESR130mm / h. PT ↑. Prothrombin time activity ↓. Fibrinogen (FBG) ↑. D-dimer ↑ 754 (0-330). CRP ↑ 129mg / L. Anti O 677iu/ml. IgG ↑, IgA ↑, C3 ↑. NK, T (-). CD4/CD8 0.4. HBV-DNA (-).

This time he was treated with medicines including YiSaPu (rhTNF II R-Ab fusion pro), vancomycin, tinidazole, TiKaoKongNing Injection, anti-inflammatory MeiLin injection, hepatoprotective, DiXian and Naixin used as stomach protection acid suppression, Futalin and Vitamin A capsules, low dose of prednisone (30mg/d) as symptomatic anti-inflammatory and rash treatment, and methods including Hyperbaric oxygen, blood transfusion (Albumin, RBC, Platelet PL, and fresh plasma). LeFanMing

---

Vc and SaiWei injections were used to improve immunity.

## RESULTS

In these two times of admission, after treatments he got certain such remission as rash subsided, itching and fever disappearance, and decreased swelling in his left cheek, thus each time he was discharged from hospital. However, remission was temporal, recurrence and anemia exhaustion led to his death in 2009 only after another one year in his suffering history.

## DISCUSSION

The patient had Psoriasis and suffered from it many times. Debut at any age, vast majority under 50 years old, Psoriasis is a papulosquamous skin disease with several phenotypes. The most common is vulgaris (chronic plaque), approximately 80% to 90%, usually symmetrically and most frequently at the abdominal elbows and knees, scalp, and the lumbosacral region. Secondly as nail lesions. Erythroderma is its unusual but serious form attacking entire body<sup>5</sup>.

This patient died from anemia soon after 4 years of his psoriasis. However, in Tamas's<sup>4</sup> report, the psoriasis of his patient who received the Allogeneic BMT for his severe aplastic anemia which disappeared in no time after Allogeneic BMT was managed well and has kept the patient remaining in remission over the 10 years of follow-up.

As T cells are important in the pathogenesis of psoriasis<sup>1</sup>, we might expect that BMT have a potentiality to alter the course of the disease development. Evidence

---

supporting such a phenomenon comes from experimental mouse models<sup>2</sup>. There are also some clinical case reports demonstrating the long-term resolution of psoriasis post Allogeneic BMT<sup>3,4</sup> and the relapse of psoriasis post Autologous BMT<sup>6</sup>.

Tamas<sup>4</sup> described two psoriatic patients. The above mentioned one received Allogeneic BMT who recovered from his psoriasis completely and has been in remission for more than 10 years. The second patient received Autologous BMT whose psoriasis returned after 21 months of remission. Tamas indicated that, as complete donor chimerism was proved on day 342, it was more likely that a substantial alteration in patient's cellular immunity was the reason for the complete resolution of the first one's psoriasis.

There are two main hypotheses currently holding a view on the psoriasis pathogenesis either as a primary keratinocyte disorder or as an immunocyte-mediated chronic skin inflammatory disorder. There is more medication-related rather than Psoriasis-related osteomyelitis reported<sup>7</sup>. Basically, since Schon, more researchers<sup>2,8</sup> also indicated an involvement of bone marrow in the immunopathogenesis of psoriasis, and suggested a mechanism mediated by certain inflammatory or haematopoietic cytokines in the bone marrow microenvironment played a role in psoriasis.

As for the essence in pathogenesis mechanism and therapeutic strategies, additional study<sup>3</sup> presented that elevation of HES1 mRNA expression suggested a potential role of the Notch signaling pathway in psoriasis, and target therapy utilizing anti-tumor necrosis factor  $\alpha$  as reported<sup>6</sup> and alefacept<sup>8</sup> could also be referred.



---

In brief, a vital and effective method for investigation is to launch a foundation of an ideal animal model. In fact, since 1940s, the progress in animal model of psoriasis as skin lesion of psoriasis-like histology has been conducted from topical drug administration to local or intravascular injection of T cells<sup>9</sup> which were all included in a limitation as a local and temporal lesion model, far from being a systematic and sustainable satisfactory subject to promisingly meet and propel the Psoriasis researches including gene therapy, T cell vaccine, and drug screening. Hopefully, given that bone-marrow derivative pathogenesis was confirmed, a substantially novel animal model would be facilitated for hematopoietic stem cell therapy to solute Psoriasis.

With regard to the latest reports on the relationships between psoriasis and stomatology, there are four literatures talked about the oral manifestations and involvements with psoriasis<sup>10,11</sup>, three articles discussed the association of psoriasis with dental caries and periodontitis<sup>12,13</sup>, and two declarations about the treatment of multiple diseases involving psoriatic disorder and Behcet's disease<sup>14</sup>, as well as the STAT3 genetic variants in the susceptibility to these two medical conditions<sup>15</sup>.

A mutual triggering of one disease triggered by the other disease drug between psoriasis agents and Behçet's disease drugs seems to be presented and concerned by Ophthalmological and Pharmacological experts respectively<sup>14,16</sup>, in these investigations they in sighted into Behçet's disease or oral mucositis with psoriasis. Briefly, dental Infection was viewed as a triggering factor in Palmoplantar Pustulosis<sup>17</sup>. Oral candidiasis was also evaluated in patients with psoriasis<sup>18</sup>. To decrease some mortality,

allogeneic BMT and new knowledge are worth to be considered by both stomatologists and dermatologists.

**Conclusion:**

Psoriasis is either a keratinocyte disorder or an immunocyte-mediated chronic skin inflammatory disease. There is more medication-related rather than Psoriasis-related osteomyelitis reported<sup>10</sup>. In this unusual mandibular osteomyelitis in concurrence with Psoriasis, the exact mutual pathogenesis remains unclear. In fact, the bone marrow in which certain microenvironmental inflammatory or haematopoietic cytokines might play a role is under suspicion for Psoriasis's immunopathogenesis<sup>6,9</sup>. Further insights of this severe auto immunologic disease are marching. To decrease some mortality, allogeneic BMT and new knowledge are worth to be considered by both stomatologists and dermatologists.

**Disclaimer regarding Consent/Ethical Approval:**

As per university standard guideline participant consent and ethical approval has been collected and preserved by the authors

**REFERENCES**

1. Amanda SB, Richard LG. Innate Immunity and antimicrobial defense systems in psoriasis[J]. *Clin Dermatol* 2007; 25(6): 616–624.
2. Nickoloff BJ, Nestle FO. Recent insights into the immunopathogenesis of psoriasis provide new therapeutic opportunities[J]. *J Clin Invest* 2004; 113: 1664–75.
3. Zhang K, Hou R, Niu X, et al. Decreased colony formation of high proliferative potential colony-forming cells and granulocyte-macrophage colony-forming units and

- 
- increased Hes-1 expression in bone marrow mononuclear cells from patients with psoriasis[J]. *Br J Dermatol* 2010; 163: 93–101.
4. Tamas Masszi, Arpad Farkas, Peter Remenyi, et al. Ten-year remission of psoriasis after allogeneic but not autologous bone marrow transplantation[J]. *Dermatol* 2006; 212: 88–89.
  5. Knuckles MLF, Levi E, Soung J. Defining and treating moderate plaque psoriasis: a dermatologist survey[J]. *J Dermatolog Treat* 2018; **22**: 1-6.
  6. Anna B, Serena L, Teresa C, Matteo M, Annunziata R, Luisa DC. Anti-Tumor Necrosis Factor- $\alpha$  Therapy in the Management of Psoriasis and B-Chronic Lymphocytic Leukemia[J]. *Case Rep Dermatol* 2011; 3: 60–63.
  7. Shibahara T. Imaging modalities for drug-related osteonecrosis of the jaw (2), Overview of the position paper on medication-related osteonecrosis of the jaw and the current status of the MRONJ in Japan[J]. *Jpn Dent Sci Rev.* 2019 Nov;55(1):71-75.
  8. Gerald GK, Kristina PC. Development and use of alefacept to treat psoriasis[J]. *J Am Acad Dermatol* 2003; 49: S87-97.
  9. Kaiming Z, Xinhua L. Bone marrow, the Centrum of Psoriatic Immunopathogenesis? (In Chinese)[J]. *Chin J Derm Venereol*, 2004; 18(8): 501-503.
  10. Ganzetti G, Campanati A., Santarelli A, et al. Involvement of the oral cavity in psoriasis: results of a clinical study[J]. *Br J Dermatol* 2015; 172(1): 282–285.
  11. Yer LN, Gwen CB. Oral manifestations of psoriasis. Clinical presentation and management[J]. *New York State Dent J* 2012; 78(3): 14-18.
  12. Fadel H T, Ingela F, Ann-Marie C, et al. Profiles of dental caries and periodontal disease in individuals with or without psoriasis[J]. *J Periodontol* 2013; 84(4): 477-485.
  13. Egeberg A, Mallbris L, Gislason G, et al. Risk of periodontitis in patients with psoriasis and psoriatic arthritis. *J Eur Acad Dermatol Venereol* 2017; **31**: 288-293.
  14. Kawazoe Y, Sugita S, Yamada Y, et al. Psoriasis triggered by infliximab in a patient

---

with Behçet's disease [J]. *Japa J Ophthalmol* 2013; 57(1): 95-97.

15. Cénit MC, Ortego-Centeno N, Raya E, et al. Influence of the STAT3 genetic variants in the susceptibility to psoriatic arthritis and Behcet's disease[J]. *Human Immunol* 2013; 74(2): 230–233.
16. Popa A M, Kelly V, Latha R, et al. Bevacizumab-induced oral mucositis in background of cutaneous plaque-type psoriasis[J]. *Ann Pharmacotherapy* 2012; 46(11): e32.
17. Kikuchi N, Yamamoto T. Dental Infection as a Triggering Factor in Palmoplantar Pustulosis[J]. *Acta dermato-venereologica* 2013; 93(6): 721-722.
18. Chularojanamontri L, Wongpraparut C, Tuchinda P, et al. Oral Candida Colonization in Thai Patients with Psoriasis[J]. *J Med Assoc Thai* 2016; 99: 84-7.

## Figures Legends

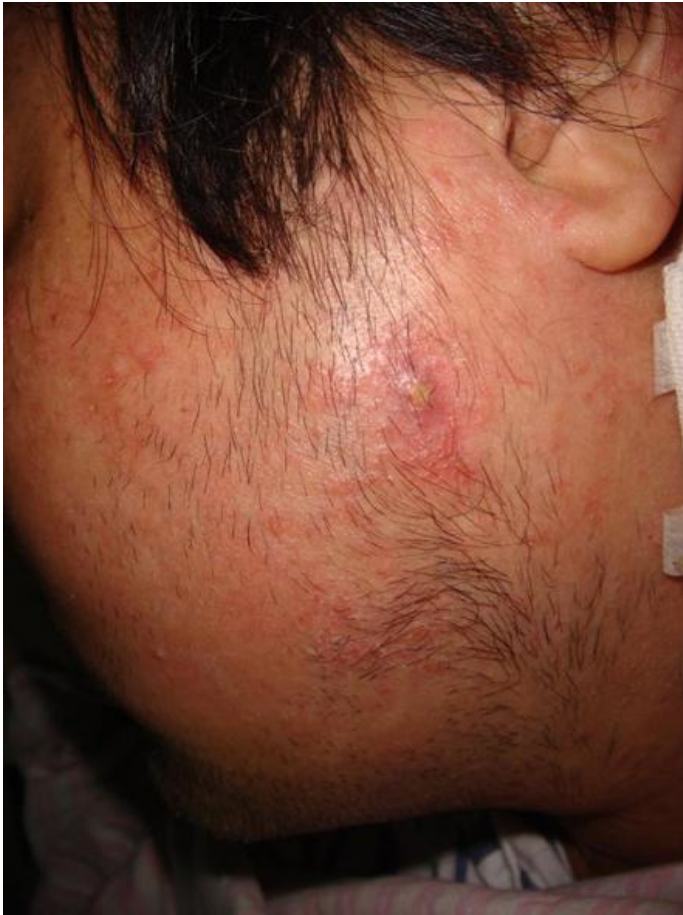

Figure 1 The patient's fistula and swelling from mandibular osteomyelitis in his left cheek.

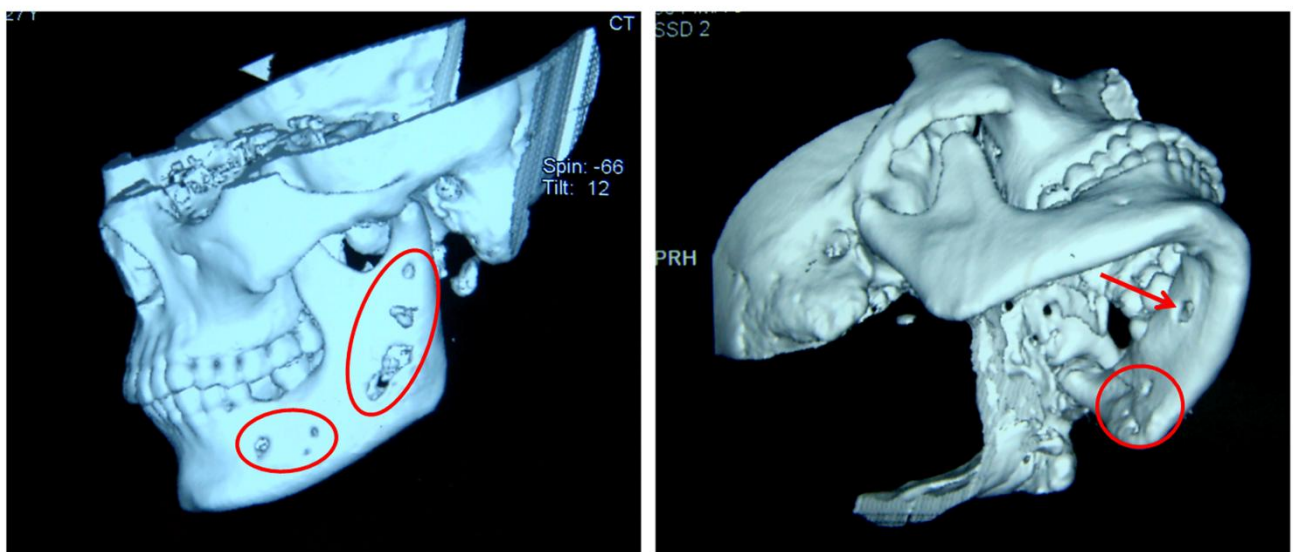

Figure 2 The CT scanning photographs of his mandible and maxilla showed his left mandibular osteomyelitis.

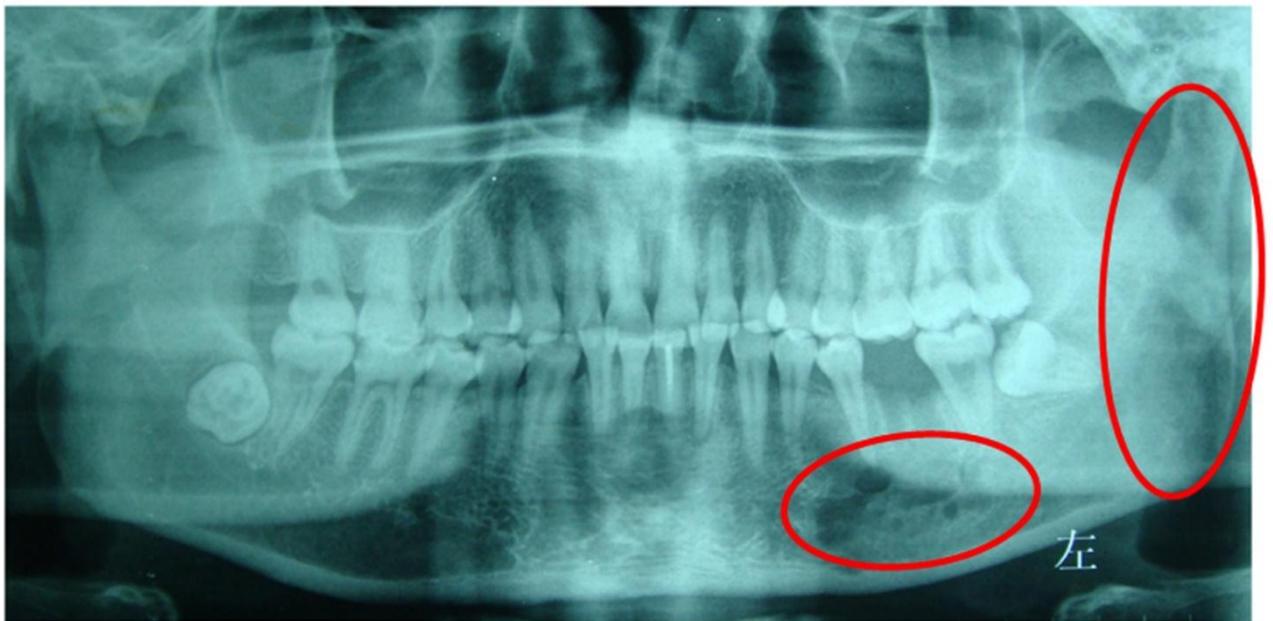


Figure 3 Panoramic X-ray of his mandible and maxillar showed his left madibular osteomyelitis.