

Hypofractionated radiotherapy using simultaneous integrated boost technique With Concurrent and Adjuvant Temozolomide for glioblastoma multiforme

ABSTRACT

Aim: This study was conducted to assess the safety and efficacy of postoperative hypofractionated radiotherapy (HRT) using simultaneous integrated boost (SIB) technique for glioblastoma multiforme (GBM) compared to conventional radiotherapy (CRT).

Study design: This was a prospective study with historical control arm.

Place and duration of the study: Department of Clinical Oncology and Nuclear Medicine, Mansoura University Hospital, Mansoura, Egypt, between May 2017 and June 2019.

Methods: The intervention (HRT) group included 30 patients who received 3D conformal HRT with SIB using field in field (FIF) technique to deliver a differential radiation dose to different targets. Planning target volume 60 (PTV60) includes the gross target volume (GTV) plus a 5-mm margin, and PTV45 includes the GTV plus a 15-mm margin. PTV60 will receive 60 Gy in 20 fractions, and PTV45 will receive 45 Gy in the same 20 fractions (one fraction daily and 5 days per week). The CRT group included 30 patients who received 3D conformal CRT with total dose 60 Gy in 2-Gy fractions delivered over 6 weeks. Both groups were planned to receive concurrent and adjuvant temozolamide.

Results: The median PFS was 10 months in both groups. The median OS was 13 months in HRT group versus 12 months in CRT group which is statistically non significant. The toxicities were mild and acceptable. Performance status and adjuvant temozolamide were significant predictors that affect the overall survival.

Conclusion: HRT with SIB using 3D conformal RTH with (FIF) technique in patients with GBM is a feasible and safe treatment and its results are comparable to the conventional radiotherapy.

Keywords: Glioblastoma multiforme, Simultaneous integrated boost, hypofractionated radiotherapy, Temozolomide, Toxicity, Efficacy

1. INTRODUCTION

Glioblastoma is the most prevalent and most aggressive malignant primary brain neoplasm, accounts for 54% of all gliomas, It is considered **an** incurable disease with a median survival of 16 months (1).

The standard treatment of GBM should be based on multidisciplinary team and include maximal safe resection followed by RT concurrent with temozolomide (TMZ) then adjuvant TMZ (2).

Localized field radiotherapy is the **standard treatment** of GBM and the target dose is 60 Gy, delivered over six weeks in 2-Gy fractions(3).

The failure pattern after standard treatment is local , and intensive treatment targeting localized lesions is required to improve the outcome in patients with GBM.Dose escalation to the contrast-enhancing volume using contemporary techniques is area of research and still investigated by ongoing clinical trials(4).

Radiation dose escalation using conventional fractionation failed to demonstrate survival benefit in patients with GBM ,whereas high dose per fraction in hypofractionated radiotherapy may has radiobiological advantage and will reduce tumor repopulation but may associated with higher incidence of radiation necrosis(5).

Multiple studies that used hypofractionated accelerated radiation therapy in patients with GBM have demonstrated median survival comparable to the result of conventional radiotherapy concomittent with chemotherapy, with good tolerability and shortening of the treatment period by 2 weeks (6).

This study was done to demonstrate the safety and efficacy of postoperative HRT using SIB for GBM compared to CRT.

2. METHODS

This is a prospective study that enrolled 30 patients with Glioblastoma who attended to Clinical Oncology and Nuclear Medicine Department at Mansoura University Hospital between May 2017 and June 2019. The results are compared to **historical control arm that included** patients with same criteria who received standard chemoradiotherapy within previous 2 years from 2014 to 2016.

2.1 Selection of patients

Inclusion criteria: age >18 years,histologically proven GBM,Eastern Collaborative Oncology Group (ECOG) Performance status had to be equal or less than 2 and acceptable kidney ,liver and bone marrow functions. Informed consent **was taken** . Exclusion criteria: prior RT to the head or neck area,prior use of chemotherapy and Recurrent disease.

2.2 Patient assessment

All patients **were** initially evaluated with a complete history , neurological examination and a computerized tomography (CT) scan and/ or magnetic resonance imaging (MRI) preoperatively. Extent of surgical resection was recorded based on surgical report and postoperative radiology.

2.3 Treatment protocol

2.3.1 Intervention group: After surgery (Total , subtotal resection or biopsy) all patients received 3D conformal HRT with SIB on a linear accelerator to deliver a differential radiation dose to different targets. TMZ was administered orally, once per day at 75 mg/m² concomitant with radiation therapy .Adjuvant TMZ was given at 150–200 mg/m² orally once per day for 5 consecutive days every 28 days, for six cycles.

All patients were simulated in supine position and were immobilized, using mask.CT- based treatment planning was done for all patients with IV contrast.The gross tumor volume (GTV) was delineated as the operative bed and/or contrast enhancing lesion on the postoperative MRI. Planning target volume 60 (PTV60) includes the GTV plus a 5-mm margin.Planning target volume 45 (PTV45) includes the GTV plus a 15-mm margin. PTV60 will receive 60 Gy in 20 fractions, and PTV45 will receive 45 Gy in the same 20 fractions (one fraction daily and 5 days per week).The maximum tolerance dose for the brain stem, chiasma, ,optic nerves and eyes) was 45 Gy , lens was 7 Gy and for cochlea was 35 Gy.

2.3.2 Historical control group included patients who received 3D conformal conventional fractionated radiotherapy with total dose 60 Gy in 2-Gy fractions delivered over 6 weeks concurrent with (TMZ) then adjuvant (TMZ) 6 cycles.

2.4 Follow up, assessment

The patients were evaluated on a weekly basis during concurrent RT and TMZ, on a monthly basis during adjuvant TMZ chemotherapy, and once every 3 months thereafter. The patient evaluation included history and physical examination, blood tests for the metabolic panel and hematological profile, performance status, and toxicity assessment. Contrast-enhanced brain MRI was performed before study treatment as a baseline, and then at 1 and 3 months after RT, and once every 3 months thereafter. The National Cancer Institute Common Terminology Criteria for Adverse Events (NCI-CTCAE) version 4 was used to grade the treatment-related toxicities .

2.5 Statistical analysis

Data were entered and analyzed using IBM-SPSS software (Version 25.0).Survival analysis was run with the following tests:The Kaplan-Meier test, Log-rank test and Cox proportional hazards regression . For any of the used tests, results were considered as statistically significant if p value ≤ 0.050 .

3. RESULTS

Each group included 30 patients with Twenty two male patients (73.3 %) and eight (26.7 %) female patients. The mean age was 53.3 ± 8.8 years in HRT arm versus 53.6 ± 10 years in CRT arm.All patients completed the radiotherapy course but unfortunately some patients in both groups had gap during radiotherapy course due to device malfunction . Not all of them received concurrent and adjuvant TMZ due to economic reasons.Also The patient and

treatment characteristics of both groups are summarized in Table 1. There is no significant difference between both arms.

Table 1. patient and treatment characteristics

Parameter	HRT arm	CRT arm	P value
N	30	30	
Age (years) Mean ± SD	53.3 ± 8.8	53.6 ± 10.4	0.91
Sex N (%) Male Female	22 (73.3%) 8 (26.7%)	22 (73.3%) 8 (26.7%)	1.00
Performance status N (%) PS 0 PS 1 PS 2	8 (26.7%) 12 (40%) 10 (33.3%)	3 (10%) 17 (56.7%) 10 (33.3%)	0.21
Tumor location Frontal	7 (23.3%)	9 (30%)	0.19
Parietal	13 (43.3%)	10 (33.3%)	
Temporal	8 (26.7%)	9 (30%)	
Occipital	2 (6.7%)	1 (3.3%)	
Thalamic	0 (0%)	1 (3.3%)	
Surgery type Total excision Subtotal excision Biopsy	4 (13.3%) 23 (76.7%) 3 (10%)	4 (13.3%) 22 (73.3%) 4 (13.3%)	1.00
Temozolomide with radiotherapy	26 (86.7%)	28 (93.3%)	0.67
Adjuvant Temozolomide	25 (83.3%)	21 (70%)	0.22
Median Gap between surgery and radiotherapy (months)	1.5 (1.0-2.0)	1.25 (1.0-2.0)	0.99

Patients who had Gap during radiotherapy	8 (26.7%)	6 (30%)	0.54
---	-----------	---------	------

This study was conducted to assess if there is significant difference in survival. 26 patients in HRT had progression, 23 patients died, all from the disease except 2 patients died from another causes (one died from covid -19 pneumonitis and one from cardiovascular disease). All patients in the historical Group were dead. The median PFS was 10 months in both groups as shown in Figure 1. The median OS was 13 months in HRT arm versus 12 months in CRT arm (P value=0.09) which is statistically non significant as shown in Figure2. Between all factors of patients and tumor Characteristics, the only independent predictors of OS were using adjuvant TMZ and better PS as presented in Table 2.

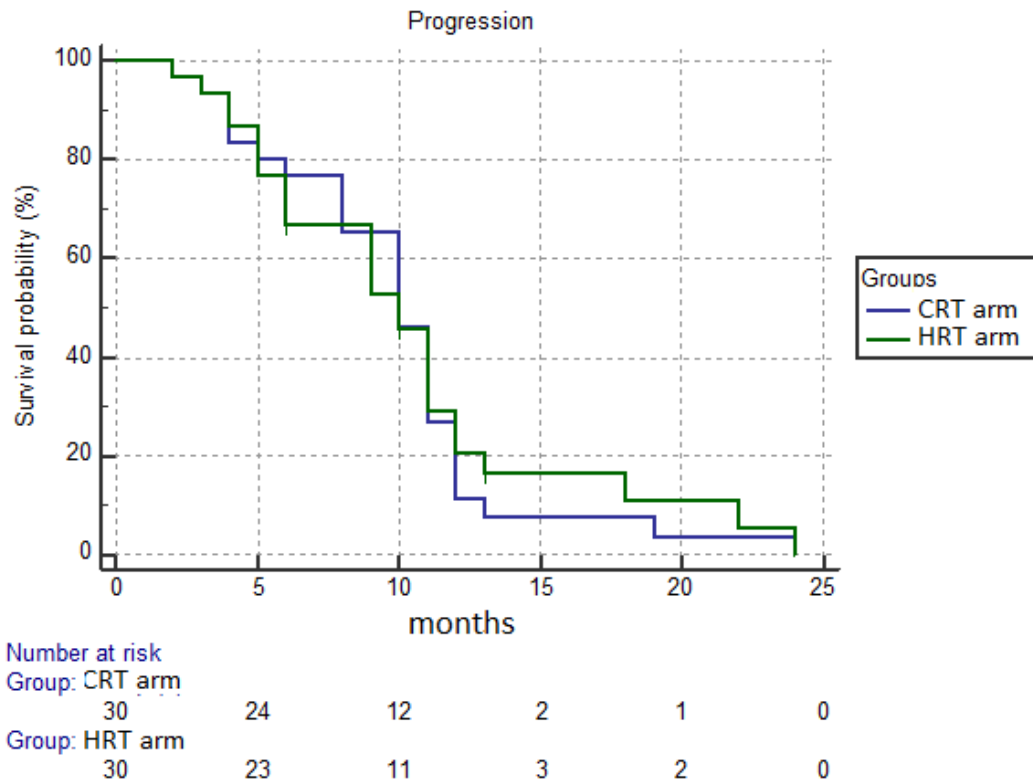
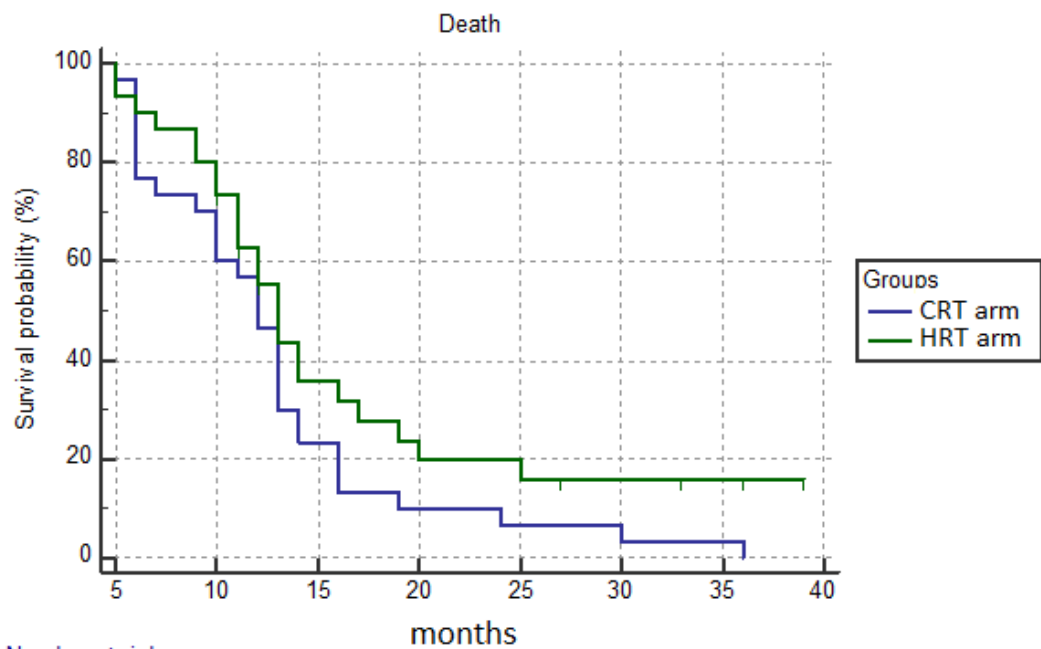


figure 1. Progression free survival Curve



Number at risk		5	10	15	20	25	30	35	40
Group: CRT arm		29	18	7	3	2	1	1	0
Group: HRT arm		28	21	9	5	4	3	2	0

figure 2 Overall Survival Curve

UNDER

Table 2. Multivariate analysis for overall survival

Predictor	Multivariate	
	HR (95% CI)	P
Age	1.002 (0.97-1.04)	0.93
PS	2.07 (1.27-3.38)	0.004
Adjuvant Temozolomide No Yes	R 0.17 (0.07-0.43)	<0.001
Gap between surgery and radiotherapy	1.18 (0.71-1.95)	0.52

Among both arms ,the Acute adverse effects were mainly grade 1 and 2 fatigue and headache and were observed during the concurrent radiotherapy and chemotherapy. Grade 3 thrombocytopenia developed only in one patient in HRT arm. No patients developed grade 4 toxicity. Fatigue and headache were also the most common late toxicities. Two patients in HRT arm developed confusion and 1 patient in each arm had visual changes. One patient in hypofractionated arm developed radiation necrosis and was diagnosed by pathological examination after reoperation. The difference between both arms in treatment toxicities was not statistically significant.

4. Discussion:

For GBM ,fractionated radiation therapy improves OS compared with chemotherapy or best supportive care alone following surgical resection(3). the Standard dose-fractionation schedule is 60 Gy in 2-Gy fractions delivered over 6 weeks(3). The accelerated radiotherapy protocols and using higher doses per fraction will reduce the treatment duration,so may have a radiobiological advantage and decrease the tumor repopulation (7).

In our study , the patients received Hypofractionated radiotherapy using simultaneous integrated boost technique. Although IMRT was applied in most of the studies, We used 3D conformal field in field (FIF) technique. The median PFS was 10 months in both groups . The median OS was 13 and 12 months respectively which is statistically not significant and this result was in line with other trials.

Panet-Raymond et al. used accelerated hypofractionated IMRT with cocurrent and adjuvant TMZ in 35 patients with newly diagnosed GBM using a concomitant boost technique, the gross tumor volume received 60 Gy in 20 fractions and the PTV received 40 Gy in 20 fractions. The median OS was about 14.4 months, and the median PFS was 7.7 months.

The recurrence was detected centrally, within 2 cm of the initial GTV. They reported in their study minimal acute toxicity, and the most common one was moderate fatigue. No Grade 3 or 4 toxicities were detected during concomitant TMZ with RTH. Myelotoxicity, although common, was not severe. During adjuvant TMZ, grade 3-4 toxicity was limited to one patient with nausea and vomiting (8).

Cho, Kwan Ho et al. in their study used SIB IMRT in 40 patients with high-grade gliomas (WHO grade III, 14 patients; grade IV, 26 patients). A dose of 50 Gy in 25 fractions (2 Gy per fraction) was delivered to the PTV and 60 Gy in 25 fractions (2.4 Gy per fraction) was delivered to the GTV. Twenty patients received temozolomide chemotherapy. The median OS and PFS were 14.8 months and 11.0 months (9).

Sultanem, Khalil et al. in their trial included 25 patients with GBM treated with hypofractionated IMRT. 40 Gy in 20 fractions (5 daily fractions per week) were delivered to GTV +1.5 cm margin. 60 Gy in 20 daily fractions (3 Gy per fraction) were delivered to the GTV. The median OS and PFS were 9.5 months and 5.2 months. Acute adverse effects developed in 2 (8%) patients, and no late toxicity was observed (10). In this study the patients didn't receive TMZ and this may explain the lower survival than our study.

Jastaniyah N et al. used hypofractionated IMRT with concurrent and adjuvant TMZ in 25 patients with GBM. Two dose levels were done, the first was 54.4 Gy in 20 fractions over 4 weeks and the second was 60 Gy in 22 fractions over 4.5 weeks. The median survival and PFS were 15.67 months and 6.7 months. Most of the patients had mild or no toxicities. One patient developed *Pneumocystis carinii* pneumonia infection. Grade 3 and/or 4 hematological toxicity developed in two patients (6).

Zhong and his colleagues reported the efficacy of moderately hypofractionated SIB IMRT combined with TMZ for GBM, 80 patients received 64 Gy in 27 fractions delivered to the GTV, 60 Gy in 27 fractions delivered to the clinical target volume 1 (CTV1), and 54 Gy in 27 fractions delivered to CTV2. The median PFS was 15 months. The median OS was 21 months. These results may be higher than our results due to different hypofractionated dose and larger number of patients. Also all patients in this study had surgery either total or subtotal and no one had only biopsy. The most common acute adverse effects were grade 1 or 2 during concurrent chemoradiation in the form of nausea, fatigue, headache and hematologic toxicities. Grade 3 toxicity was detected in 5 patients, including neutropenia, anemia, and thrombocytopenia. Grade 4 toxicity was not reported. Cognitive dysfunction was the most common late toxicity, which was detected in 4 (5.0%) patients (11).

Mallick S et al. in their trial enrolled 89 newly diagnosed GBM patients divided in 2 groups, Group 1 received 3D conformal RTH (60 Gy in 30 fractions over 6 weeks - 2 Gy/per fraction) and Group 2 received SIB IMRT (60 Gy in 20 fractions over 4 weeks - 3 Gy/per fraction to high-risk PTV and 50 Gy in 20 fractions over 4 weeks - 2.5 Gy/per fraction to low-risk PTV). Median OS in the Group 1 was 18.07 months and 25.18 months in Group 2, $p = 0.3$. Median PFS for all patients was 13.5 months. As in our trial only one patient had developed radio necrosis. Better OS was detected in young patients (less than 40 years), patients with a gross total excision of tumor and a mutated IDH-1. PFS was higher for patients with a gross total resection of tumor and a mutated IDH-1 (12).

A systematic review and meta-analysis was published in 2019 to demonstrate the efficacy and safety of HRT, and to compare between it and CRT for the treatment of patients with GBM. It concluded that Patients treated with HRT and CRT had comparable OS and PFS, and similar rates of adverse events. However, in participants aged >70 years, those who received HRT had a higher OS than those who received CRT. As there was some limitations

, The role of HRT in the treatment of GBM in young patients and those with better prognosis requires further research(13). Another systematic review and meta-analysis was done to analyse the impact of hypofractionation on survival in patients with GBM. Eleven comparative trials were enrolled. They concluded that due to few trials and limited quality of reporting, it is difficult to define the role of hypofractionation in GBM, but in general hypofractionation resulted in comparable survival results with the benefit of a shortened treatment period (14).

There are some limitations in our study and should be considered. The non randomized prospective arm and historical arm design and the small sample size. Also other studies have demonstrated the role of O6-methylguanine-DNA-methyltransferase (MGMT) promoter methylation. Unfortunately, MGMT status was not identified as molecular analysis is not routinely done in our hospital. However, our study reported its aim which demonstrated that HRT with SIB in patients with GBM is a feasible and safe treatment and its results is comparable to the conventional RTH. Moreover, this protocol allowed us to treat patients with shortened period. All patients completed their treatment schedule with no interruption due to toxicity. The current study fits our limited resources. This also will decrease work load on the used machines by decreasing number of treated patients per day. Furthermore this will get rid of the long waiting lists of treatment.

5. CONCLUSION

HRT with SIB using 3D conformal RTH with (FIF) technique in patients with GBM is a feasible and safe treatment and its results is comparable to the conventional radiotherapy. However, more trials with larger number of patients are necessary.

CONSENT

Informed consent has been written before patient enrolment in the trial.

ETHICAL APPROVAL

Our protocol was submitted to the IRB board of Mansoura Medicine faculty and was approved before starting the trial.

COMPETING INTERESTS DISCLAIMER:

Authors have declared that no competing interests exist. The products used for this research are commonly and predominantly use products in our area of research and country. There is absolutely no conflict of interest between the authors and producers of the products because we do not intend to use these products as an avenue for any litigation but for the advancement of knowledge. Also, the research was not funded by the producing company rather it was funded by personal efforts of the authors.

REFERENCES

1. Koshiy, Matthew et al. "Improved survival time trends for glioblastoma using the SEER 17 population-based registries." *Journal of neuro-oncology* vol. 107,1 (2012): 207-12. doi:10.1007/s11060-011-0738-7
2. Davis, Mary. "Glioblastoma: Overview Of Disease And Treatment". *Clinical Journal Of Oncology Nursing*, vol 20, no. 5, 2016, pp. S2-S8. Oncology Nursing Society (ONS), doi:10.1188/16.cjon.s1.2-8.
3. Cabrera, Alvin R et al. "Radiation therapy for glioblastoma: Executive summary of an American Society for Radiation Oncology Evidence-Based Clinical Practice Guideline." *Practical radiation oncology* vol. 6,4 (2016): 217-225. doi:10.1016/j.prr.2016.03.007
4. Shieh, Li-Tsun et al. "Survival of glioblastoma treated with a moderately escalated radiation dose-Results of a retrospective analysis." *PloS one* vol. 15,5 e0233188. 15 May. 2020, doi:10.1371/journal.pone.0233188
5. Chen, Changhu et al. "Phase I trial of hypofractionated intensity-modulated radiotherapy with temozolomide chemotherapy for patients with newly diagnosed glioblastoma multiforme." *International journal of radiation oncology, biology, physics* vol. 81,4 (2011): 1066-74. doi:10.1016/j.ijrobp.2010.07.021
6. Jastaniyah, Noha et al. "Phase I study of hypofractionated intensity modulated radiation therapy with concurrent and adjuvant temozolomide in patients with glioblastoma multiforme." *Radiation oncology (London, England)* vol. 8 38. 20 Feb. 2013, doi:10.1186/1748-717X-8-38.
7. Shenouda, George et al. "A Phase 2 Trial of Neoadjuvant Temozolomide Followed by Hypofractionated Accelerated Radiation Therapy With Concurrent and Adjuvant Temozolomide for Patients With Glioblastoma." *International journal of radiation oncology, biology, physics* vol. 97,3 (2017): 487-494. doi:10.1016/j.ijrobp.2016.11.006
8. Panet-Raymond, Valerie et al. "Accelerated hypofractionated intensity-modulated radiotherapy with concurrent and adjuvant temozolomide for patients with glioblastoma multiforme: a safety and efficacy analysis." *International journal of radiation oncology, biology, physics* vol. 73,2 (2009): 473-8. doi:10.1016/j.ijrobp.2008.04.030
9. Cho, Kwan Ho et al. "Simultaneous integrated boost intensity-modulated radiotherapy in patients with high-grade gliomas." *International journal of radiation oncology, biology, physics* vol. 78,2 (2010): 390-7. doi:10.1016/j.ijrobp.2009.08.029
10. Sultanem, Khalil et al. "The use of hypofractionated intensity-modulated irradiation in the treatment of glioblastoma multiforme: preliminary results of a prospective trial." *International journal of radiation oncology, biology, physics* vol. 58,1 (2004): 247-52. doi:10.1016/s0360-3016(03)00819-8
11. Zhong, Liangzhi et al. "Efficacy of moderately hypofractionated simultaneous integrated boost intensity-modulated radiotherapy combined with temozolomide for the postoperative treatment of glioblastoma multiforme: a single-institution experience." *Radiation oncology (London, England)* vol. 14,1 104. 13 Jun. 2019, doi:10.1186/s13014-019-1305-1

12. Mallick, Supriya et al. "Hypofractionated accelerated radiotherapy (HART) with concurrent and adjuvant temozolomide in newly diagnosed glioblastoma: a phase II randomized trial (HART-GBM trial)." *Journal of neuro-oncology* vol. 140,1 (2018): 75-82. doi:10.1007/s11060-018-2932-3
13. Liao, Guixiang et al. "Efficacy and Safety of Hypofractionated Radiotherapy for the Treatment of Newly Diagnosed Glioblastoma Multiforme: A Systematic Review and Meta-Analysis." *Frontiers in oncology* vol. 9 1017. 14 Oct. 2019, doi:10.3389/fonc.2019.01017
14. Trone, Jane-Chloe et al. "Survival after hypofractionation in glioblastoma: a systematic review and meta-analysis." *Radiation oncology (London, England)* vol. 15,1 145. 8 Jun. 2020, doi:10.1186/s13014-020-01584-6

UNDER PEER REVIEW