

Comparison of submucosal injection of Dexamethasone and Triamcinolone acetonide for control of postoperative pain after impacted mandibular third molar surgery-A Prospective Randomized Controlled Trial.

ABSTRACT:

The aim of the study was to compare the efficacy of submucosal injection of dexamethasone and triamcinolone acetonide on postoperative pain, swelling, occurring after impacted mandibular third molar surgery. A total of 150 patients with asymptomatic, unilateral, impacted mandibular third molar, and without any systemic disease were included in this study. Patients were divided into three groups randomly, one group dexamethasone, and the second group triamcinolone acetonide third group placebo . Dexamethasone and triamcinolone acetonide were injected into submucosa at about 0.5 cm to 1 cm above the surgical area submucosally. Pain evaluation was performed by visual analog scale (VAS). There were statistically significant differences between the three groups on the different days of the postoperative period. The effect of triamcinolone acetonide works postoperatively and the effect of triamcinolone acetonide on trismus and pain was better than other groups . There was no significant difference between the effects of dexamethasone and triamcinolone acetonide regarding postoperative complications. The submucosal injection of dexamethasone and triamcinolone acetonide might be an effective treatment following impacted mandibular third molar surgery, and triamcinolone acetonide could be applied as an alternative to dexamethasone for reducing pain post operatively for impacted mandibular third molar surgery.

Keywords : Dexamethasone, Triamcinolone, Mandibular, molar, synthetic steroids, Maxillofacial surgery

INTRODUCTION:

The common sequelae of mandibular third molar surgery are facial swelling, pain, and trismus, all of which arise as a result of tissue inflammation due to surgical insult. These symptoms have been reported to severely affect patients' quality of life during the immediate postoperative period (McGrath *et al.*, 2003).

Impacted mandibular molars presents a common problem all over the world and its removal also may lead to other complications like pain, swelling etc. which leads to researchers all over the world to concentrate on further research.

Because of their anti-inflammatory effects, corticosteroids have been widely tested to counter these sequelae (Ngeow and Lim, 2016). This idea began with an editorial in 1954, when Kenny suggested using corticosteroids to manage postoperative sequelae of dentoalveolar surgery (Kenny, 1954). Before this, Stream and Horton and Spies *et al.* had already used cortisone or hydrocortisone for the treatment of oral diseases related to local causes and oral manifestations of inflammatory systemic disease with some success (Spies *et al.*, 1952).

Inflammation is crucial for the body's defense as concerns tissue lesions, such as those associated with surgical interventions. This process includes release of inflammatory mediators that result in vasodilation, increased vascular permeability, protein extravasation and other tissue phenomena at the cellular level, which can cause swelling, pain, increased temperature, erythema and loss of function (Lima *et al.*, 2017).

Reduction of postoperative discomfort after third molar removal is of interest for all oral and maxillofacial surgeons and their patients. Many techniques are employed to reduce the Pain, swelling and trismus of third molar removal. Various drugs have been considered in the attempt to reduce the postoperative inflammatory response associated with lower third molar removal, with many published studies (Boonsiriseth *et al.*, 2017).

In 1965, Lingenerg employed dexamethasone, a synthetic adrenocortical steroid, to control swelling and reduce difficulty in mouth opening and pain after oral surgery. From that time onward, use of synthetic steroids in oral surgery became increasingly more popular as a function of their beneficial effects in the reduction of postinflammatory signs and symptoms (Boonsiriseth *et al.*, 2012).

Several studies have investigated the influence of systemic steroids administered before or after third molar removal with satisfactory results (Neupert *et al.*, 1992). +....

MATERIAL AND METHODS:

Study setting and Data collection:

This is a Randomized controlled clinical conducted in patients from June 2019 to March 2020 who had reported to Saveetha Dental College for treatments of mandibular third molar impactions. Patients reporting to the Department of Oral and Maxillofacial Surgery with the diagnosis of mandibular third molar impaction. A sample, which contains 150 patients, was enrolled for the study and Sampling is done using Block Randomization.

+....

Sampling:

The study population included patients who underwent treatment for mandibular third molar impaction and only Mesio Angular Impaction cases done at Saveetha Dental College by means of Systematic Sampling by Block Randomization.

- Inclusion Criteria- Patients of all age groups and gender with impacted mandibular third molars were included.
- Exclusion Criteria- Patients with impacted teeth other than mandibular third molars, and common dental problems were excluded from the study. Other exclusions are
 - Allergy
 - Pregnancy and breastfeeding
 - Use of antibiotic or analgesic or anti inflammatory drugs
 - taking any drug before the surgery.

Primary Assessment Parameter:

Post-operative pain.

Patients were evaluated on 1st, 3rd, 5th and 7th post-operative days and evaluated for Duplicate patient records and incomplete data were excluded. Datas were reviewed by an external reviewer. Totally, n= 150 patients were included. Demographic data such as the patient's age, gender were also recorded.

Data Analysis:

The data obtained were tabulated in Microsoft Excel 2016 (Microsoft office 10) and later exported to SPSS (Statistical Package for Social Sciences) for Windows version 20.0, SPSS Inc, Chicago IU, USA) and subjected to statistical analysis. One Way Anova test was employed with a level of significance set at $p < 0.05$.

RESULTS AND DISCUSSION:

There were statistically significant differences between the three groups on the different days of the postoperative period. The effect of triamcinolone acetonide on pain started on the first day postoperatively and the effect of triamcinolone acetonide on trismus and pain was better than other groups at the third and seventh days. However, there was no statistically significant difference between the effects of dexamethasone and triamcinolone acetonide regarding postoperative complications. Gender distribution shows 45.33% males and 54.67% females [figure 1] age group distribution shows 21-35 years 38%, 36-50 years 42.67%, above 50 years 19.33% [figure 2], and figure 3,4 shows triamcinolone gender and age group distribution, figure 5,6 shows dexamethasone gender and age group distribution, figure 7,8 shows placebo gender and age group distribution.

Triamcinolone has mean value of 4.08 and standard deviation of 1.209[table 1] , dexamethasone has mean value of 4.86 and standard deviation of 1.129[table 1] , placebo has mean value of 4.90 and standard deviation of 1.161[table 1] ,Anova Statistical test seen in table 2,3

GRAPHS :

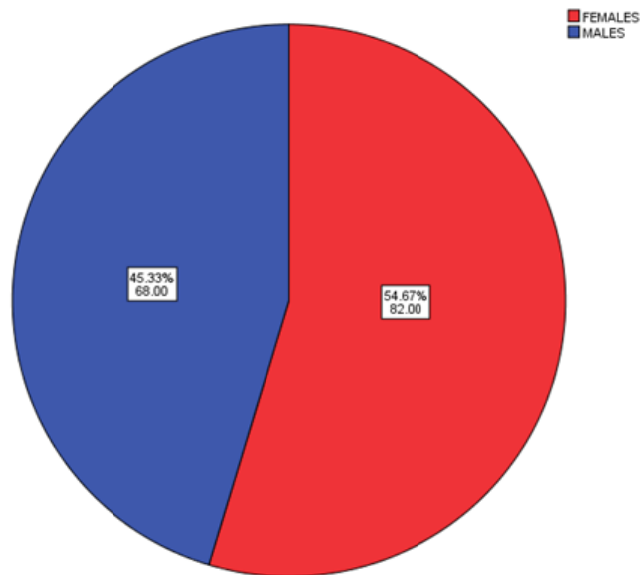


Figure 1: Pie diagram explaining gender distribution of study population. Pie diagram shows males 45.33%, females 54.67%. From the graph it is observed that the prevalence of females is more compared to males.

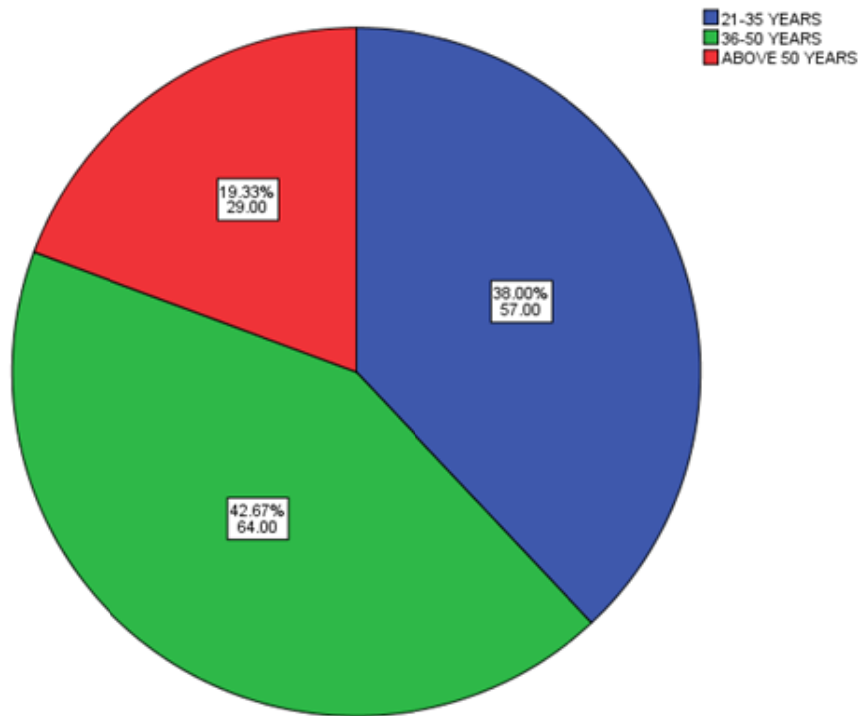


Figure 2: Age Distribution. Pie diagram showing age distribution. This graph showed that patients in 21-35 years were 38.0%, patients in 36-50 years 42.67% and patients in age group of above 50 years 19.33%. From the graph, it is found that the incidence is more among patients of 36-50 years age groups when compared to other age groups

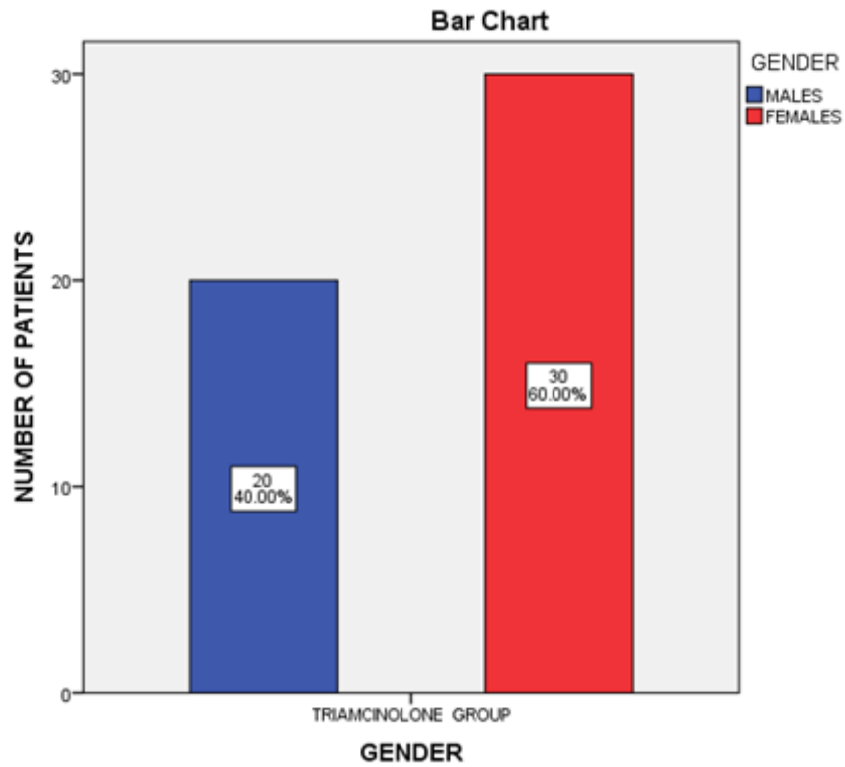


Figure 3: Triamcinolone group gender. This graph shows distribution of gender under the triamcinolone group .X axis represents gender group and Y axis represents number of patients. From the graph, it is observed that the prevalence of females is more compared to males.

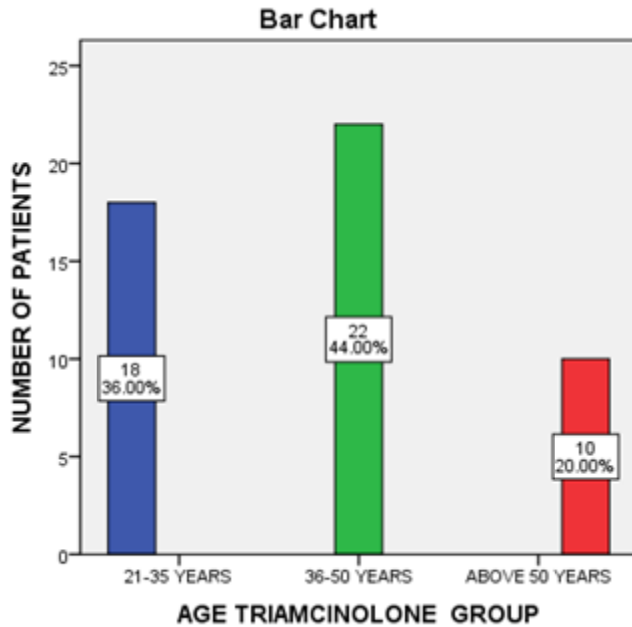


Figure 4: Triamcinolone group age distribution. This graph shows distribution of age group under triamcinolone group .X axis represents age group and Y axis represents number of patients .from the graph, it is observed that prevalence of patients in age group of 36-50years was more when compared to other groups.

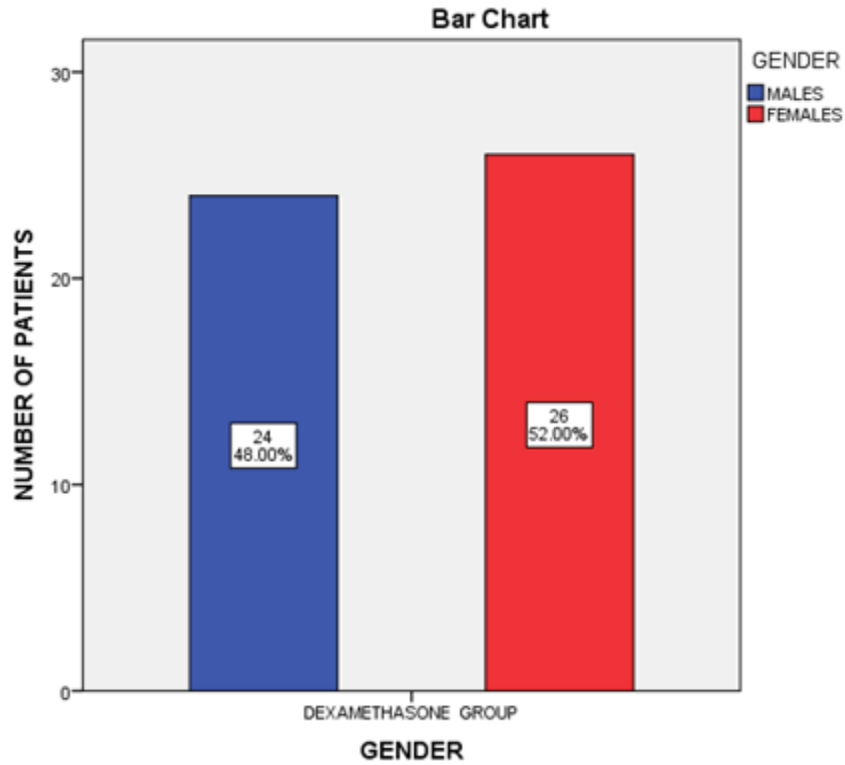


Figure 5: Dexamethasone Gender distribution. This graph shows distribution of gender under the dexamethasone group .X axis represents gender group and Y axis represents number of patients. From the graph, it is observed that the prevalence of females is more compared to males.

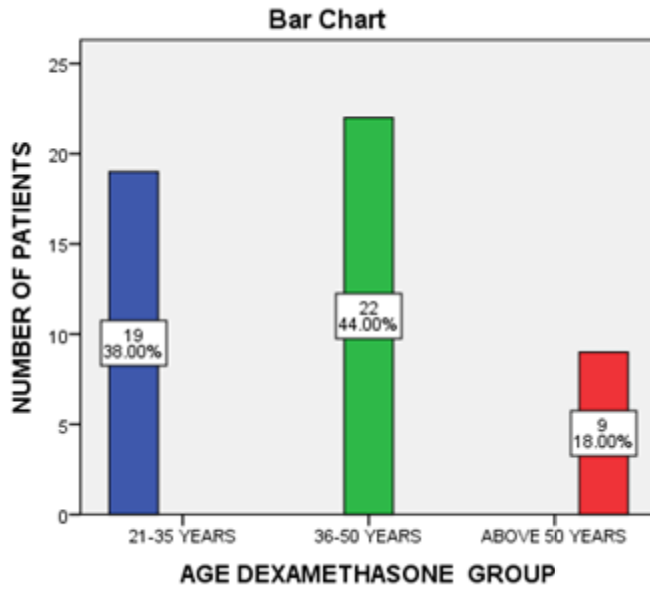


Figure 6: Dexamethasone Age distribution. This graph shows distribution of age group under dexamethasone group .X axis represents age group and Y axis represents number of patients .from the graph, it is observed that prevalence of patients in age group of 36-50years was more when compared to other groups.

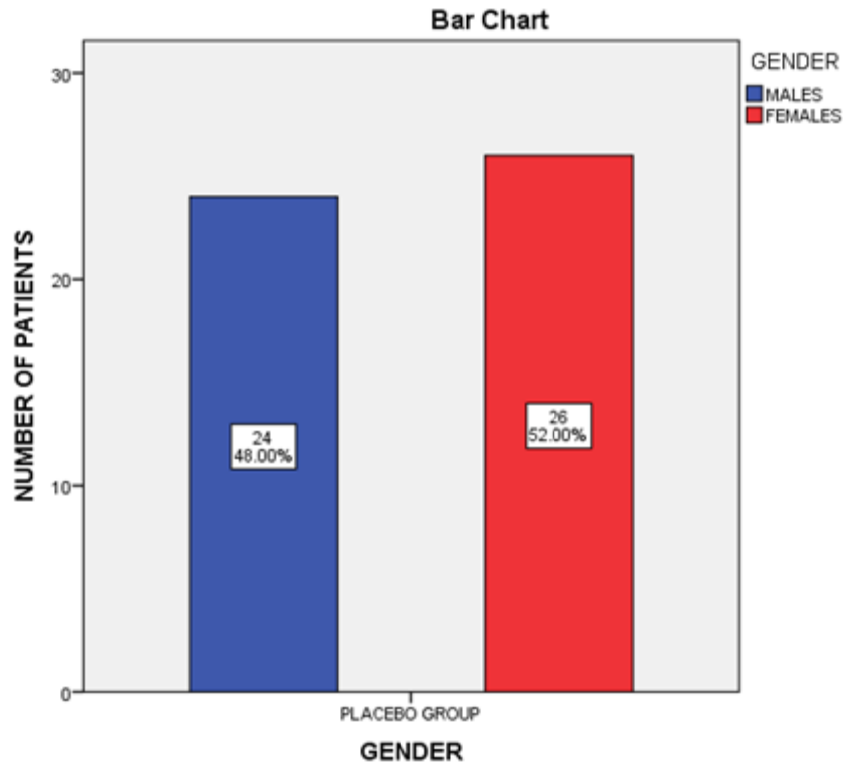


Figure 7: Placebo Gender distribution. This graph shows distribution of under placebo group .X axis represents gender group and Y axis represents number of patients. From the graph, it is observed that the prevalence of females is more compared to males.

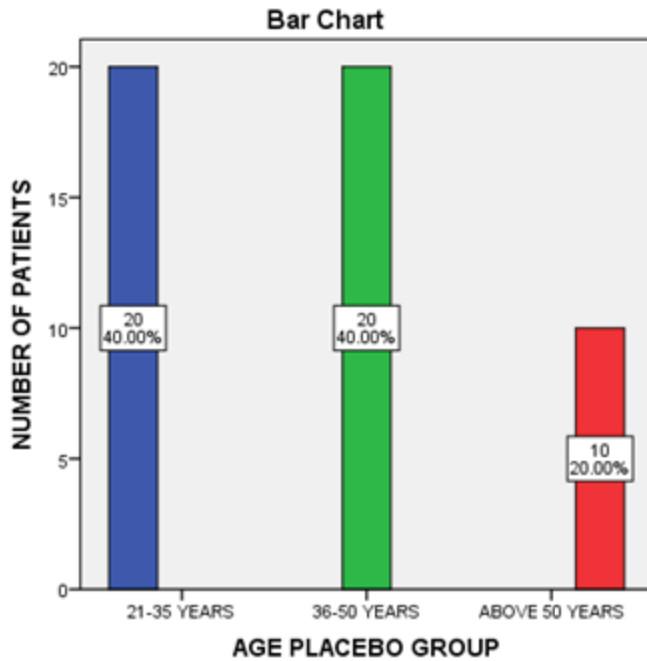


Figure 8: Placebo Age distribution. This graph shows distribution of age under placebo group .X axis represents age group and Y axis represents number of patients. From the graph, it is observed that prevalence of patients in the age group of 21- 50 years was more when compared to other groups.

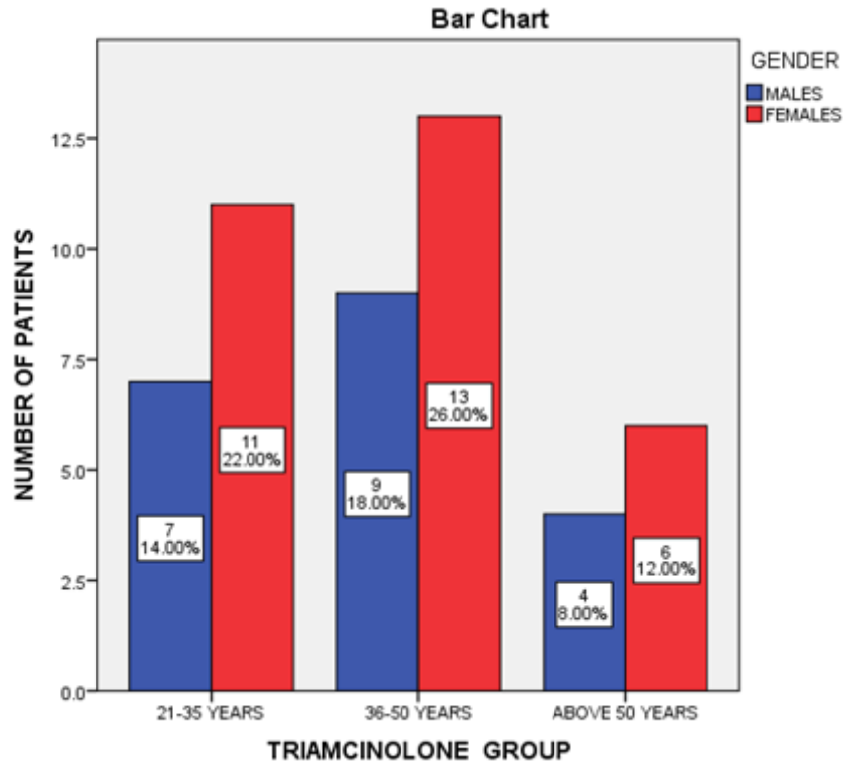


Figure 9: Triamcinolone age gender association. This graph shows distribution of age under triamcinolone group .X axis represents age group and Y axis represents number of patients. From the graph, it is observed that prevalence of patients in age group of 36- 50 years was more when compared to other groups.

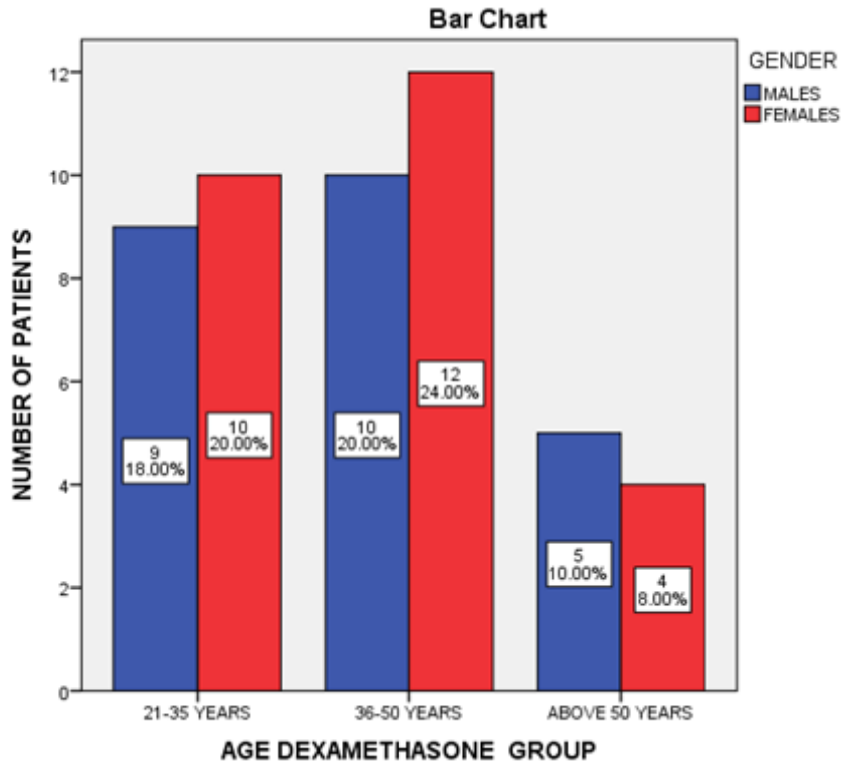


Figure 10: Dexamethasone Age gender association. This graph shows distribution of age under dexamethasone group. X axis represents age group and Y axis represents number of patients. From the graph, it is observed that prevalence of patients in age group of 21- 50 years was more when compared to other groups.

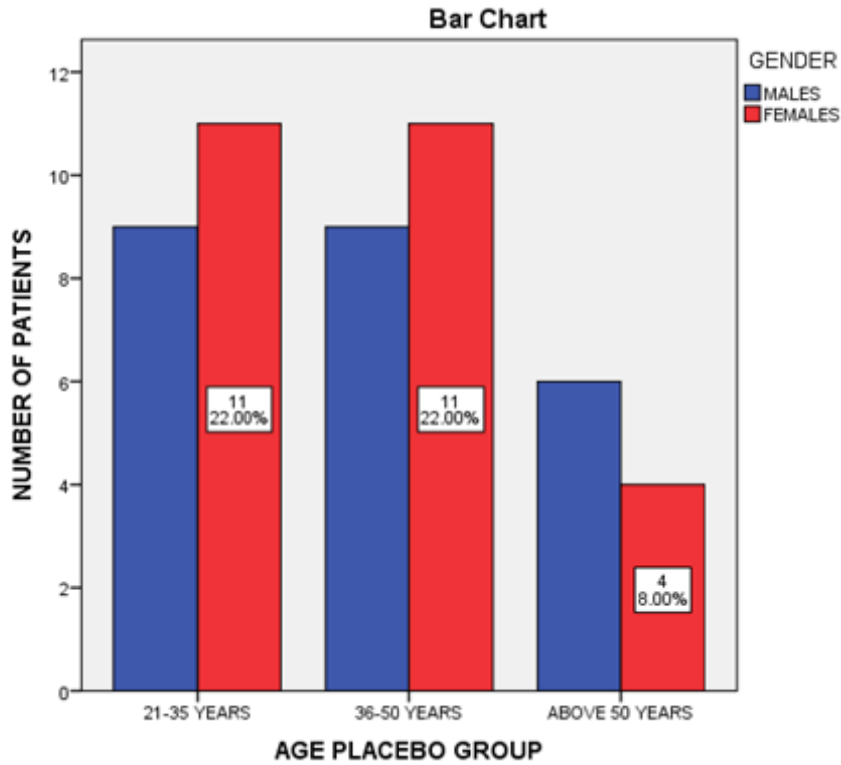


Figure 11:Placebo Age gender association.Placebo Age distribution.This graph shows distribution of age under placebo group .X axis represents age group and Y axis represents number of patients.From the graph,it is observed that prevalence of patients in age group of 21-50 years was more when compared to other groups.

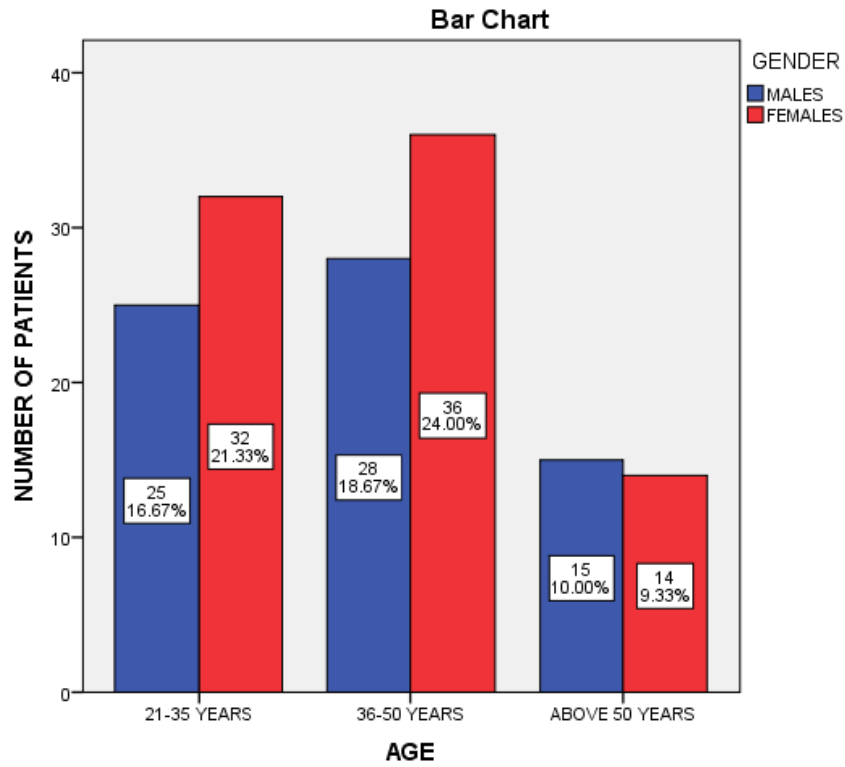


Figure 12: Age Gender association.

Table 1: Descriptives

VAS

	N	Mean	Std. Deviation	Std. Error	95% Confidence Interval for Mean		Minimum	Maximum
					Lower Bound	Upper Bound		
Triamcinolone	50	4.08	1.209	.171	3.74	4.42	2	7
Dexamethasone	50	4.86	1.129	.160	4.58	5.22	2	7
Placebo	50	4.90	1.161	.164	4.53	5.19	2	7
Total	150	4.61	1.219	.100	4.42	4.81	2	7

UNDER REVIEW

Table 2: ANOVA

VAS

	Sum of Squares	df	Mean Square	F	Sig.
Between Groups	21.373	2	10.687	7.847	.001
Within Groups	200.200	147	1.362		
Total	221.573	149			

UNDER PEER REVIEW

Table 3: Multiple Comparisons

Dependent Variable: VAS

Bonferroni

(I) Group	(J) Group	Mean Difference (I-J)	Std. Error	Sig.	95% Confidence Interval	
					Lower Bound	Upper Bound
Triamcinolone	Dexamethasone	-.820 [*]	.233	.002	-1.39	-.25
	Placebo	-.780 [*]	.233	.003	-1.35	-.21
Dexamethasone	Triamcinolone	.820 [*]	.233	.002	.25	1.39
	Placebo	.040	.233	1.000	-.53	.61
Placebo	Triamcinolone	.780 [*]	.233	.003	.21	1.35
	Dexamethasone	-.040	.233	1.000	-.61	.53

*. The mean difference is significant at the 0.05 level.



The removal of impacted third molars is one of the most frequently performed procedures in oral and maxillofacial surgery (Poeschl, Eckel and Poeschl, 2004). Extraction of impacted third molar involves trauma to the soft tissues and bony structures of the oral cavity resulting in pain and swelling (Koerner, 1994). A number of studies have been conducted to evaluate the efficacy of corticosteroids in reducing the postsurgical sequelae experienced after oral surgical procedures, particularly after the removal of impacted third molar teeth and impacted canine.

These products rapidly found their way into the world of sports, in particular because of their anti-inflammatory properties (Khan, 2005). Glucocorticoids are capable of suppressing the inflammatory process through numerous pathways. These anti-inflammatory effects include inhibition of early processes such as edema, fibrin deposition, capillary dilatation, movement of phagocytes into the area, and phagocytic activities. Later processes, such as capillary production, collagen deposition, and keloid formation also are inhibited by corticosteroids (Series, 2007).

Dexamethasone is especially widely used in third molar surgical procedures for its anti-inflammatory action, and various doses of dexamethasone have been used in most of the previous studies (Graziani *et al.*, 2006).

Pain after surgery or trauma has always been associated with inflammatory mediators such as prostaglandins and bradykinins produced at the site of injury. We postulated that localized production of prostaglandins and bradykinins might not be the sole cause of postoperative pain. If the former was true, then administration of corticosteroids, in our case dexamethasone and triamcinolone acetonide, would have significantly reduced postoperative pain because of its inhibitory effect on prostaglandin production. Some authors have attributed the pain to tension that results from swelling (Klongnoi *et al.*, 2012).

Tissue injury upregulates the production of prostaglandins or inflammatory cytokines, as well as stimulates the release of neurotransmitters such as substance P, glutamate, and calcitonin gene related peptide from the terminals of nociceptors within the spinal cord. These

neurotransmitters are not inhibited by corticosteroids. Therefore, pain still persists at a lower amplitude despite inhibition of prostanoid production(Chen, Yang and Grosser, 2013).

The mechanism of action of steroids includes inhibition of enzyme phospholipase A2 , which decreases the release of arachidonic acid from the cells at the inflammation site. As a result, the synthesis of prostaglandins and leukotrienes is reduced, with a consequent decrease of neutrophil accumulation, which at least partially accounts for the greater power of steroids by comparison to nonsteroidal antiinflammatory drugs(Laureano Filho *et al.*, 2008).

Other approaches for control of oral surgery pain include maximization of drug levels at their site of action and minimization of systemic adverse effects, along with the use of combinations of various drugs or routes of administration for one and the same drug(Bamgbose *et al.*, 2006).

The biologic half life of dexamethasone is 36 to 54 hours, and it is considered to be a long-acting steroid. The most commonly used agents are oral dexamethasone (Decadron), and intravenous or intramuscular dexamethasone sodium phosphate (Decadron phosphate)(Kim *et al.*, 2009). Triamcinolone is a better corticosteroid for intralesional injection due to its better local potency, longer duration of action, and lower systemic absorption(Hamner, Looney and Chused, 1974). Triamcinolone is a synthetic and long acting corticosteroid widely used to treat severe inflammatory diseases. Triamcinolone is widely used to treat uveitis, cystoid macular edema, proliferative vitreoretinopathy, and choroidal neovascular membrane secondary to age related macular degeneration(Kim *et al.*, 2006).

Triamcinolone is also applied clinically as a therapeutic agent to treat multiple sclerosis, which is characterized by multi topic inflammation and demyelination. Meanwhile, it has been widely accepted that topical (intralesional injection) glucocorticoids (such as Triamcinolone) are the mainstay treatment for erosive oral lichen planus. Systemic and topical glucocorticoids are contraindicated in patients with ocular primary glaucoma, tuberculosis, herpes simplex, or acute psychosis. Other conditional contraindications include diverticulitis, Cushing's syndrome, active or latent peptic ulcer, hypertension, renal insufficiency, diabetes mellitus, osteoporosis, and acute or extended infections(Williamson, Lorson and Osbon, 1980).

In 2017, Shamiri et al. performed a study with 24 patients in which they compared the efficacy of dexamethasone administered per the oral route before or immediately after surgery; the results showed that swelling and pain were lower at the analyzed time points when the drug was administered before surgery. In the present study, the greatest reduction of swelling was obtained when dexamethasone was used in both the pre and postoperative periods, with a consequent reduction of the pain level 16 hours after surgery(Al-Shamiri, Shawky and Hassanein, 2017).

The true contribution of steroids to pain control is not fully understood; it might be due to reduction of swelling, in which case steroids alone do not seem to have a clinically evident effect(Barbalho, Vasconcellos and de Morais, 2017). Dionne et al. found high levels of prostaglandins expressed by COX-2, 2 to 3 hours after surgery when placebo was administered instead of dexamethasone(Dionne *et al.*, 2003). Similarly, some studies that employed microdialysis for third molar surgery detected higher COX-2 mRNA levels in tissues taken from the site of dental extraction 2 to 3 hours after surgery. The same authors also found that dexamethasone was inefficacious to reduce the prostaglandin levels at the injury site, especially when compared with nonsteroidal antiinflammatory drugs(Abdul Wahab *et al.*, 2017; Eapen, Baig and Avinash, 2017; Patil *et al.*, 2017; Jain and Nazar, 2018; J *et al.*, 2018; Marimuthu *et al.*, 2018; Wahab *et al.*, 2018; Abhinav *et al.*, 2019; Ramadorai, Ravi and Narayanan, 2019; Senthil Kumar *et al.*, 2019; Sweta, Abhinav and Ramesh, 2019).

CONCLUSION: The submucosal application of corticosteroid drugs might be a relatively painless, comfortable, less invasive method for the patient and surgeon. It is also an effective, easy, and cheap method and its systemic effect is limited. Furthermore, the present study showed that administration of submucosal dexamethasone and triamcinolone produced similar effects in reducing edema, pain, and trismus after third molar surgery. It was concluded that the submucosal injection of dexamethasone or triamcinolone might be an effective treatment following impacted third molar surgery.and that triamcinolone could be used as an alternative to dexamethasone.

LIMITATIONS OF THE STUDY AND FUTURE SCOPE :

This study is of shorter duration with limited population. So to ascertain the findings of our study we have to do further studies in the future with large sample size and longer duration. This can be helpful to find the role of submucosal injection of dexamethasone and triamcinolone acetonide for control of postoperative pain and swelling after impacted mandibular third molar surgery.

Ethical Approval

Ethical committee approval for this study was obtained from the Institutional Ethics Committee the following ethical approval number. SDC/SIHEC/2020/DIASDATA/0619-0320.

Consent

As per international standard or university standard, patient's written consent has been collected and preserved by the author(s).

REFERENCES:

Abdul Wahab, P. U. *et al.* (2017) 'Risk Factors for Post-operative Infection Following Single Piece Osteotomy', *Journal of maxillofacial and oral surgery*, 16(3), pp. 328–332.

Abhinav, R. P. *et al.* (2019) 'The Patterns and Etiology of Maxillofacial Trauma in South India', *Annals of maxillofacial surgery*, 9(1), pp. 114–117.

Al-Shamiri, H. M., Shawky, M. and Hassanein, N. (2017) 'Comparative Assessment of Preoperative versus Postoperative Dexamethasone on Postoperative Complications following Lower Third Molar Surgical Extraction', *International journal of dentistry*, 2017, p. 1350375.

Bamgbose, B. O. *et al.* (2006) 'Prospective, randomized, open-label, pilot clinical trial comparing the effects of dexamethasone coadministered with diclofenac potassium or acetaminophen and diclofenac potassium monotherapy after third-molar extraction in adults', *Current therapeutic research, clinical and experimental*, 67(4), pp. 229–240.

Barbalho, J. C., Vasconcellos, R. J. H. and de Moraes, H. H. (2017) 'Effects of co-administered dexamethasone and nimesulide on pain, swelling, and trismus following third molar surgery: a

randomized, triple-blind, controlled clinical ...', *maxillofacial surgery*. Elsevier. Available at: <https://www.sciencedirect.com/science/article/pii/S0901502716302843>.

Boonsiriseth, K. *et al.* (2012) 'Comparative study of the effect of dexamethasone injection and consumption in lower third molar surgery', *International Journal of Oral and Maxillofacial Surgery*, pp. 244–247. doi: 10.1016/j.ijom.2011.12.011.

Boonsiriseth, K. *et al.* (2017) 'Dexamethasone injection into the pterygomandibular space in lower third molar surgery', *International journal of oral and maxillofacial surgery*, 46(7), pp. 899–904.

Chen, L., Yang, G. and Grosser, T. (2013) 'Prostanoids and inflammatory pain', *Prostaglandins & other lipid mediators*, 104-105, pp. 58–66.

Dionne, R. A. *et al.* (2003) 'Dexamethasone suppresses peripheral prostanoid levels without analgesia in a clinical model of acute inflammation', *Journal of oral and maxillofacial surgery: official journal of the American Association of Oral and Maxillofacial Surgeons*, 61(9), pp. 997–1003.

Eapen, B. V., Baig, M. F. and Avinash, S. (2017) 'An Assessment of the Incidence of Prolonged Postoperative Bleeding After Dental Extraction Among Patients on Uninterrupted Low Dose Aspirin Therapy and to Evaluate the Need to Stop Such Medication Prior to Dental Extractions', *Journal of maxillofacial and oral surgery*, 16(1), pp. 48–52.

Graziani, F. *et al.* (2006) 'Perioperative dexamethasone reduces post-surgical sequelae of wisdom tooth removal. A split-mouth randomized double-masked clinical trial', *International Journal of Oral and Maxillofacial Surgery*, pp. 241–246. doi: 10.1016/j.ijom.2005.07.010.

Hamner, J. E., 3rd, Looney, P. D. and Chused, T. M. (1974) 'Submucous fibrosis', *Oral surgery, oral medicine, and oral pathology*, 37(3), pp. 412–421.

Jain, M. and Nazar, N. (2018) 'Comparative Evaluation of the Efficacy of Intraligamentary and Supraperiosteal Injections in the Extraction of Maxillary Teeth: A Randomized Controlled Clinical Trial', *The journal of contemporary dental practice*, 19(9), pp. 1117–1121.

J, P. C. *et al.* (2018) 'Prevalence and measurement of anterior loop of the mandibular canal using CBCT: A cross sectional study', *Clinical implant dentistry and related research*, 20(4), pp. 531–534.

Kahn, C. M. (2005) 'The Merck veterinary manual', <http://www.merckvetmanual.com/mvm/index.jsp?cfile=htm/bc/50707.htm>. NJ. Available at: <https://ci.nii.ac.jp/naid/20000950202/>.

Kenny, F. A. (1954) 'Editorial & clinical observation', *Journal of oral surgery*, 12, p. 314.

Kim, H. *et al.* (2006) 'Safety and pharmacokinetics of a preservative-free triamcinolone acetate formulation for intravitreal administration', *Retina*, 26(5), pp. 523–530.

Kim, K. *et al.* (2009) 'The use of corticosteroids and nonsteroidal antiinflammatory medication for the management of pain and inflammation after third molar surgery: A review of the literature', *Oral Surgery, Oral Medicine, Oral Pathology, Oral Radiology, and Endodontology*, 107(5), pp. 630–640.

Klongnoi, B. *et al.* (2012) 'Effect of single dose preoperative intramuscular dexamethasone injection on lower impacted third molar surgery', *International journal of oral and maxillofacial surgery*, 41(3), pp. 376–379.

Koerner, K. R. (1994) 'The removal of impacted third molars. Principles and procedures', *Dental clinics of North America*, 38(2), pp. 255–278.

Laureano Filho, J. R. *et al.* (2008) 'Clinical comparative study of the effectiveness of two dosages of dexamethasone to control postoperative swelling, trismus and pain after the surgical extraction of mandibular impacted third molars', *Cephalalgia: an international journal of headache*, 28(12), p. 220.

Lima, C. A. A. *et al.* (2017) 'Oral dexamethasone decreases postoperative pain, swelling, and trismus more than diclofenac following third molar removal: a randomized controlled clinical trial', *Oral and maxillofacial surgery*, 21(3), pp. 321–326.

Marimuthu, M. *et al.* (2018) 'Canonical Wnt pathway gene expression and their clinical

correlation in oral squamous cell carcinoma', *Indian journal of dental research: official publication of Indian Society for Dental Research*, 29(3), pp. 291–297.

McGrath, C. *et al.* (2003) 'Changes in life quality following third molar surgery – the immediate postoperative period', *British Dental Journal*, pp. 265–268. doi: 10.1038/sj.bdj.4809930.

Neupert, E. A., 3rd *et al.* (1992) 'Evaluation of dexamethasone for reduction of postsurgical sequelae of third molar removal', *Journal of oral and maxillofacial surgery: official journal of the American Association of Oral and Maxillofacial Surgeons*, 50(11), pp. 1177–82; discussion 1182–3.

Ngeow, W. C. and Lim, D. (2016) 'Do Corticosteroids Still Have a Role in the Management of Third Molar Surgery?', *Advances in therapy*, 33(7), pp. 1105–1139.

Patil, S. B. *et al.* (2017) 'Comparison of Extended Nasolabial Flap Versus Buccal Fat Pad Graft in the Surgical Management of Oral Submucous Fibrosis: A Prospective Pilot Study', *Journal of maxillofacial and oral surgery*, 16(3), pp. 312–321.

Poeschl, P. W., Eckel, D. and Poeschl, E. (2004) 'Postoperative prophylactic antibiotic treatment in third molar surgery—a necessity?', *Journal of oral and maxillofacial surgery: official journal of the American Association of Oral and Maxillofacial Surgeons*, 62(1), pp. 3–8.

Ramadorai, A., Ravi, P. and Narayanan, V. (2019) 'Rhinocerebral Mucormycosis: A Prospective Analysis of an Effective Treatment Protocol', *Annals of maxillofacial surgery*, 9(1), pp. 192–196.

Senthil Kumar, M. S. *et al.* (2019) 'Inflammatory pseudotumour of the maxillary sinus: clinicopathological report', *Oral Surgery*, 12(3), pp. 255–259.

Series, M. H. (2007) 'Thomson Micromedex', *Greenwood Village, CO. Accessed Oct.*

Spies, T. D. *et al.* (1952) 'A clinical appraisal of ACTH and cortisone as therapeutic agents in dental medicine', *Oral surgery, oral medicine, and oral pathology*, 5(1), pp. 25–40.

Sweta, V. R., Abhinav, R. P. and Ramesh, A. (2019) 'Role of Virtual Reality in Pain Perception

of Patients Following the Administration of Local Anesthesia', *Annals of maxillofacial surgery*, 9(1), pp. 110–113.

Wahab, P. U. A. *et al.* (2018) 'Scalpel Versus Diathermy in Wound Healing After Mucosal Incisions: A Split-Mouth Study', *Journal of oral and maxillofacial surgery: official journal of the American Association of Oral and Maxillofacial Surgeons*, 76(6), pp. 1160–1164.

Williamson, L. W., Lorson, E. L. and Osbon, D. B. (1980) 'Hypothalamic-pituitary-adrenal suppression after short-term dexamethasone therapy for oral surgical procedures', *Journal of oral surgery*, 38(1), pp. 20–28.

UNDER PEER REVIEW