

A case report on Neonatal giant hepatic hemangioma

ABSTRACT

Introduction: Hepatic hemangioma is the third most common pediatric tumor, and it is rare in the neonatal period. Because of its rarity, a treatment strategy for this disease is still being established.

Patient and Methods: A neonate girl was referred to our unit for hepatomegaly. She had a very high Alpha-fetoproteins, and the abdominal scan showed a large mass with no vascular invasion nor deep lymphadenopathy. She was diagnosed with hepatic hemangioma and treated successfully with propranolol and cortisone. After 17 months of treatment, the patient's hepatomegaly was reduced by 97.3%.

Results: Report on successful treatment, with no side effects, for hepatic hemangioma with propranolol and cortisone associated with calcium, potassium, and vitamin D.

Conclusion: The patient's large focal hepatic hemangioma was treated successfully with propranolol. The treatment included cortisone for one month, associated with calcium, potassium, and vitamin D.

Keywords: infantile hepatic hemangioma, propranolol, corticosteroids.

INTRODUCTION

Infantile hepatic hemangioma (IHE) is a vascular liver tumor of infancy (accounting for 1%–5% of all tumors), and it is also the third most common hepatic tumor of children [1]. IHE is characterized by proliferative endothelial cell lesions; however, most IHEs go clinically undetected and eventually resolve on their own without incident [2,3].

IHE is usually diagnosed using radiological examinations (ultrasound, computed tomography, and magnetic resonance imaging); biopsies should be carefully considered since they might result in massive bleeding [2,4]. The general natural history shows that small and asymptomatic lesions in children may self-heal without treatment, while larger or symptomatic lesions require active treatment to prevent serious complications, such as congestive heart failure, hypothyroidism, abdominal compartment syndrome, or fulminant hepatic failure that will lead to death [2]. Therapeutic options for IHE include drug treatment (propranolol, corticosteroids, and drugs with strong antiangiogenic effects, such as interferon alpha, cyclophosphamide, vincristine, or actinomycin D), radiotherapy, selective embolization, and surgery (vascular ligation, tumor resection, or liver transplantation) [3]. In the present case, a 3-day-old girl presented a large hemangioma on segments V-VIII of the liver. The girl's hemangioma shrank to 28% of its initial size after seven months, and then to less than 3% of its initial size after seventeen months of treatment.

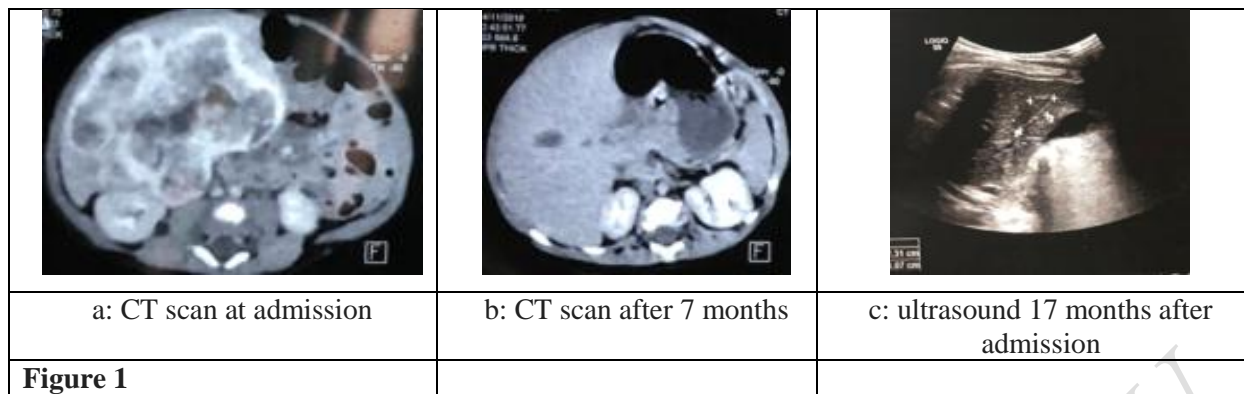
CASE REPORT

A 3-day-old girl was referred to our hospital for a hepatomegaly detected incidentally two days after birth. The obstetric history of the patient's mother was uncomplicated, and no abnormalities were noticed during prenatal examinations. In particular, no abdominal tumor was noticed during ultrasound exams during pregnancy. When the girl was admitted to our unit, she was breathing smoothly, had a good appetite, and slept well. After physical examination, her stable heart rate was between 120 and 130 bpm at admission; respiratory rate was 25 bpm; her systolic blood pressure ranged between 84 and 90; and the diastolic was between 45 and 59 mm Hg. No significant yellow pigmentation or vascular papules were found in the skin and sclera, and the liver was palpated approximately 8 cm below the left costal margin, without tenderness.

An abdominal scan showed a large polylobed mass in segments V, VI, VII, and VIII of the right lobe of the liver. The mass hypodense, heterogeneous, contained cystic areas and some linear calcifications, intensely enhanced in a peripheral lump after injection of a contrast product, with centripetal infill measured at 72mm x 68mm x 54mm (Figure 1.a). This mass pushes back the hepatic capsule in some places, and produces a mass effect on the neighboring vascular structures which remain permeable (the HSV, the TP and its bifurcation branches which are removed by the mass).

Although the examination showed her alpha-fetoproteins (AFP) to be too high (2637.0 ng/ml), we did not diagnose her with malignant disease since she was in the neonatal period and there was no vascular invasion, nor deep lymphadenopathy. Her alanine aminotransferase (ALT) was 13.0 U/L and the aspartate aminotransferase (AST) was 35.6 U/L. Cardiac Doppler ultrasound showed no obvious abnormalities and normal coagulation function. Her general vital signs were stable at admission.

The girl was diagnosed with hepatic hemangioma after multidisciplinary diagnosis. As the child's symptoms and imaging performances were rather typical of IHE, no further examination, such as biopsy under ultrasound, or laparoscopic exploration were considered. She was treated with propranolol (2 mg per kg body weight per day), cortisone associated with calcium, potassium, and vitamin D. After one week of treatment, she developed no signs of bradycardia, asthma, hypotension, or other adverse effects. Four weeks after starting propranolol, her AFP decreased significantly (to 87 ng/ml), which confirmed the hepatic hemangioma even though the mass had not regressed (patients respond to propranolol from 4.3 weeks to 8.7 weeks [5]). However, subsequent regular checks showed that the mass was regressing. After seven months, the mass measured 27mm x 41mm x 51mm, which is 28% the initial size of the mass (Figure 1.b). After another ten months, an ultrasound revealed a mass with reduced size at 22mm x 24mm x 11mm, which is 2.72% the initial size of the mass (Figure 1.c).



DISCUSSION

IHE is the most common benign liver tumor of infants (12%–20% of all infants) and is classified into 3 types: focal, multiple, and diffuse [3]. The average age of IHEs starts at 47 days (range 1–365 days) and they are mainly diagnosed in the first quarter after birth [6]. Many hepatic hemangiomas are asymptomatic and clinically silent, while others may result in anemia, consumptive coagulopathy, vomiting, abdominal compartment syndrome, and congestive heart failure. Congestive heart failure might be caused by high volume arteriovenous or portovenous shunting, and the mortality rate of infants due to hepatic hemangiomas used to be as high as 18% [7]. Most abdominal tumors are discovered by ultrasound during pregnancy. Unfortunately, no abnormalities were noticed during prenatal examinations in the parents' home city.

Imaging is vital to diagnose these lesions. Ultrasound shows a lesion full of blood flow signals [8], while CT scanning reveals the lesion in a low-density area when the contrast agent is injected into the vena, and the area is first enhanced at the edge and then enters into the center. After a short period, the focus area's density becomes the same as the liver's.

Until recently, cutaneous IH was commonly treated using corticosteroids, and Leaute-Labreze et al [9] found that using propranolol was highly effective for cutaneous IH in 2008. Many practitioners have adopted propranolol as the first line therapy, and it has been proven effective in treating diffuse hepatic infantile hemangiomas in the last few years. Recent studies have shown that propranolol can successfully treat multifocal and diffuse intrahepatic hemangiomas in combination with other medical therapies, such as systemic corticosteroids and vincristine [10,11]. The effect of propranolol on IH seems to be related to the diameter of the hemangioma [10]. Most studies evaluating propranolol for IHE have involved small patient numbers with dosages of 2 to 3.5 mg/kg/day divided two times a day.

Propranolol has rare side effects in both cutaneous and hepatic IH, and most such effects occur within 1 to 3 hours after oral administration and are transient [12]. Common adverse events include hypotension, bradycardia, sleep disturbance, and acrocyanosis. Serious adverse events are rare, and include reports of symptomatic hypotension, bradycardia, bronchospasm, hypoglycemia, and even hypoglycemic seizures. Prolonged fasting is to be avoided during episodes of acute respiratory disease and bronchial spasm [13].

Congenital focal hepatic hemangiomas show a less predictable response to propranolol therapy [14]. This may be associated with arteriovenous shunts. In our case, we used propranolol for seven weeks and reviewed the size of the lesion by a CT scan, but no obvious changes were detected. This may have been due to the short period of using propranolol. The patient was kept on propranolol treatment for ten months, with cortisone doses of 2 mg/Kg/day during the first two months, and then gradually decreasing doses until no cortisone was included starting the third month.

It is generally believed that IHE, which is defined as having a diameter larger 5 cm, is an indication for embolization [15]. Unfortunately, this technique requires significant technical skills and knowledge specific to these lesions.

CONCLUSION

Propranolol proved to be effective in the treatment of hemangiomas. To cure the disease, treatment is necessary for several months.

REFERENCES

1	Bouzidi, Hassan, et al. "Inherited tubular renal acidosis." <i>Annales de biologie clinique</i> . Vol. 69. No. 4. 2011.
2	Smith AN, Jouret F, Bord S, Borthwick KJ, Al-Lamki RS, Wagner CA, Ireland DC, Cormier-Daire V, Frattini A, Villa A, Kornak U, Devuyt O, Karet FE (2005) Vacuolar H ⁺ -ATPase d2 subunit: molecular characterization, developmental regulation, and localization to specialized proton pumps in kidney and bone. <i>J Am Soc Nephrol</i> 16:1245–1256
3	Mohebbi, Nilufar, and Carsten A. Wagner. "Pathophysiology, diagnosis and treatment of inherited distal renal tubular acidosis." <i>Journal of nephrology</i> 31.4 (2018): 511-522.
4	Nijenhuis T, Renkema KY, Hoenderop JG, Bindels RJ (2006) Acid- base status determines the renal expression of Ca ²⁺ and Mg ²⁺ transport proteins. <i>J Am Soc Nephrol</i> 17:617–626
5	Escobar, Laura I., et al. "Mutations in ATP6V1B1 and ATP6V0A4 genes cause recessive distal renal tubular acidosis in Mexican families." <i>Molecular genetics & genomic medicine</i> 4.3 (2016): 303-311.
6	Alexander, R. Todd, et al. "Hereditary Distal Renal Tubular Acidosis Synonyms: Classic Renal Tubular Acidosis, Type 1 RTA." <i>Gene</i> 1: 2.
7	Elhayek, Donia, et al. "Molecular diagnosis of distal renal tubular acidosis in Tunisian patients: proposed algorithm for Northern Africa populations for the ATP6V1B1, ATP6V0A4 and SCL4A1 genes." <i>BMC medical genetics</i> 14.1 (2013): 119.
8	Rossert J, Barousse-Nicolet L. Régulation rénale de l'équilibre acide- base. <i>Ann Biol Clin</i> 2000 ; 58 : 705-10.
9	Green J, Maor G. Effect of metabolic acidosis on the growth hormone/IGF-1 endocrine axis in skeletal growth centers. <i>Kidney Int</i> 2000 ; 57 : 2258-67.
10	Dechaux M, Caldas A. Acidoses tubulaires. In : Loirat C, Niaudet P. eds., <i>Nephrol. Progrès en néphrologie pédiatrique</i> 1993 : 57-64.
11	Jequier S, Stoermann Chopard C, Terrier F. Nephrocalcinose et autres calcifications du parenchyme rénal. <i>Encycl Med. Chir. Radiodiagnostic. Urologie. Gynécologie</i> 2002 ; 34-180-A-10 : 24P.
12	Rodriguez-Soriano J. New insights into the pathogenesis of renal tubular acidosis from functional to molecular studies. <i>Pediatr Nephrol</i> 2000 ; 14 : 1121-36.

13	Karet FE. Inherited distal renal tubular acidosis. J Am Soc Nephrol 2002 ; 13 : 2178-84.
14	ZHU, Zhenwei, CAI, Peng, ZHU, Jie, et al. Neonatal giant hepatic hemangioma: A case report. Medicine, 2018, vol. 97, no 42.
15	Hubert P, Ben Jaballah N, Labenne M. Troubles de l'eau et des elec- troytes. Encycl Med Chir Pediatri 1995 ; 4-054-A-10 : 12P.

UNDER PEER REVIEW