

Effect of *Naja nigricollis* (Elapidae) venom on some vital organs of *Oryctolagus cuniculus*

ABSTRACT

The general objective of this study was to evaluate the effect of *Naja nigricollis* venom on some vital organs of rabbits. To carry out this study, nine (9) rabbits including five (5) males and four (4) females were divided into two (2) control lots and one (1) experimental lot. Each control lot was composed of three (3) rabbits (males or females) while the experimental lot was comprised of two (2) males and one (1) female. The rabbits of the experimental lot were injected with *Naja nigricollis* venom for about 20 to 30 minutes and then after the determination of their biochemical and hematological parameters, were autopsied for the removal of organs such as heart, liver, kidneys and lungs. These organs were weighed and their appearance was studied. The results of this study showed that the heart and lungs of control male rabbits weighed more than those of females, whereas the liver and kidneys did not. Then, the cytotoxins of the *Naja nigricollis* venom were at the origin of gangrene which induced necrosis by an increase in their volume in a general way and degradation of the organs studied. Finally, the dose of venom injected (2 mg/Kg of body weight) could also cause hypotension, so favoring the formation of oedemas and consequently gangrene.

Keywords: Venom, Naja nigricollis, organs, hypotension, necrosis

1. INTRODUCTION

Envenomation is the introduction into the body of a toxic substance, the venom, due to the bite of a snake, the sting of a scorpion, a wasp, etc. The most dangerous is that caused by snake bites [1,14]. In fact, the venom contains a complex mixture of enzymes, peptides and proteins of low relative molecular weight, with specific chemical and biological activities, which can lead to death through neurological and/or hematological disorders [12,14]. This case of envenomation is a problem affecting the five continents of the world. Worldwide, the annual incidence of snakebites exceeds six million [3,10,7]. In Africa, the severity of envenomations is noticed in rural and urban areas with an incidence about ten to twenty times lower than in rural areas. Also in Africa, more than one million snakebites occur each year causing 600,000 cases of envenomation. However, the number of patients treated can be estimated at 250,000 with nearly 20,000 deaths because the majority prefer to turn to traditional medicine first [5,6].

In Africa, in general, the venomous snakes responsible for all these disasters are mostly Viperidae and Elapidae. The Viperidae (vipers) are the most widespread of the venomous species and do the most damage while the Elapidae (naja or cobra, mamba) are the most dangerous of the snakes because of the high degree of toxicity of their venom [15]. It is traditional to oppose cobraic envenomations, essentially neurotoxic, and viperine envenomations, dominated by necrosis and hemorrhagic syndromes. In practice, this distinction must be qualified [6]. Indeed, the diversity of substances contained in the venoms of the species of these two families of snakes, vary according to the species and even between individuals of the same species, which makes certain species exceptional in the action of their venom. Among these exceptions is the venom of *Naja nigricollis* (spitting cobra), one of the most dangerous and representative species of Elapidae in Africa. Its venom contains cytotoxins that target certain blood cells and those of certain organs such as the heart. Its action on these organs, creates dysfunctions whose effects associated with those of these neurotoxins could have a serious impact on the respiration of the victim and lead to death [13,4].

It is with the aim of understanding the action that the venom of *Naja nigricollis* can have on certain vital organs that this study was conducted.

2. MATERIALS AND METHODS

2.1 Animal material

For this study, nine rabbits, five males and four females of the Hyplus breed, aged two and a half months were purchased from a breeder in the locality of Daloa (Côte d'Ivoire, West Africa). After the acclimatization period, the weight of the rabbits varied between 1.45 and 2.4 kg. Besides this animal model, the venom of *Naja nigricollis* (spitting cobra) was also used and provided by the Pasteur Institute of Adiopodoumé (Côte d'Ivoire, West Africa).

2-2 Method of carrying out experimental tests

For the experimental tests, 2 mg of venom crystals were dissolved in 0.5 mL of physiological solution to obtain a concentration of 4 mg/mL. This is the concentration that was injected into the rabbits of the experimental batch for about twenty to thirty minutes. According to [11], the median lethal dose for a 2 kg rabbit is 2 mg/kg body weight in intra-muscular injection.

2.3 Methods of organ procurement

To collect these organs, control and experimental rabbits were autopsied and then the organs such as heart, liver, lungs and kidneys were isolated and weighed in the laboratory. Then, the appearance of these various organs was studied.

3. RESULTS

3.1 General appearance of isolated rabbit organs

Figures 1, 2, 3 and 4 are those of isolated organs (heart, liver, kidney and lungs, respectively) of control and envenomated rabbits. Isolated organs from control rabbits (Figures 1A, 2A, 3A, and 4A) are reddish for the heart (Figure 1A) and kidneys (Figure 3A), brown for the liver (Figure 2A), and purplish red for the lungs (Figure 4A). They are also firm and elastic in consistency. However, the organs of envenomated rabbits (Figures 1B, 2B, 3B, and 4B) are dark red for the heart (Figure 1B) and kidneys (Figures 3B), purplish red for the liver (Figure 2B), and orange-red for the lungs (Figure 4B). These organs have a flaccid texture and present a degraded state or a generally bulky appearance.

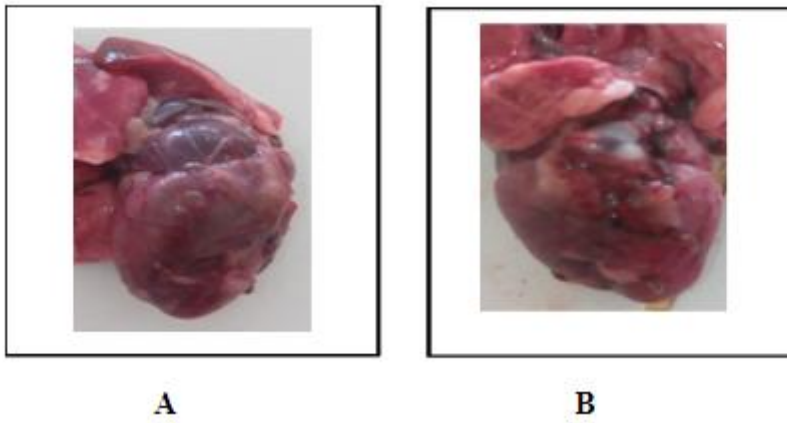


Fig. 1: Isolated rabbit hearts

A: Isolated heart of control rabbit, B: Isolated heart of envenomed rabbit

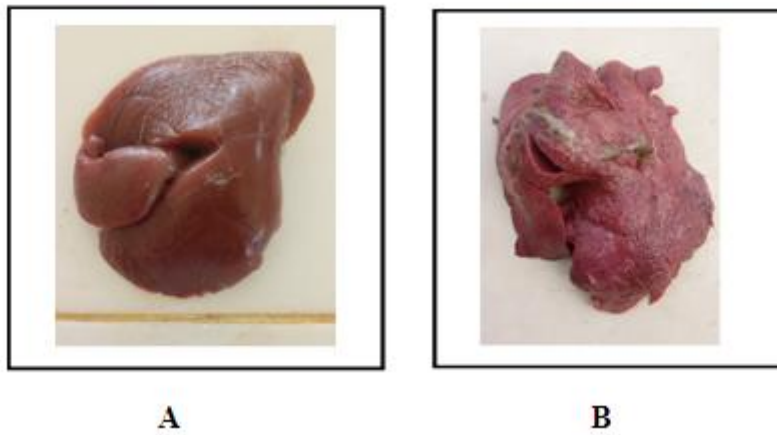


Fig. 2: Isolated livers of rabbits

A: Isolated livers from control rabbits, B: Isolated livers from envenomated rabbits

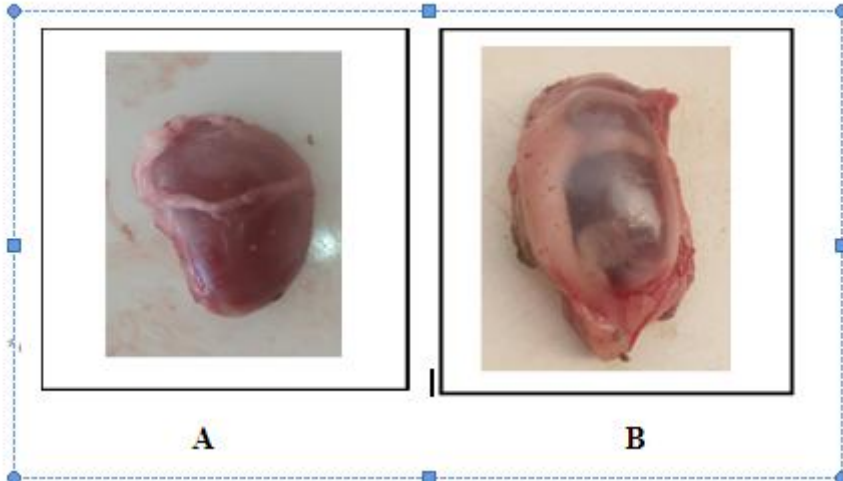


Fig. 3: Isolated kidneys from rabbits

A: Isolated kidney from control rabbit, B: Isolated kidney from envenomed rabbit

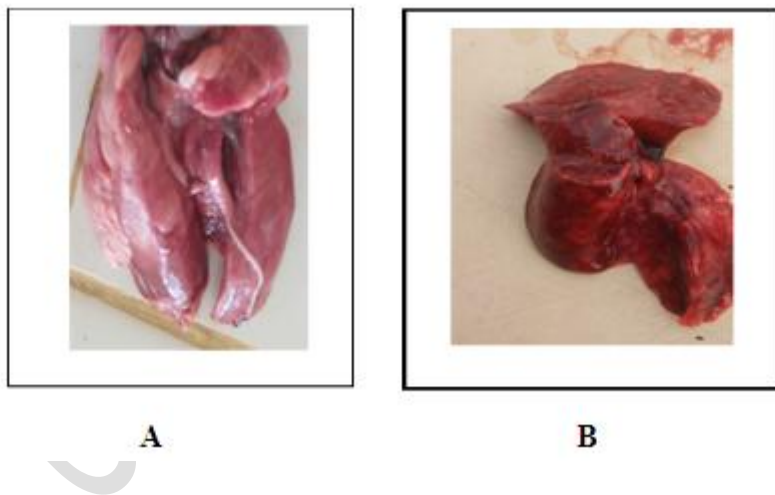


Fig. 4: Isolated lungs of rabbits

A: Isolated lung from control rabbit, B: Isolated lung from envenomed rabbit

3.2 Weight of organs isolated from control and envenomed rabbits

Table 1 shows the results of weighing the isolated organs of control (lot 11 and 12) and envenomed (lot 1) rabbits. It allowed to have for the control rabbits (males or females) and each isolated organ, the following reference values:

- for the heart, they range from 4.51 to 8.70 g for males and from 4.48 to 6.63 g for females.
- for the liver, they range from 49.68 to 64.30 g in males and from 51.56 to 64.66 g in females.
- for males and females, they are 4.94 to 6 g and 5.01 to 5.95 g respectively for the kidneys.
- for males and females, they range from 6.50 to 8.03 g and from 5.66 to 7.07 g for the lungs, respectively.

As for the weight of the organs of the envenomed rabbits, it indicates that:

- the heart and lungs of the M18 male (10.5 g and 8.5 g respectively) and those of the F4 female (7.02 g and 8.45 g) are above their respective norms (4.51-8.70 g and 6.50-8.03 g, and 4.48-6.63 g and 5.66-7.07 g); while those of the M19 male (7.5 g and 8 g) are normal
- the liver and kidneys of both males (70.9 g and 81.3 g for liver, and 6.9 g and 8.1 g for kidneys) and of the female (69.4 g for liver and 6.8 g for kidneys) are above their respective reference values (49.68-64.30 g and 51.56-64.66 g for liver, and 4.94-6 g and 5.01-5.95 ng for kidneys).

Table 1: Organ weights isolated from control and envenomed rabbits

	Lot 11: Males controls					Lot 12: Females controls					Lot 1: Envenomed				
	M10	M16	M17	M	Sd	Reference values	F1	F10	F12	M	Sd	Reference values	M18	M19	F4
Weight (Kg)	2.4	1.45	1.9	1.9167	0.4752	1.44-2.39	2	1.7	2	1.9	0.1732	1.73-2.07	1.85	1.9	1.9
Heart (g)	8.7	4.51	6.6	6.6033	2.095	4.51-8.70	6.66	4.51	5.5	5.5567	1.0761	4.48-6.63	10.5	7.5	7.02
Liver (g)	65	50.7	55.3	56.99	7.313	49.68-64.30	60.7	50.7	63	58.113	6.5505	51.56-64.66	70.9	81.3	69.4
Kidneys (g)	6	4.94	5.47	5.47	0.53	4.94-6	5.7	4.94	5.8	5.48	0.4703	5.01-5.95	6.9	8.1	6.8
Lungs (g)	8.1	7.1	6.6	7.2667	0.7638	6.50-8.03	6.3	7.1	5.7	6.3667	0.7024	5.66-7.07	8.5	8	8.45

F= Female ; M= Male ; M = Mean ; Sd = Standard deviation ; Dark grey and bold: High value

Example: M10= Male number 10; F1= Female number 1

4. DISCUSSION

Regarding the macroscopic analysis, it can be said that the heart and lungs weigh more in males than females because their respective reference values are 4.51 to 8.70 g and 4.48 to 6.63 g, and 6.50 to 8.03 g and 5.66 to 7.07 g. On the other hand, the liver and kidneys of females which are respectively 51.56 to 64.66 g and 5.01 to 5.95 g weigh more than those of males (49.68 to 64.30 g and 4.94 to 6 g). The reference values obtained in this study are similar to those of [9] for liver; [2] for heart and [17] for kidney.

If for the envenomed rabbits (lot 1), the heart and lungs of one male out of two and the female, and for the liver and kidneys of both males and the female have their respective organ is above the norms, it would mean that the snake venom has certainly more action on these organs mentioned above. So in general, the venom would induce on these isolated organs of these envenomed rabbits, an increase in their volume. In addition, besides this noticed increase, the isolated organs are generally degraded. Therefore, the increase in volume of certain organs and the degraded or dilated appearance observed on these organs could be due to certain factors. These factors may include fluid accumulation in the interstitial zone and tissue necrosis. The necrosis may be caused by cytotoxins that would induce gangrene in these organs, while the accumulation of fluid in the interstitial zone would be the cause of edema. Indeed, according to [8], the venoms of Elapidae possess cytolytic toxins. This cytolysis can cause necrosis which can lead to gangrene. These gangrene can expose vital organs to anaerobic germs and superinfection [15]. Thus, the degraded state of the different organs obtained in this study can be explained by this state of affairs. According to [11], the dose of 2 mg/Kg body weight of *Naja nigricollis* venom injected in this study can cause a drop in blood pressure (hypotension). This decrease is due to the cytotoxins of this venom. [16] reveal that the reduction of this blood pressure would be at the origin of the formation of edemas observed on certain organs. These edemas would in turn be the cause of hypertrophy. [14] also shows that the increase in volume of the cell which becomes waterlogged seems to be linked to a disruption of ionic exchanges on both sides of the membrane, which makes it possible to suppose that cytotoxins act at the level of ionic channels, particularly sodium. They depolarize the cytoplasmic membrane of excitable cells. So, the hypertrophy observed on the organs of this study would obey these principles.

5. CONCLUSION

In the end, this study revealed that in general:

- the heart and lungs of male rabbits weigh more than those of females in contrast to the liver and kidneys.
- the venom of *Naja nigricollis* induces in a general way an increase in volume and degradation of vital organs leading to necrosis. The necrosis is due to the cytotoxins of the venom which causes gangrene of these organs. These gangrene can expose the vital organs to anaerobic germs and to a superinfection.
- The dose of venom injected (2 mg/Kg of body weight) can also cause hypotension (decrease in blood pressure) which can lead to the formation of edemas and consequently to gangrene (hypertrophy of organs).

ETHICAL APPROVAL

Animal ethic committee approval has been taken to carry out this study.

REFERENCES

1. Anonymous. Envenomations in the Medical Encyclopedia of Africa. Larousse Afrique 4, Belgium. 1986;1111-1115.
2. Aouimeur A, M'Ziane K. Biochemical and histological characteristics of the heart according to the co-administration of vitamin C in male rabbits treated with Avimec. Master in Biology Option: Biological Engineering, Faculty of Natural and Life Sciences, Blida 1 University, Algeria. 2017;80.
3. Arfaoui A, Hmimou R, Ouammi L, Soulaymani A, Mokhtari A, Chafiq F, Soulaymani-Bencheick R. Epidemiological profile of snakebites in Morocco. J Venom Anim Toxins Incl Trop Dis. 2009;15(4): 653-666.
4. Chippaux JP. Snakebites in intertropical Africa. Health booklet. 1992; 2:221-234.
5. Chippaux JP. Snake bites: appraisal of the global situation. Bulletin of World Health Organisation. 1998;76(5):515-524.
6. Chippaux JP. The snakes of West and Central Africa. Tropical Fauna and Flora Collection. 2006;35:11-329.
7. Coulibaly SK, Hami H, Hmimou R, Mokhtari A, Soulaymani R, Maiga A, Soulaymani A. Ophidian envenomations in the Koulikoro region of Mali. Antropo. 2013;29:41-47. www.didac.ehu.es/antropo
8. Diarra A. Epidemiological, clinical and therapeutic aspects of snakebites in the national hospitals of Mali. State Doctorate in Medicine, Faculty of Medicine, Pharmacy and Odontostomatology, University of Bamako, Mali. 2006;70.
9. Djamila S. Study of the effects of Switch (Fludioxonil and Cyprodinil) on the liver of rabbit "*Oryctolagus cuniculus*". Doctorate in Veterinary, Institute of Veterinary Sciences, University Saad Dahlad Blida1, Algeria. 2018;52.

10. El Koraichi A, Tsala G, El Haddoury M, Ech-chérif El Kettani S. Epidemiology of viper bite envenomations in the pediatric intensive care unit at the children's hospital of Rabat, Morocco. French Annals of Anesthesia and Resuscitation. 2011;30(1):83-85.
11. Fumba G. Anti-venomous medicinal plants from Burundi. Presses of the future, Arlon, Belgium. 1983;136.
12. Gentilini M. Venomous animals, Flammarion medicine science: 5th edition Paris. 1993;682 p.
13. Goyffon M, Chippaux JP. Terrestrial venomous animals. Encyclopedia Medico-Surgery, Paris, France. 1990;14.
14. Kassogué A. Renal complications of snake bite envenomations at the SUC HGT from January to December 2004. State Doctorate in Medicine, Faculty of Medicine, Pharmacy and Odontostomatology, University of Bamako, Mali. 2006;86.
15. Manaoui R. Snake bites in the region of Marrakech Tensift el Haouz. State Doctorate in Medicine, Faculty of Medicine and Pharmacy, Cadi Ayyad University, Marrakech, Morocco. 2007;73.
16. Roch A, Allardet S. Physiopathology of edema. Resuscitation. 2007;16:102-110.
17. Zerrout N. Effect of vitamin C co-administration on the kidney in male rabbits treated with ivermectin. Master's thesis in Biology Option: Biological Engineering, Faculty of Natural and Life Sciences, Blida 1 University, Algeria. 2016;63.